


---

**U.S. ARMY MEDICAL DEPARTMENT CENTER AND SCHOOL  
FORT SAM HOUSTON, TEXAS 78234-6100**

---



# **ANATOMY FOR X-RAY SPECIALISTS**

**SUBCOURSE MD0956**

**EDITION 200**

## **DEVELOPMENT**

This subcourse is approved for resident and correspondence course instruction. It reflects the current thought of the Academy of Health Sciences and conforms to printed Department of the Army doctrine as closely as currently possible. Development and progress render such doctrine continuously subject to change.

The subject matter expert responsible for content accuracy of this edition was the NCOIC, Nursing Science Division, DSN 471-3086 or area code (210) 221-3086, M6 Branch, Academy of Health Sciences, ATTN: MCCS-HNP, Fort Sam Houston, Texas 78234-6100.

## **ADMINISTRATION**

Students who desire credit hours for this correspondence subcourse must meet eligibility requirements and must enroll in the subcourse. Application for enrollment should be made at the Internet website: <http://www.atrrs.army.mil>. You can access the course catalog in the upper right corner. Enter School Code 555 for medical correspondence courses. Copy down the course number and title. To apply for enrollment, return to the main ATRRS screen and scroll down the right side for ATRRS Channels. Click on SELF DEVELOPMENT to open the application and then follow the on screen instructions.

For comments or questions regarding enrollment, student records, or examination shipments, contact the Nonresident Instruction Branch at DSN 471-5877, commercial (210) 221-5877, toll-free 1-800-344-2380; fax: 210-221-4012 or DSN 471-4012, e-mail [accp@amedd.army.mil](mailto:accp@amedd.army.mil), or write to:

NONRESIDENT INSTRUCTION BRANCH  
AMEDDC&S  
ATTN: MCCS-HSN  
2105 11TH STREET SUITE 4191  
FORT SAM HOUSTON TX 78234-5064

## **CLARIFICATION OF TERMINOLOGY**

When used in this publication, words such as "he," "him," "his," and "men" are intended to include both the masculine and feminine genders, unless specifically stated otherwise or when obvious in context.

## TABLE OF CONTENTS

<u>Lesson</u>		<u>Paragraphs</u>
	INTRODUCTION	
1.	INTRODUCTION TO HUMAN ANATOMY	
	Section I. Orientation	1-1--1-2
	Section II. Cells	1-3--1-6
	Section III. Bones	1-7--1-13
	Section IV. Common Fractures	1-14--1-15
	Exercises	
2.	REGIONAL OSTEOLOGY	
	Section I. Upper Extremity	2-1--2-8
	Section II. Lower Extremity	2-9--2-15
	Section III. The Vertebral Column	2-16--2-21
	Section IV. The Thorax	2-22--2-25
	Section V. The Skull	2-26-2-34
	Exercises	
3.	BODY SYSTEMS OTHER THAN SKELETAL	
	Section I. The Digestive System	3-1--3-12
	Section II. The Urogenital System	3-13--3-19
	Section III. The Respiratory System	3-20--3-28
	Section IV. The Nervous System	3-29--3-34
	Section V. The Circulatory System	3-35--3-44
	Section VI. The Endocrine System	3-45--3-54
	Section VII. The Special Senses	3-55--3-57
	Exercises	

**CORRESPONDENCE COURSE OF  
THE U.S. ARMY MEDICAL DEPARTMENT CENTER AND SCHOOL  
SUBCOURSE MD0956  
ANATOMY FOR X-RAY SPECIALISTS**

**INTRODUCTION**

As an X-ray specialist (technologist), you need to have a good understanding of human anatomy, especially as it relates to identifying anatomical landmarks, positioning a patient correctly and comfortably, for the making of radiographic exposures.

Many structures of the body are radiopaque (impenetrable by x-ray). Others can be made so. These are the structures that are of primary interest to you, and the area of primary emphasis in this subcourse. Thus, this subcourse is not a broad introductory course in anatomy. Rather, it makes several assumptions, that you, the reader, already have a general basic knowledge of human anatomy and physiology, and that you have a good working knowledge of medical terminology. If you do not meet these requirements, you are advised to study Subcourse MD0006, Basic Human Anatomy, and Subcourse MD0007, Basic Human Physiology, either before or while you study this subcourse and have a good medical dictionary readily available. The final assumption is that you need, and want, instruction in anatomy from the special viewpoint of the X-ray technologist.

Subcourse Components:

The subcourse instructional material consists of the following:

- Lesson 1, Introduction to Human Anatomy.
- Lesson 2, Regional Osteology.
- Lesson 3, Body Systems Other Than Skeletal.

Here are some suggestions that may be helpful to you in completing this subcourse:

- Read and study each lesson carefully.
- Complete the subcourse lesson by lesson. After completing each lesson, work the exercises at the end of the lesson, marking your answers in this booklet.
- After completing each set of lesson exercises, compare your answers with those on the solution sheet that follows the exercises. If you have answered an exercise incorrectly, check the reference cited after the answer on the solution sheet to determine why your response was not the correct one.



**Credit Awarded:**

To receive credit hours, you must be officially enrolled and complete an examination furnished by the Nonresident Instruction Branch at Fort Sam Houston, Texas. Upon successful completion of the examination for this subcourse, you will be awarded 11 credit hours.

You can enroll by going to the web site <http://atrrs.army.mil> and enrolling under "Self Development" (School Code 555).

A listing of correspondence courses and subcourses available through the Nonresident Instruction Section is found in Chapter 4 of DA Pamphlet 350-59, Army Correspondence Course Program Catalog. The DA PAM is available at the following website: <http://www.usapa.army.mil/pdffiles/p350-59.pdf>.

## **LESSON ASSIGNMENT**

### **LESSON 1**

Introduction to Human Anatomy

### **TEXT ASSIGNMENT**

Paragraph 1-1 through 1-15.

### **LESSON OBJECTIVES**

After completing this lesson, you should be able to:

- 1-1. Select correct answers to questions regarding osteology and arthrology, including general morphology of the bones and joints, bone classification, formation and growth, joint classification, and joint movement.

### **SUGGESTION**

After completing the assignment, complete the exercises at the end of this lesson. These exercises will help you to achieve the lesson objectives.

## LESSON 1

### INTRODUCTION TO HUMAN ANATOMY

#### Section I. ORIENTATION

##### 1-1. INTRODUCTION

a. The human body is a complex organism made up of various interdependent systems and components. Anatomy is the study of these components and the systems that they comprise. Put another way, anatomy is the study of the structure of the body, and the spatial relationship of its parts. Radiographic anatomy is the study of body structures that can be satisfactorily recorded as images of varying densities on x-ray film. Although the primary emphasis in radiographic anatomy will be on the skeletal system, as an X-ray technologist, you should be familiar with the structure of the whole body, and the interdependent systems of which it is comprised.

b. A detailed study of human anatomy and physiology is beyond the scope of this subcourse. Fortunately, you do not require such detailed knowledge. However, a basic knowledge of bones and their joints, their locations, and their surface landmarks, is essential for proper positioning of the patient. You should also know sufficient detail of the internal organ systems, including their components, locations, and functions, to perform the various radiographic procedures.

c. In the radiology department, you need to possess a thorough knowledge of medical and anatomical terminology so that you can communicate quickly and accurately with other members of the health care team. This knowledge will enable you to evaluate the situations in which you carry out your responsibilities, and to take the appropriate actions. For example, suppose that an ambulatory patient presents a request slip that shows a provisional diagnosis of arthritis with ankylosis of the right shoulder and elbow. You should immediately recognize that the patient has a fixed and inflamed right shoulder and elbow. This knowledge will influence the manner in which the exposure is made. You should do everything possible to position the patient in such a way as to cause minimum discomfort. In addition, you need to have sufficient knowledge of anatomy to interpret clinical requests correctly and to determine if the anatomical structures represented in the finished radiograph fulfill the requirements of the original request.

##### 1-2. MEDICAL TERMINOLOGY

a. **General Terminology.** The foundation for radiographic anatomy and allied subjects is centered primarily in medical terminology. As an X-ray technologist, you should know the meaning of the following general terms:

- (1) Science. Systematized and classified knowledge.
- (2) -ology (suffix). A science or branch of knowledge.
- (3) Regional or topographical anatomy. The study of separate parts of the body.

(4) Systemic anatomy. The study of systems and associated parts. Systemic anatomy is divided into these subdivisions:

- (a) Osteology. The study of the bones.
  - (b) Arthrology. The study of the articulations or joints.
  - (b) Myology. The study of the muscular system.
  - (c) Neurology. The study of the nervous system.
  - (d) Angiology. The study of the vascular/lymphatic vessels.
- (5) Embryology. The study of the origin of the structures of the body.
  - (6) Physiology. The study of the functions and activities of the body.
  - (7) Pathology. The study of changes in the structures or function of the body caused by disease or trauma.
  - (8) Radiology. That branch of medical science that deals with the use of radiant energy in the diagnosis and treatment of injuries and diseases.

**b. Normal Anatomical Position.** To avoid misunderstanding, a standard position of the human body (figure 1-1) is arbitrarily taken to be the erect (standing) position with feet flat on the floor, heels together, upper extremities at the sides, and palms, toes, and eyes directed forward. This is the anatomical position.

**c. Terms Dealing with Aspects and Directions.**

- (1) Anterior, frontal, or ventrum. The front side of the body.
- (2) Posterior or dorsum. The back, or dorsum, of the body.
- (3) Median. Pertaining to the midline of the body (figure1-1).

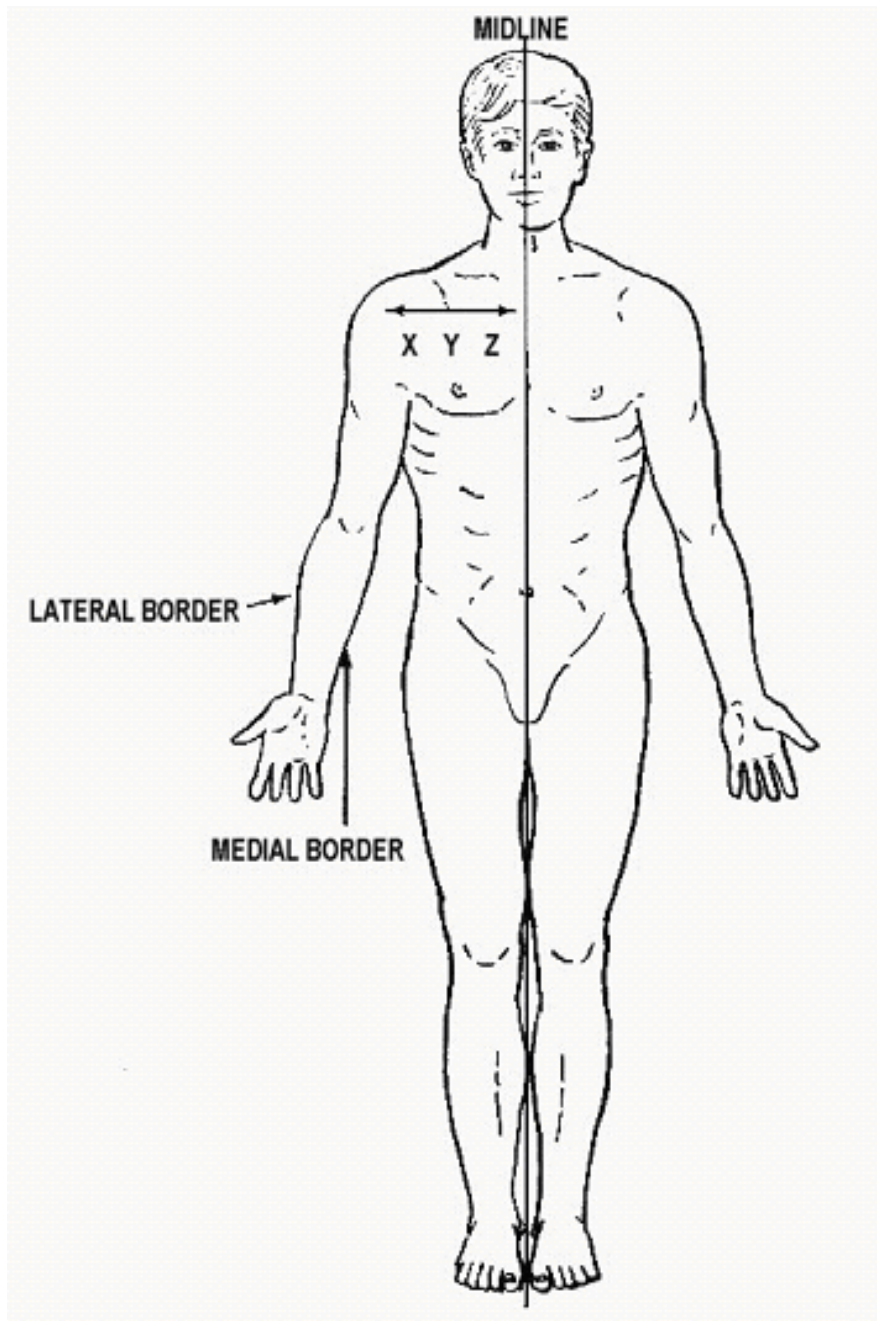


Figure 1-1. Medial-lateral relationships.

X is lateral to Y and Z. Y is medial to X and lateral to Z. In the example shown, the body is in the normal anatomical position.

(4) Lateral. Away from the midline or lateral side of the body (figure 1-1). In the forearm, the ulna is medial to the radius and the radius is lateral to the ulna. The thumb is on the lateral aspect of the hand.

(5) Proximal. Nearest to a point under consideration or the point of origin. In the case of the extremities, the articulations are considered points of origin (figure 1-2). For instance, the proximal end of the humerus is the upper end.

(6) Distal. Remoteness from a point under consideration or the point of origin; the opposite of proximal. In the case of the extremities, joints are considered points of origin (figure 1-2).

(7) Superior. Above.

(8) Inferior. Below.

(9) Cephalic. Toward the head (figure 1-3A).

(10) Caudal. Toward the feet (figure 1-3B).

d. **Radiographic Usage of Certain Terms.** In diagnostic X-ray services, such terms as anteroposterior (AP) or posteroanterior (PA) are frequently used. The prefix indicates the surface from which the central ray (CR) enters the part and the suffix indicates the surface from which the CR emerges.

e. **Planes of the Body** (figure 1-4).

(1) Sagittal plane. Any vertical plane that divides the body into right and left unequal portions.

(2) Median or midsagittal plane. The vertical plane that divides the body into right and left halves.

(3) Frontal or coronal plane. Vertical plane that divides the body into front and rear portions.

(4) Transverse or horizontal plane. Any horizontal plane that divides the body into upper and lower portions. The level of this plane must be given.

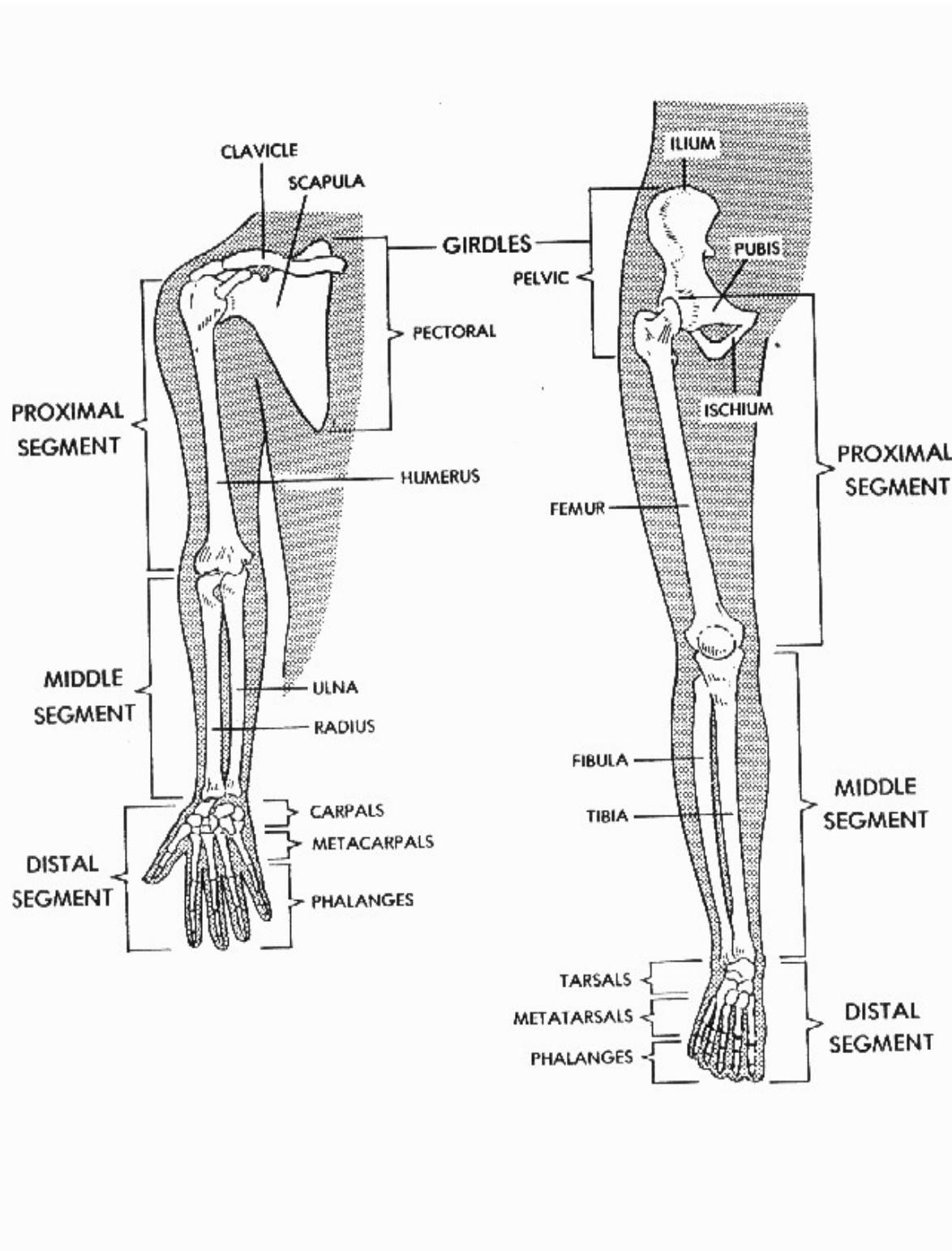


Figure 1-2. Proximal-distal relationships.

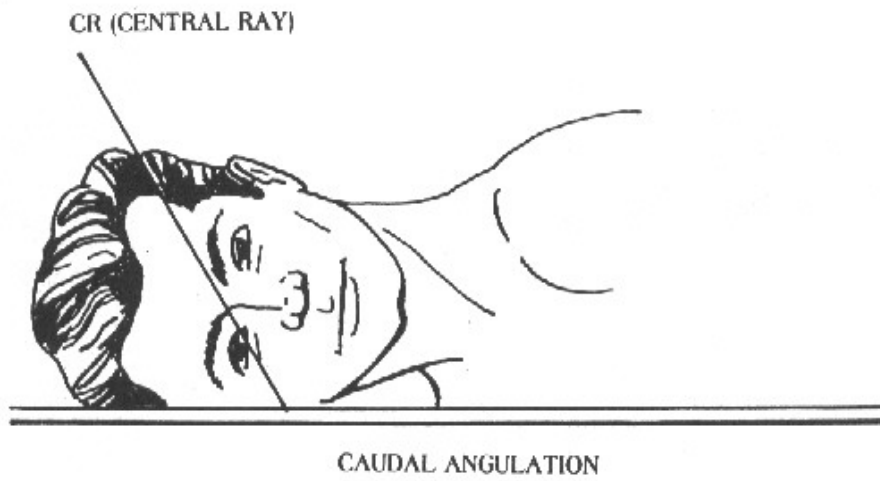
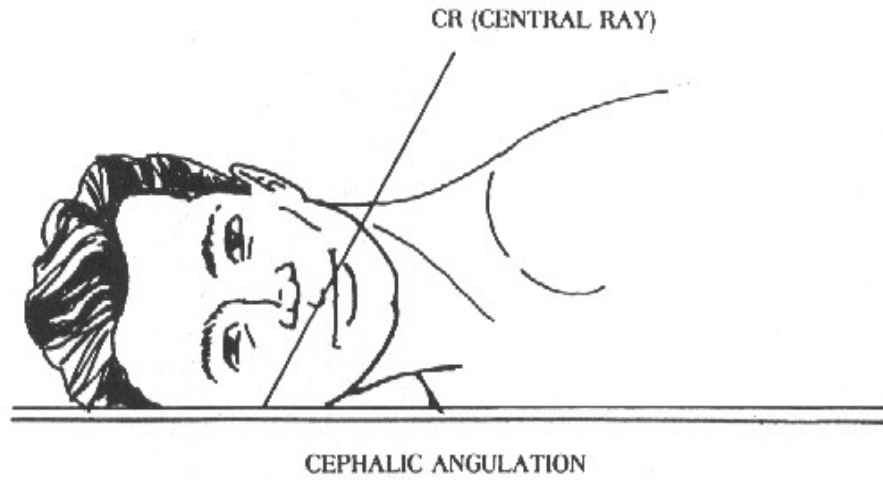


Figure 1-3. Angulation of x-rays. (A.) Cephalic angulation. (B.) Caudal angulation.



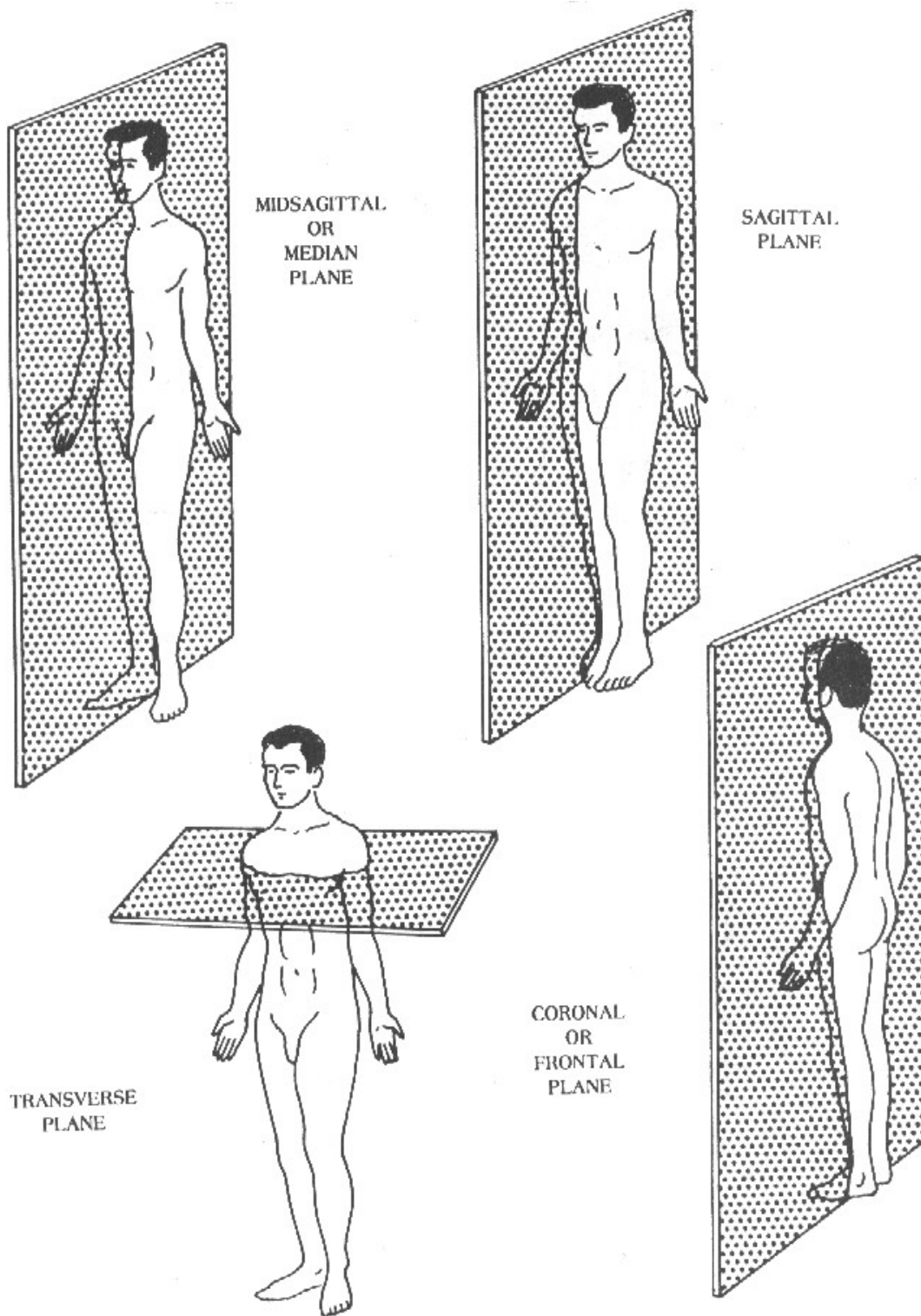


Figure 1-4. Planes of the body.

f. **Surfaces of the Hands and Feet.**

- (1) Palmar surface. Anterior surface (palm) of the hand.
- (2) Volar surface. Anterior surface of the hand and forearm (or the sole of the foot).
- (3) Plantar surface. Inferior surface (sole) of the foot.
- (4) Dorsal surface. Top or superior surface (dorsum) of the foot.

g. **Terminology Relating to the Positions of the Body** (figure 1-5).

- (1) Supine. A horizontal position of the body lying flat on the back with no rotation of the trunk.
- (2) Prone. A horizontal position of the body lying face and stomach down with no rotation of the trunk.
- (3) Lateral recumbent. A horizontal position of the body lying on either side with no rotation of the trunk.
- (4) Oblique. A position of the body, or any of its parts, when placed at an inclined angle to the X-ray film.
- (5) Erect or vertical. A position of the body either sitting or standing.

h. **External and Internal.** These terms are used to describe locations with respect to the surface.

i. **Body Types.** Four terms are generally used to designate the four major types of body habitus (figure 1-6). Since the position of certain organs (for example, the gallbladder) can vary as much as 6 to 8 inches between body types, it is essential that the X-ray specialist be familiar with these major body types.

- (1) Hypersthenic. The hypersthenic body (figure 1-6A) is of massive build with a broad and deep thorax. The diaphragm is high and the stomach and gallbladder also occupy high positions. An extreme body type, the hypersthenic classification accounts for only about five percent of all people.

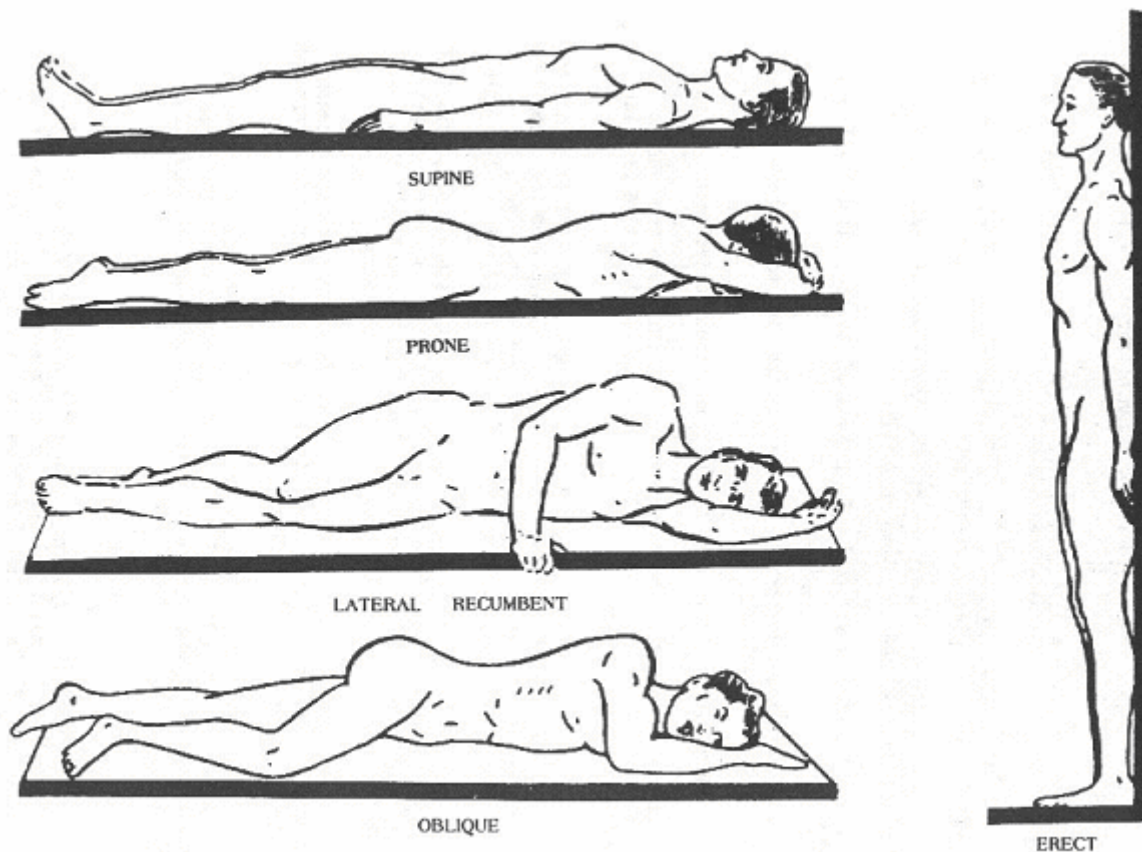


Figure 1-5. Body positions.

(2) Sthenic. Means active or strong. The sthenic body (figure 1-6B) is the one we usually associate with the athletic type. The body is rather heavy with large bones. The sthenic body type is the predominant type, with about half of all people falling into this classification.

(3) Hyposthenic. Slender and light in weight with the stomach and gallbladder situated high in the abdomen (figure 1-6c). About 35 percent of all people fall into this classification.

(4) Asthenic. Extremely slender, light build, with a narrow, shallow thorax, and the gallbladder and stomach situated low in the abdomen. An extreme type, the asthenic classification accounts for only about ten percent of all people (figure 1-6D).

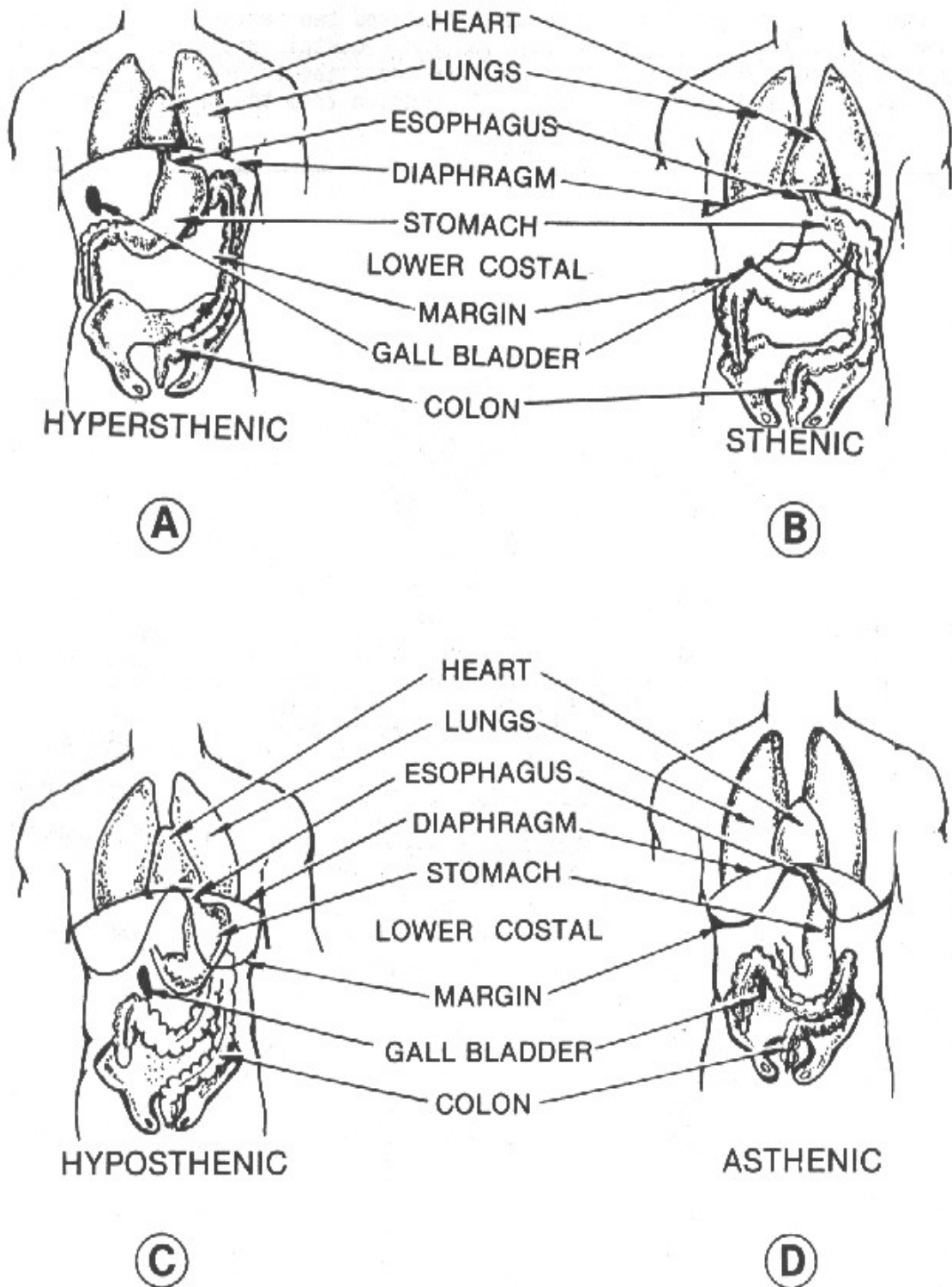


Figure 1-6. Major body types.

**j. Regions of the Abdomen.**

(1) The abdomen is that portion of the body that lies between the thorax and the pelvis. It consists of a large cavity, separated from the thoracic cavity by the diaphragm, bounded by muscles and fascia, and partially lined with a serous membrane called the peritoneum.

(2) For purposes of description, the abdomen is divided into nine regions (figure 1-7) by means of two horizontal and two vertical lines. The upper horizontal line passes through the tenth costal cartilage inferiorly. The lower line passes through the level of the iliac tubercle. Each vertical line passes through the midpoint of a line drawn from the anterior superior iliac spine to the symphysis pubis.

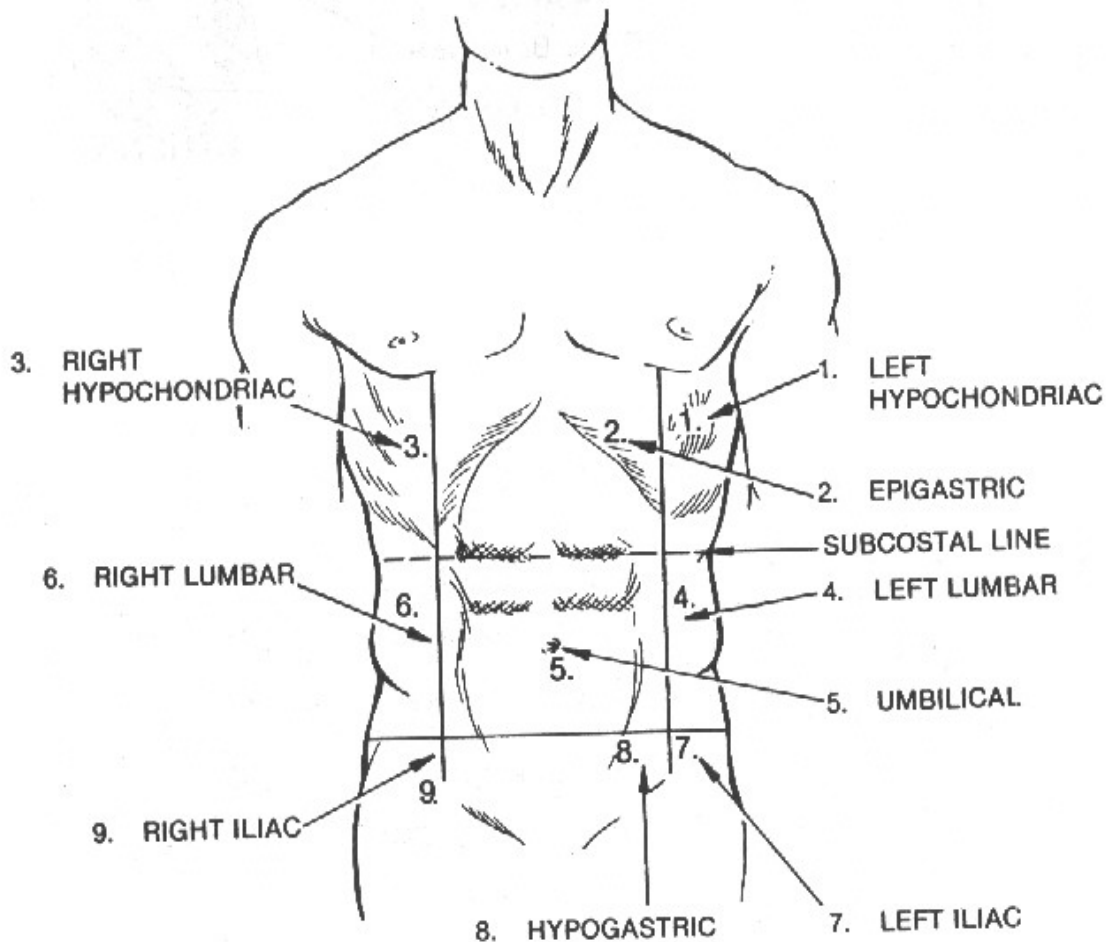


Figure 1-7. Regions of the abdomen.

## Section II. CELLS

### 1-3. GENERAL

The cell is the basic structural, functional, and developmental unit of the body. The human body contains hundreds of trillions of cells, each of which is capable of performing the necessary functions of life.

### 1-4. CELL STRUCTURE

There is no typical cell that can be examined to determine the functions of the various parts. However, most cells have certain basic common components and it is, therefore, possible to visualize and describe a composite cell that combines the observed features of numerous cell types. Such a composite cell would be made up of the following components (figure 1-8).

a. **Cell Membrane.** Each somatic (body) cell is surrounded by a semi permeable membrane that controls the exchange of nutrients and waste between the cell and its environment.

b. **Nucleus.** A cell usually contains a nucleus surrounded by some form of protoplasm and enclosed by a semi permeable membrane. The nucleus has been called the control center of the cell. One important known function of the nucleus is the transmission of hereditary traits. This is actually carried out by the chromosomes or chromatin material that is found in the nucleus of the cell. Chromosomes are made up of DNA (deoxyribonucleic acid), which has been called the "super molecule." The cell nucleus also contains a thick fluid called karyoplasms in which are suspended small bodies known as nucleoli.

c. **Cytoplasm.** Cytoplasm is the fluid substance surrounding the nucleus and surrounded by the cell membrane. Suspended within the semi liquid cytoplasm are living bodies (organelles) and nonliving substances such as proteins, fat droplets, pigments, and various crystals. Within the cytoplasm are found the following:

(1) Centrosome. Usually located near the cell nucleus and believed to initiate cell division.

(2) Mitochondria. Minute fluid bodies in which numerous chemical reactions occur from which the cell's energy is derived. Mitochondria are sometimes called the power plants of the cells.

(3) Lysosomes. Digestive centers which break down large molecules and which aid in destroying the cell at the end of its useful life.

(4) Ribosomes. Believed to synthesize protein.

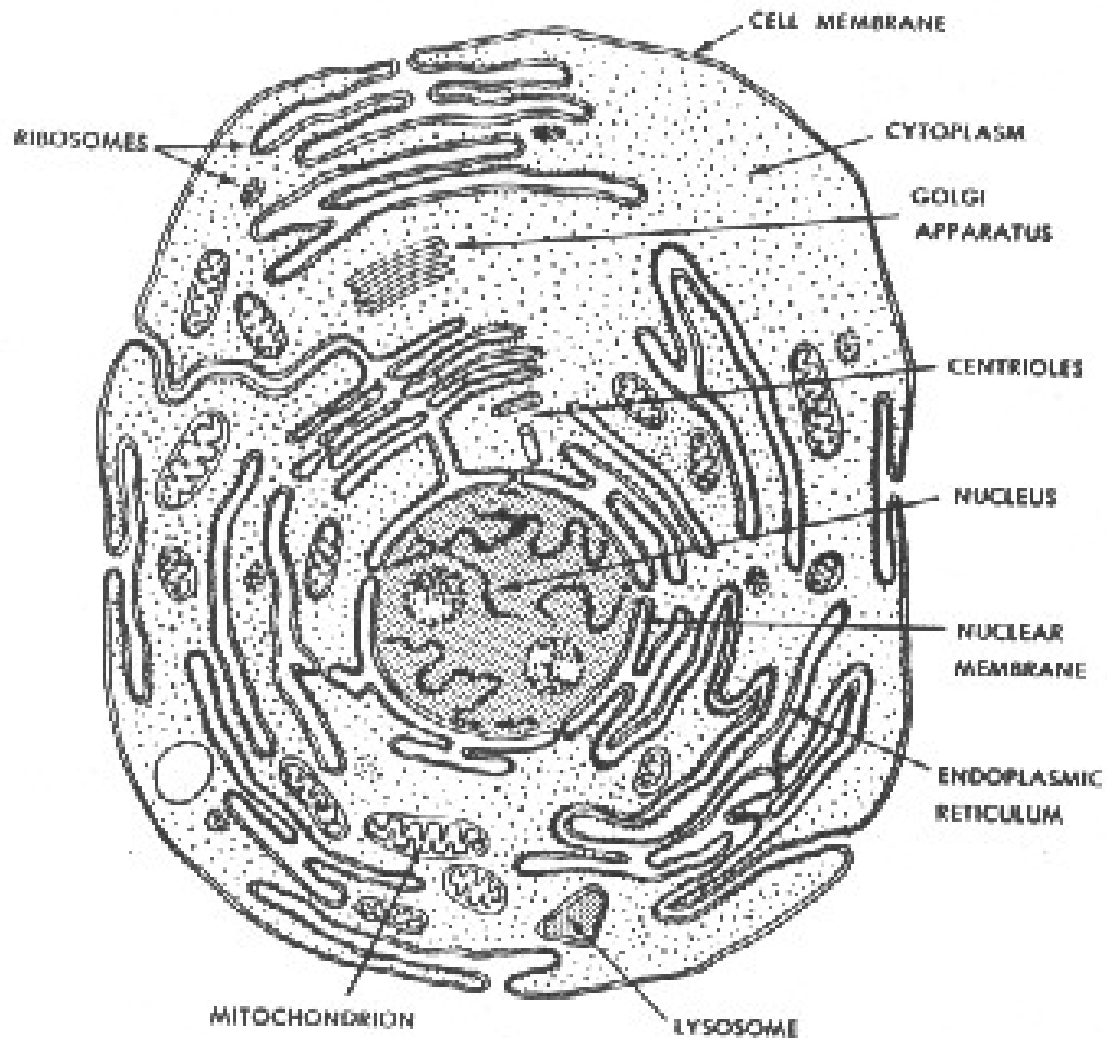


Figure 1-8. Diagrammatic representation of a cell.

(5) The endoplasmic reticulum. A network of internal membranes which form a series of small canals through the cytoplasm for the purpose of transporting substances from the cell membrane to the nuclear membrane.

(6) Golgi body (or com la ex). A series of smooth membranes continuous with the endoplasmic reticulum which is believed to have something to do with regulating the movement of fluids in the cell.

(7) Fibrils. Thin, protoplasmic threads in the cytoplasm that probably give the cell structural support.

## 1-5. CELL DIVISION

The two basic types of human cells, somatic cells and sex cells, mature and increase in number through processes known as mitosis and meiosis, respectively.

a. **Mitosis.** Mitosis is the form of cell division that occurs in higher forms of animal life, including man. This form of cell division consists of four phases (prophase, metaphase, anaphase, and telophase) during which the chromatin material in the nucleus undergoes various changes in arrangement, leading to the ultimate division of the cell. The result of mitosis of a somatic cell is two daughter cells, each of which possesses the same number of chromosomes as the parent cell (figure 1-9). In humans, each somatic cell contains 23 pairs, or 46 chromosomes.

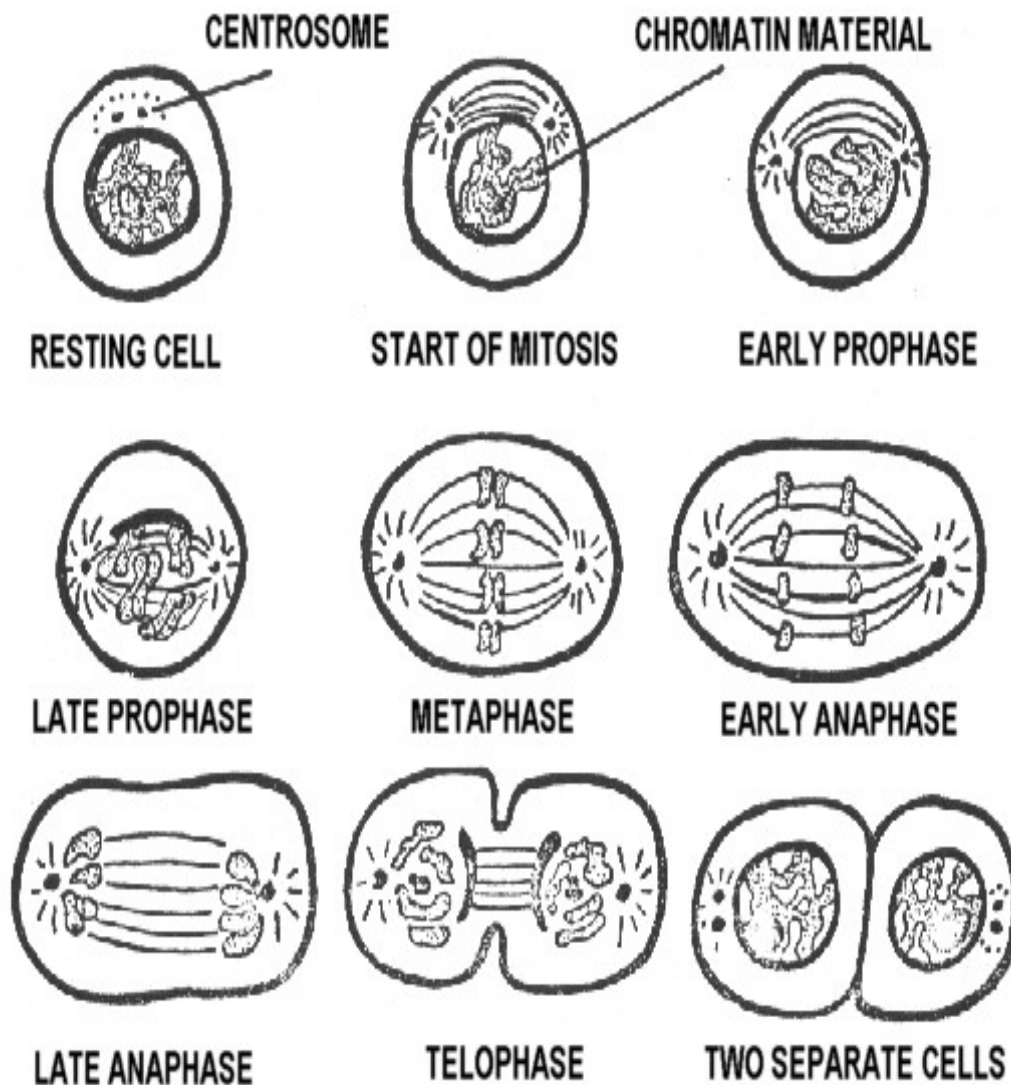


Figure 1-9. Diagrammatic representation of mitosis.



b. **Meiosis.** Sex cells mature and propagate by a different process than somatic cells. This process is called meiosis. In meiosis, the series of nuclear changes within the sex cell results in the production of new cells with half the number of chromosomes present in the original sex cell. Meiosis occurs in both female and male sex cells, resulting in the formation of ova and spermatozoa, respectively. The union of a mature spermatozoa and a mature ovum results in the formation of a new individual. As a result of meiosis, the chromosome number remains constant from one generation to the next. For this reason, meiosis is sometimes called reduction division.

## 1-6. TISSUE

Somatic cells are usually classified as either epithelial, muscle, nerve, or connective. Cells arranged or organized to perform one or more specific functions are called a tissue. The four basic tissue types found in the human body are classified according to the type of cells that comprise them and have these specialized functions.

- a. **Epithelial Tissue.** Forms linings and coverings of various body parts and systems.
- b. **Muscle Tissue.** Contracts to cause movement and to maintain body posture.
- c. **Nerve Tissue.** Conducts messages (impulses) to and from the central nervous system.
- d. **Connective Tissue.** Serves as filler and binder substances of the body and forms the supporting framework of the body and the body organs.

## Section III. BONES

### 1-7. BONES OF THE SKELETON

a. The normal adult human body has approximately 206 bones. This includes the auditory ossicles and the patella, but excludes the small sesamoid bones. Figure 1-10 shows a human skeleton in anatomical position.

b. The skeleton may be divided into the appendicular and the axial skeleton. The appendicular skeleton includes the bones of the upper and lower free extremities, the shoulder (pectoral girdle), and the pelvic girdle. The axial skeleton includes the bones of the skull, the vertebral column, the thoracic cage, the auditory ossicles, and the hyoid bone.

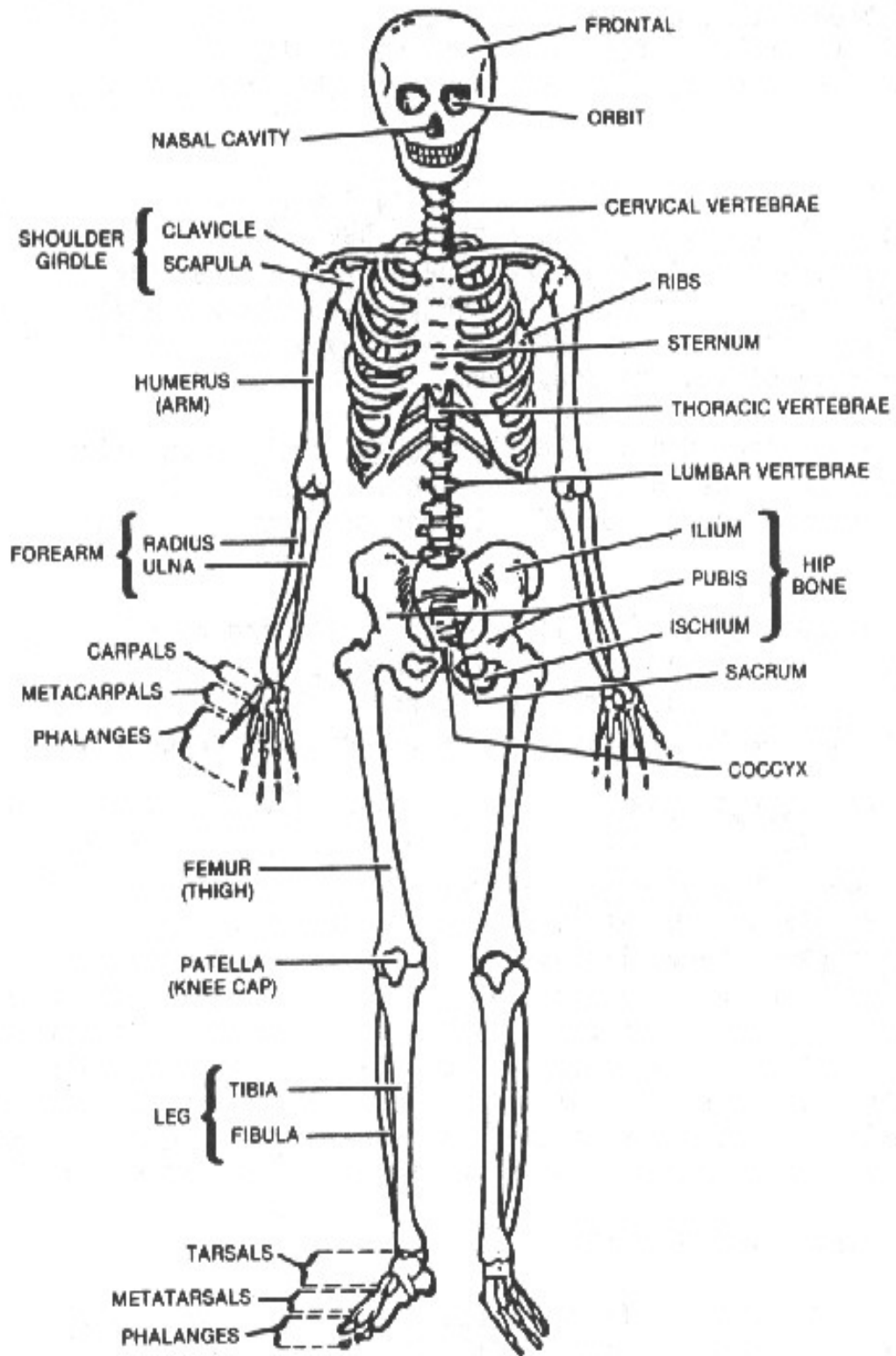


Figure 1-10. The skeleton

## 1-8. BONE STRUCTURE

a. **General.** Bone is a tissue composed of living cells (osteocytes) distributed in an intercellular matrix that contains organic and inorganic substances. The organic component, largely collagenous fibers, is responsible for the strength and resilience of bone while the inorganic salts, mostly calcium phosphate, contribute to its hardness, and rigidity. The inorganic constituents make up approximately 67% of bony matter in the adult. The radiopacity of bone depends largely upon the amount of minerals present. Lack of mineral content in the young and aged alters the radiopacity and requires compensation.

b. **Forms of Bone Tissue.** There are two forms of bone tissue, cancellous and compact. Cancellous or spongy bone consists of irregular strands of tissue, which branch and join one another, forming a loose network in which the intercommunicating spaces are filled with marrow. Compact or dense bone has a more solid, regular appearance and its intercommunicating canals are microscopic in size. The basic structure of these two types of bone is essentially the same. They differ mainly in the relative amount of solid substance and the number, size, and arrangement of the intercommunicating spaces they contain. Both cancellous and compact forms are present in most bones of the body, but the extent and distribution of each varies considerably. In adults, the exterior of all bones is compact bone while the interior is usually cancellous.

c. **A Typical Long Bone.** In a typical long bone (figure 1-11), each end (epiphysis) is largely cancellous and is covered by a thin layer of compact bone. The reverse is true in the shaft (diaphysis), which is mostly compact bone tissue. The central medullary canal, or cavity in the shaft of a long bone, is continuous with the intercommunicating spaces in the cancellous bone located at the ends. Depending on the age of the individual and the type of bone considered, either red or yellow marrow fills these cavities. Red marrow, active in the production of blood cells, is present in all bones at birth and blood cells are produced in all locations. With advancing age, the production of blood cells decreases and red marrow is replaced by yellow marrow, which consists mostly of fat cells. In the adult, red marrow is found mainly in the skull, vertebrae, ribs, sternum, and the articular ends of some long bones.

d. **Long Bone Structure.** Each long bone, except for its articular surface, is enclosed by a thick, fibrous sheet of membranous tissue, called the periosteum, which develops when the perichondrium, the outer covering of the embryonic skeleton, becomes permeated with blood vessels. The marrow cavity, and also the canal system, are lined by a delicate layer of reticular (netlike) tissue, called the endosteum.

e. **Some Other Bones.** In flat bones, such as the ribs, one or more plates of compact bone surround the cancellous bone. In many irregular bones, such as the vertebrae, spongy bone is enclosed by a thin shell of compact bone.

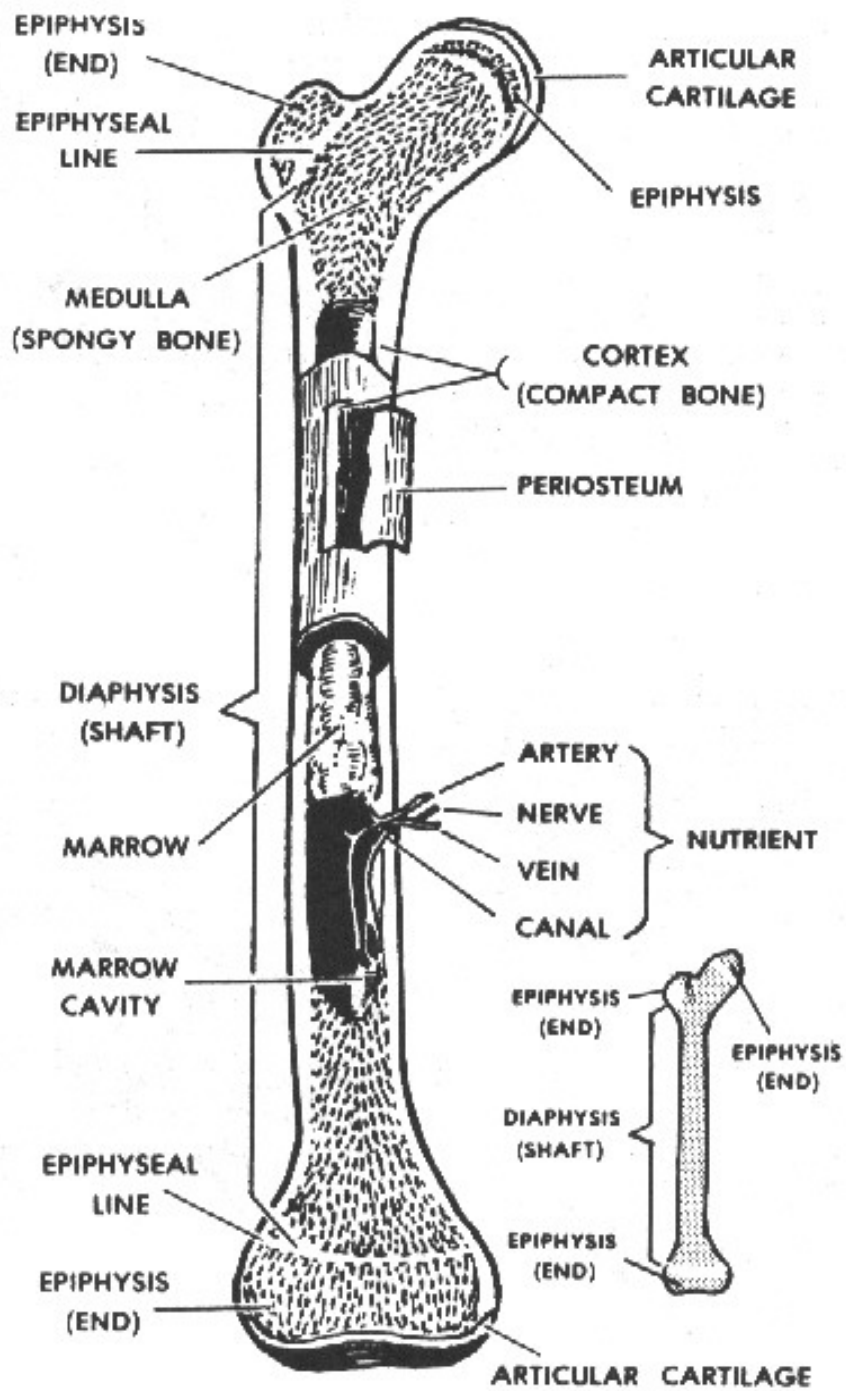


Figure 1-11. Longitudinal section of a long bone (femur).

f. **Blood Supply.** The living bone cells are nourished by a system of blood vessels and capillaries. In the long bones, for example, blood vessels in the shaft supply the bone marrow. Branches of blood vessels contained in the periosteum supply the compact and cancellous bone areas.

g. **Microscopic Structure.** When bone tissue is examined under a microscope, it is seen in layers either as a series of flat plates (for cancellous bone) or concentric cylinders (for compact bone). In compact bones, the series of concentric cylinders are formed in units called haversian systems. Here, living bone cells lie in minute cavities called lacunae. The lacunae communicate with each other, and indirectly with a central haversian canal, through a system of microscopic canals called canaliculi that contain protoplasmic extensions of bone cells. They are nourished by blood vessels from the periosteum that enter the compact bone through small pits on the surface. Branches of these blood vessels penetrate the matrix and enter the central haversian canal in each haversian system.

## 1-9. CLASSIFICATION OF BONES

Bones may be classified according to shape. This classification is of special interest to the X-ray specialist.

a. **Long Bones.** These are long, usually cylindrical, shafts with two expanded extremities. Long bones are radiographed lengthwise on the film. The humerus (figure 1-12A) of the arm is an example of a long bone.

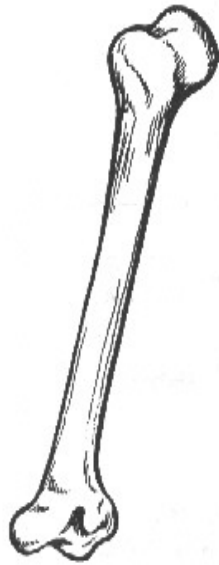
b. **Short Bones.** These bones are short, usually cylindrical shafts, with two expanded extremities. They usually occur in groups, like the metacarpals of the hand (figure 1-12B). Generally, short bones are radiographed crosswise on the film.

c. **Flat Bones.** Flat bones consist of two plates of hard, bony substance with a layer of spongy, red marrow in between. In the adult, the red marrow is the normal site for the production of granulocytes (granular leukocytes) and erythrocytes. The scapula (figure 1-12C) is an example of a flat bone.

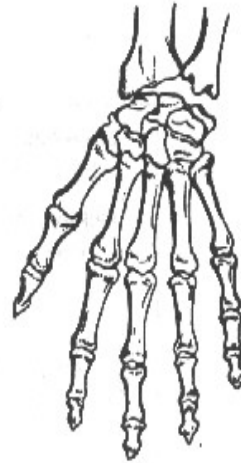
d. **Irregular Bones.** These are bones whose size and shape are modified by their function and position. The vertebrae (figure 1-12D) are examples of irregular bones.

e. **Sesamoid Bones.** Sesamoid bones are small bones embedded in tendons that pass over the joints. In addition to lessening friction, they modify pressure and help to protect ligaments and tendons. The patella (kneecap) of the knee joint (figure 1-13) is an example of a sesamoid bone. Sesamoid bones are also situated within the palm of the hand and the plantar surface of the foot.

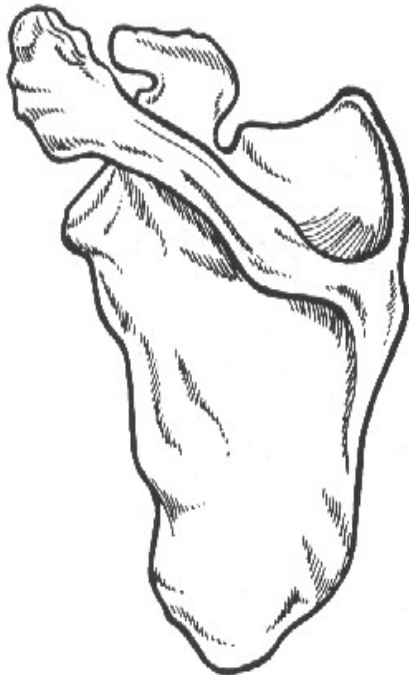f. **Supernumerary Bones.** These are "extra" bones of the skeletal system, such as an extra vertebra or rib, plus most sesamoid bones.



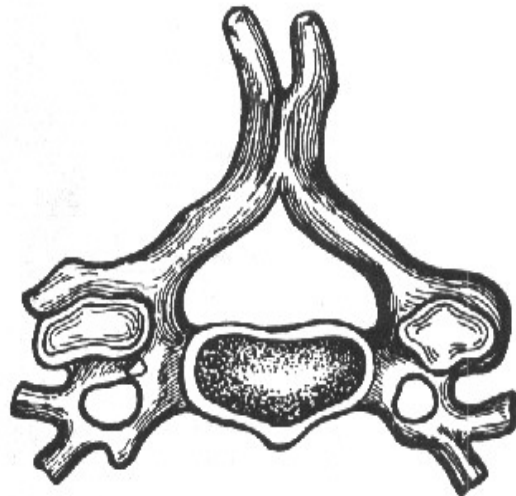
A. LONG BONE (HUMERUS)



B. SHORT BONE (METACARPAL)



C. FLAT BONE (SCAPULA)



D. IRREGULAR BONE (VERTEBRA)

Figure 1-12. Types of bones.

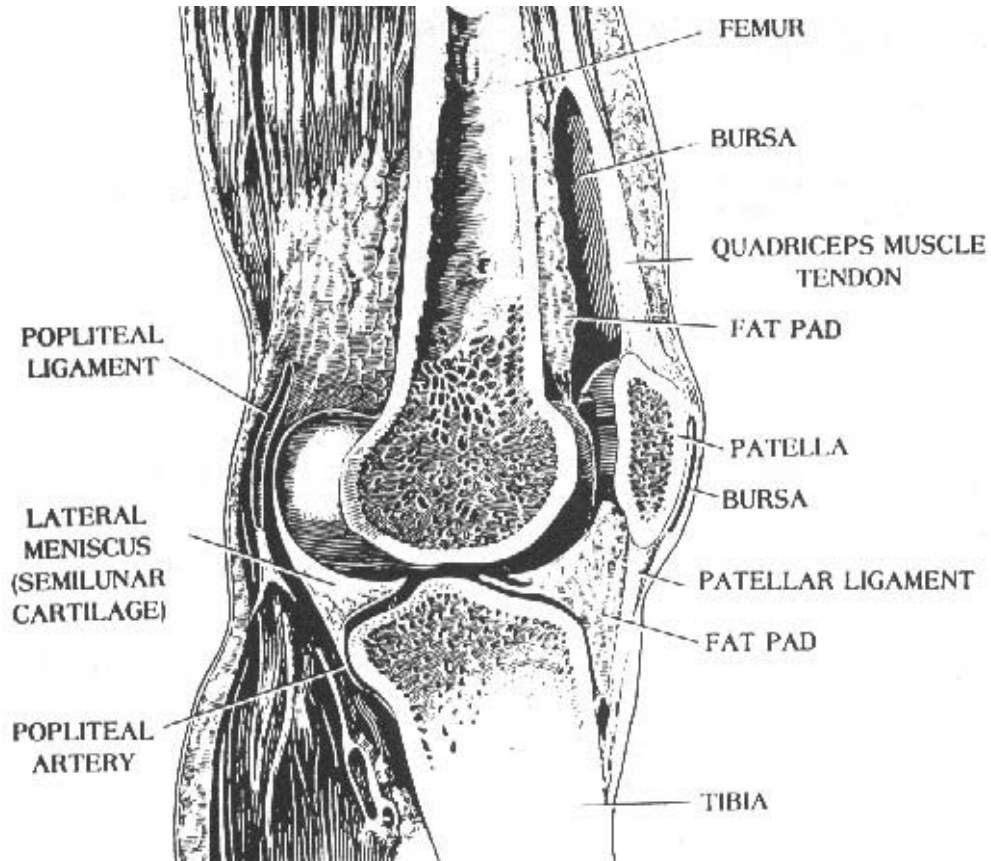


Figure 1-13. Sesamoid bone (the patella).

## 1-10. BONE FORMATION AND GROWTH

a. **Fibrous-Membrane Formation (Intramembranous).** The bones of the cranium are formed from a fibrous membrane. In various portions of the membrane, ossification centers develop. From these centers, tiny calcium spines radiate in all directions; thus, a compact network of bone is formed centrally with peripheral areas being much less compact. Between the radiating calcium columns, the osteoblasts (bone-forming cells) construct the bone. Eventually, the periosteum is formed from the membrane; the subperiosteal osteoblasts form the inner and outer tables of compact bone; and the endosteal osteoblasts form the cancellous bone. The bone marrow occupies the spaces within the cancellous bone (diploe). The bones of the cranium are not completely ossified at birth and the membranous areas are called fontanelles. See Figure 1-14 for an illustration of an infant's skull showing anterior and posterior fontanelles.

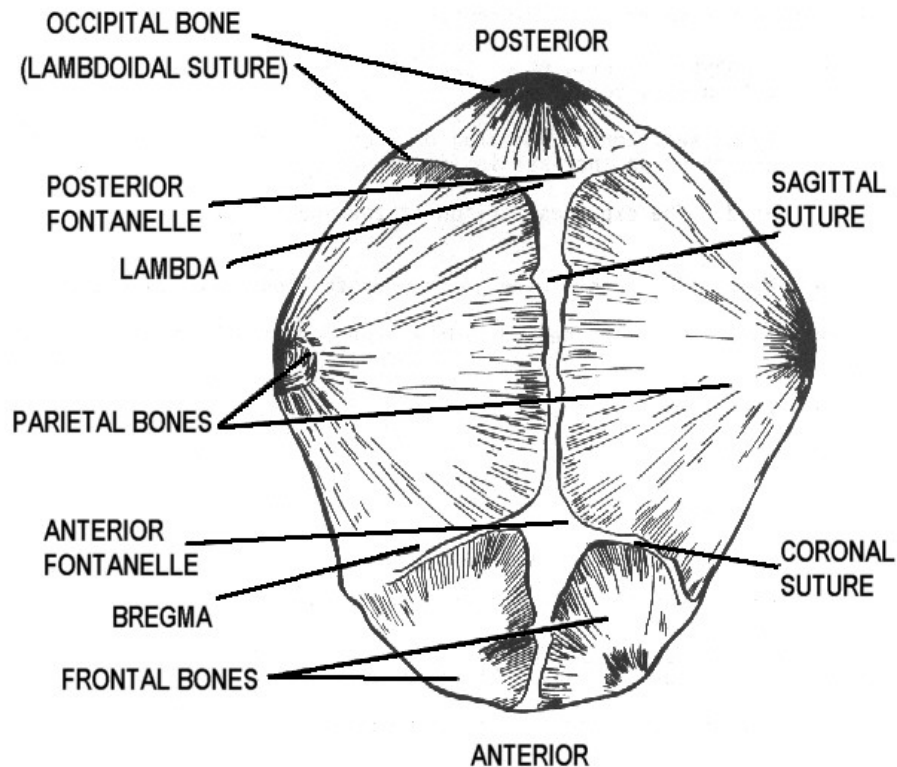


Figure 1-14. Anterior and posterior fontanelles, infant's skull.

b. **Cartilaginous (Endochondral) Formation.** The tones of the rest of the skeleton are preformed in cartilage. Ossification proceeds from an ossification center toward the extremities, which remain cartilaginous for some time. Subsequently, a similar process begins in one or more places in the extremities and gradually proceeds toward the center. An area of cartilaginous tissue persists after birth for various periods of time. In infants and children, this area affords growth in length. It is called the epiphyseal zone (the suffix "physeal" means "growth").

c. **Cranial Growth.** Growth of the cranial bones is affected in formative steps, which are modifications of intramembranous formation. Their development entails ossification of the membranous fontanelles that becomes complete when the child is approximately 2 years old.

d. **Growth of Other Bones.** The remaining bones of the skeleton undergo changes similar to those of a long bone during growth, that is, an increase in diameter and length. The periosteum that covers the bone contains osteoblasts that progressively deposit layers of bone to form the external portion of the bone. Correlated with this growth in diameter externally, osteoclasts (bone-destroying cells) in the endosteum destroy some of the bone internally, thereby enlarging the internal (medullary) canal. Growth in length takes place in the epiphyseal zones. The shaft is called the diaphysis and the end of the bone is called the epiphysis (figure 1-11).



e. **Maturity Rates.** The time required for the bones to reach full development varies for different parts of the skeleton. The skeleton matures somewhat earlier in the female than in the male. The appearance of the epiphyseal centers of ossification and their development can be followed by radiographic examination. Some appear at birth while others appear from time to time during the first 15 years of life. Later, the epiphysis and shaft of the bone unite. Ordinarily, all have united by the age of 25.

## 1-11. DESCRIPTIVE TERMINOLOGY

By reviewing the following terms, it will help you understand the discussion of bones more easily.

a. **Extremity.** The distal or terminal portion of a bone. An arm or leg is also referred to as an extremity.

b. **Diaphysis, Shaft, or Body.** The long, cylindrical part or the principal portion of a bone.

c. **Epiphyseal Zone.** The area between the shaft and the end of a bone where growth or an increase in length occurs.

d. **Head.** The expanded portion at the end of a bone, usually rounded.

e. **Neck.** The constricted portion of the bone next to the head.

f. **Base.** The expanded portion at the end of a bone opposite to its head.

g. **Ramas.** A branch of a bone.

h. **Projections.**

(1) Process. A general term for a projection.

(2) Spine. A sharp projection.

(3) Tubercle. A small, rounded, rough projection.

(4) Tuberosity. A large eminence (prominence or projection), usually roughened, for the attachment of tendons or ligaments.

(5) Styloid process. Like a stylus.

(6) Trochanter. A very large, roughened process.

(7) Crest. A projecting ridge of bone.

(8) Condyle. A smooth, rounded, swelling at the articular end of a bone.

(9) Epicondyle. A small eminence of bone above the condyle, usually roughened.

(10) Coracoid process. A beak-like process.

(11) Coronoid process. A crown-like process.

(12) Malleolus. Process resembling a little hammer.

**i. Depressions Found on Bones.**

(1) Fossa. Shallow depression.

(2) Facet. A smooth depression on the surface of a bone for articulation with another bone.

(3) Groove or sulcus. An elongated depression on the surface of a bone; a furrow.

(4) Pit. An indentation.

**j. Other Terms Relating to Bones.**

(1) Fissure. A narrow slit between two bones.

(2) Foramen. A hole or opening in a bone.

(3) Sinus or antrum. Terms used to designate a hollow space within a bone.

(4) Meatus. An opening to a passageway.

## **1-12. CARTILAGE**

Cartilage is a living tissue that occurs in three forms: hyaline cartilage, white fibrocartilage, and yellow or elastic cartilage.

**a. Hyaline Cartilage.** The most common of the three, it appears as a bluish-white, translucent substance and is very flexible and somewhat elastic. In the early embryo, the skeleton is composed of this type of cartilage; but during fetal development, most of this embryonic skeleton is replaced by bone. However, in the adult, hyaline cartilage persists in the smooth, articular, surfaces of joints, in the costal cartilages, in the rings of the trachea and bronchi, and in the cartilage of the nose.

b. **White Fibrocartilage.** Exceptionally tough and resilient, it is found in pads or disks between the vertebrae where it provides a cushioning effect. It attaches tendons and ligaments to hyaline cartilage and is also found where limited movement occurs (for example, between the articular surfaces of the bones of the skull).

c. **Yellow or Elastic Cartilage.** More flexible and elastic than true hyaline cartilage, it occurs where movement of cartilaginous structures is necessary. An example of this is found in the epiglottis. Elastic cartilage is also found in the larynx, external ear, and eustachian tube.

### 1-13. JOINTS

a. **General.** Bones of the skeleton meet in areas called joints or articulations. According to the amount of movement they permit, joints are classified as immovable, slightly movable, and freely movable (figure 1-15).

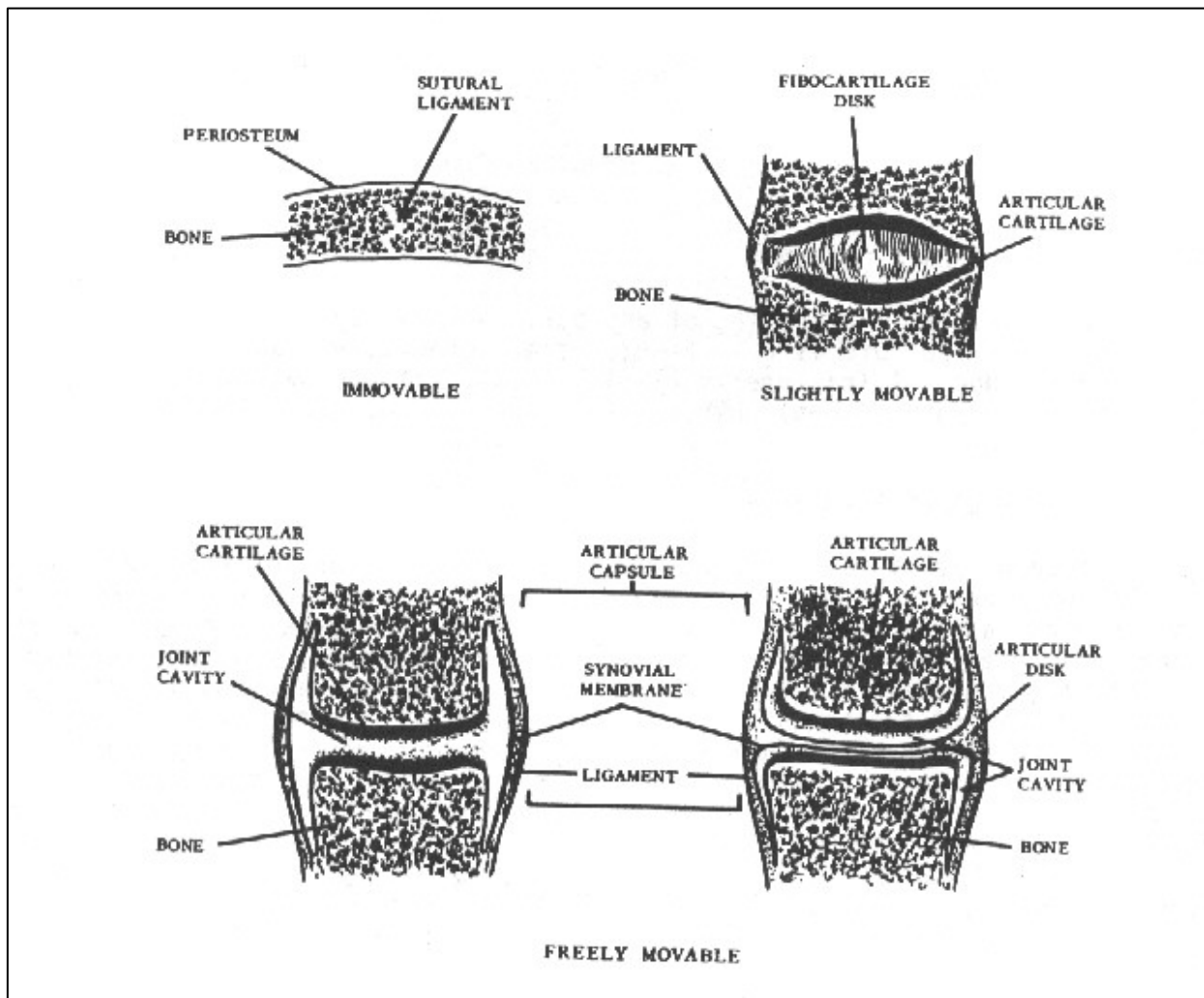


Figure 1-15. Types of joints

(1) Immovable joints or synarthrosis. These allow no appreciable movement and the bones are fastened together by cartilage or fibrous tissue. The bones of the skull are united by one type of immovable joint called a suture.

(2) Slightly movable joints or amphiarthroses. These permit limited movement and the bony surfaces are connected by fibrocartilage, often in the form of a disk. These joints are exemplified in the intervertebral spaces and in the symphysis pubis.

(3) Freely movable joints or diarthroses. The freely movable joints permit varying types of movement as discussed below. The articular surfaces of these bones are covered with hyaline (articular) cartilage and encased by an articular capsule ligament that is attached to both bones near the articulating end, holding them together. The cavity of the capsule contains synovial fluid that lubricates the joint. In some joints, an articular disk is also found between the articulating layers. Most joints of the body are freely movable (diarthrodial) and may be classified as shown below:

DIVISION	MOVEMENT	EXAMPLE
Anhrodia (Gliding)	Gliding	Sternoclavicular
Enarthrosis Ball-and-Socket	Angular, Rotation, Circumduction	Hip
Condyloid	Angular, Circumduction	Wrist
Ginglymus (Hinge)	Angular (Single Axis)	Elbow
Trochoides (Pivot)	Rotation	Atlas-axis
Saddle	Angular	Carpometacarpal of the thumb

**b. Types of Joint Movement.** Muscles are attached to bones by tendons (cords of white fibrous connective tissue). Contracting muscles provide the forces which, when transmitted to the bone, institute various movements. The different types of movement are described below.

(1) Gliding movement. Limited to a sliding of articular surfaces over each other.

(2) Angular movement.

(a) Adduction. Movement toward the median plane of the body.

(b) Abduction. Movement away from the median plane of the body.

(c) Flexion. Movement to decrease the angle between adjoining parts.

(d) Extension. Movement to increase the angle between adjoining parts.

(e) Circumduction. Movement in which the bone circumscribes a pointed cone. The base of the cone is distal to the joint; the apex is the joint.

(f) Rotation. The part turns about its own axis without changing position.

(g) Pronation. To turn the palm of the hand (from the normal anatomical position) posteriorly.

(h) Supination. To turn the palm of the hand from posterior to anterior (thus regaining the normal anatomical position).

(i) Inversion. To turn the sole of the foot inward.

(j) Eversion. To turn the sole of the foot outward.

## **Section IV. COMMON FRACTURES**

### **1-14. GENERAL CLASSIFICATIONS**

A fracture is the breaking of any part, especially a bone. The abbreviation for fracture is Fx. Fractures are generally classified as simple or compound. A fracture is W (closed) if the overlying skin is intact; it is compound (open) when there is an external wound leading to the break of the bone.

### **1-15. SPECIFIC CLASSIFICATIONS**

Fractures are further classified by position, number of fragments, and direction of fracture line. A transverse fracture is usually a straight-line break at right angles to the long axis of the bone. A spiral fracture has an S-shape fracture line. The fracture line of a longitudinal fracture roughly parallels the long axis of the bone. An oblique fracture extends diagonally to the long axis of the bone. With an impacted fracture, the broken ends or fragments are jammed firmly together. In the case of a greenstick fracture, one side of the bone is broken and the other side bent. A comminuted fracture is one in which the bone is crushed or splintered into three or more fragments. A stellate fracture is a fracture with a central point of injury from which radiate numerous fissures. A buttonhole fracture is a fracture in which the bone is perforated by a missile. A compression fracture is produced by compression and usually results in a decrease of the size of the bone.

**Continue with Exercises**

## EXERCISES, LESSON 1

**INSTRUCTIONS:** Answer the following exercises by marking the lettered response that best answers the exercise, by completing the incomplete statement, or by writing the answer in the space provided at the end of the exercise.

After you have completed all the exercises, turn to "Solutions to Exercises" at the end of the lesson and check your answers. For each exercise answered incorrectly, reread the material referenced with the solution.

1. A knowledge of medical terminology can help the X-ray specialist to:
  - a. Communicate more effectively with other members of the health care team.
  - b. Position the patient.
  - c. Interpret clinical requests.
  - d. All of the above.
  
2. Under which subdivision of systemic anatomy would information about joints and articulations be found?
  - a. Arthrology.
  - b. Pathology.
  - c. Embryology.
  - d. Myology.
  - e. All of the above.

3. The study of changes in the structure or function of the body caused by disease or trauma is called:
  - a. Radiology.
  - b. Physiology.
  - c. Embryology.
  - d. Pathology.
  
4. What term is used when referring to the front side of the body?
  - a. Anterior.
  - b. Proximal.
  - c. Medial.
  - d. Superior.
  
5. In what direction should an X-ray tube be pointed if you wish to direct the central ray in a cephalad angulation?
  - a. Toward the wrist.
  - b. Toward the head.
  - c. Toward the feet.
  - d. Perpendicular to the patient.
  
6. The vertical plane that divides the body into right and left halves is the \_\_\_\_\_ plane.
  - a. Frontal.
  - b. Sagittal.
  - c. Median.
  - d. Transverse.

7. In figure 1-1 of the subcourse, the \_\_\_\_\_ surfaces of the hands and forearms are shown.
- a. Volar.
  - b. Plantar.
  - c. Dorsal.
  - d. Lateral.
8. The body type possessed by almost half of all people is the \_\_\_\_\_ type.
- a. Asthenic.
  - b. Hypersthenic.
  - c. Hyposthenic.
  - d. Sthenic.
9. What condition found in the bones of aged patients affects X-ray technique factors?
- a. Low mineral content.
  - b. Little or no fatty tissue.
  - c. Loss of muscle tone.
  - d. Excess muscle and fatty tissues.
10. What fibrous membrane covers the outer layer of a long bone?
- a. Basilar.
  - b. Epithelial.
  - c. Periosteum.
  - d. Perichondrium.



11. Under which classification of bones would the humerus be listed?
  - a. Flat.
  - b. Short.
  - c. Irregular.
  - d. Long.
  
12. A bone grows when there is activity in the:
  - a. Periosteum.
  - b. Epiphyseal zones.
  - c. Endosteum.
  - d. Fontanelles.
  
13. What is the name of the bone-forming cells?
  - a. Osteoclasts.
  - b. Diploe.
  - c. Fontanelles.
  - d. Osteoblasts.
  
14. In the production of bone, what is the function of the epiphyseal zones?
  - a. Make the bone grow in length.
  - b. Cause the diameter of the bone to increase.
  - c. Destroy some of the bone internally.
  - d. Cover the medullary cavity of a bone.

15. Normally, at what age have the epiphysis and shaft of the bones all grown together?
- a. Birth.
  - b. Five years.
  - c. Fifteen years.
  - d. Twenty-five years.
16. A smooth swelling at an articular end of a bone is called a(n):
- a. Trochanter.
  - b. Epicondyle.
  - c. Condyle.
  - d. Crest.
17. What name is usually given to a hammer-like projection found on a bone?
- a. Coracoid process.
  - b. Coronoid process.
  - c. Malleolus.
  - d. Tubercle.
18. A hole or opening in a bone is referred to as a:
- a. Foramen.
  - b. Fissure.
  - c. Meatus.
  - d. Fossa.

19. What structure holds one bone to another, forming the capsule of a movable joint?
- a. Ligament.
  - b. Articular cartilage.
  - c. Articular disc.
  - d. Synovial membrane.
20. An example of a ginglymus or hinge joint is the:
- a. Hip.
  - b. Elbow.
  - c. Shoulder.
  - d. Wrist.
21. A freely movable joint belongs in which of these classes?
- a. Amphiarthrodial.
  - b. Diarthrodial.
  - c. Synarthrodial.
  - d. Biarthrodial.
22. The chief function of synovial fluid is to:
- a. Line joint capsules.
  - b. Act as cushions between bones.
  - c. Produce hyaline cartilage.
  - d. Lubricate the joint.

23. The heart is located \_\_\_\_\_ to the sternum.
- a. Superior.
  - b. Posterior.
  - c. Anterior.
  - d. Interior.
24. What angular movement is used when a body part is moved away from the median plane?
- a. Abduction.
  - b. Flexion.
  - c. Extension.
  - d. Adduction.
25. In supination of the hand, the palm is turned in what direction?
- a. From posterior to anterior.
  - b. From flexion to extension.
  - c. From anterior to posterior.
  - d. From extension to flexion.
26. The bones of the skull, the vertebral column, the thoracic cage, the auditory ossicles, and the hyoid bone make up the:
- a. Appendicular skeleton.
  - b. Axial skeleton.
  - c. Cancellous bone.
  - d. Compact bone.

**Check Your Answers on Next Page**

## **SOLUTION TO EXERCISES: LESSON 1**

1. d (para 1-1c)
2. a (para 1-2a(4)(b))
3. d (para 1-2a(7))
4. a (para 1-2c(1))
5. b (para 1-2c(9); figure 1-3A)
6. c (para 1-2e(2); figure 1-4)
7. a (para 1-2f(2))
8. d (para 1-2i(2))
9. a (para 1-8a)
10. c (para 1-8d)
11. d (para 1-9a)
12. a (para 1-10d)
13. d. (paras 1-10a, d)
14. a (para 1-10d)
15. d (para 1-10e)
16. c (para 1-11h(8))
17. c (para 1-11h(12))
18. a (para 1-11j(2))
19. a (para 1-13a(3))
20. b (para 1-13a(3))

- 21. b (para 1-13a(3))
- 22. d (para 1-13a(3))
- 23. c (para 1-2c, figure 1-1)
- 24. a (para 1-13b(2)(b))
- 25. a (para 1-13b(2)(h))
- 26. b (para 1-7b)

**End of Lesson 1**

## **LESSON ASSIGNMENT**

### **LESSON 2**

Regional Osteology

### **TEXT ASSIGNMENT**

Paragraph 2-1 through 2-34.

### **LESSON OBJECTIVES**

After completing this lesson, you should be able to:

- 2-1. Select correct answers to questions about the morphology and articulations of the bones of the skeleton, some of the landmarks and palpation points used in radiology, and some of the bone areas that are more susceptible to fracture.

### **SUGGESTION**

After completing the assignment, complete the exercises at the end of this lesson. These exercises will help you to achieve the lesson objectives.

## LESSON 2

### REGIONAL OSTEOLOGY

#### Section I. UPPER EXTREMITY

##### 2-1. THE HAND

The skeleton of the hand (figure 2-1) is divided into three-parts: the carpus, the metacarpus, and the phalanges digits.

a. The carpus, or wrist, consists of eight carpal bones arranged in two rows. Those in the proximal row from the lateral to the medial side of the hand are the navicular or scaphoid, lunate, triangular or triquetrum, and pisiform.

b. The carpals in the distal row are, from lateral to medial, the greater multangular or trapezium, the lesser multangular or trapezoid, capitate, and hamate.

c. The metacarpus is the bony structure of the hand. It consists of five cylindrical bones (metacarpals) that articulate proximally with the distal carpals and distally with the proximal phalanges. The metacarpals are numbered from one to five, from the thumb to the little finger.

d. The phalanges are the bones of the thumb and fingers. Each hand has 14 phalanges, three in each finger and two in the thumb. In the fingers, the proximal phalanges articulate proximally with the metacarpals and distally with the middle row of phalanges. The middle row articulates proximally with the proximal phalanges and distally with the distal phalanges. The distal end of each distal phalanx is flattened and expanded to present the unguis tuberosity for the support of the fingernail. In the thumb, the proximal phalanx articulates proximally with the first metacarpal and distally with the distal phalanx. Bennett's fracture is a longitudinal fracture of the first metacarpal bone running into the carpometacarpal joint, complicated by subluxation (stave of the thumb).

##### 2-2. THE FOREARM

The bones of the forearm (figure 2-2) are the ulna and radius. Both are long bones that articulate with each other at their proximal and distal ends.



# LEFT HAND

—Viewed from the back DORSAL SURFACE—

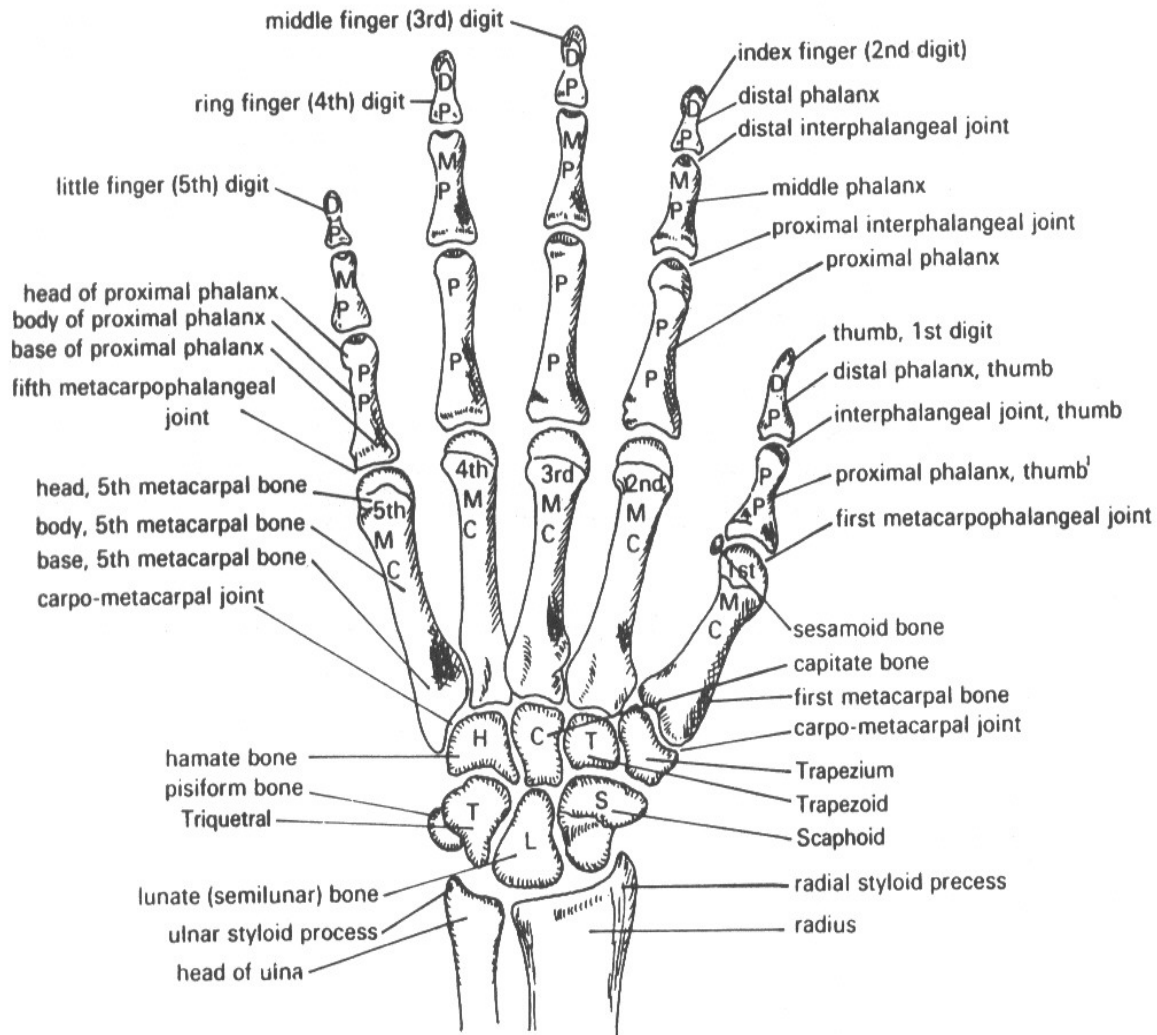


Figure 2-1. The left hand (dorsal aspect).

POSTEROLATERAL ASPECT

ANTEROMEDIAL ASPECT

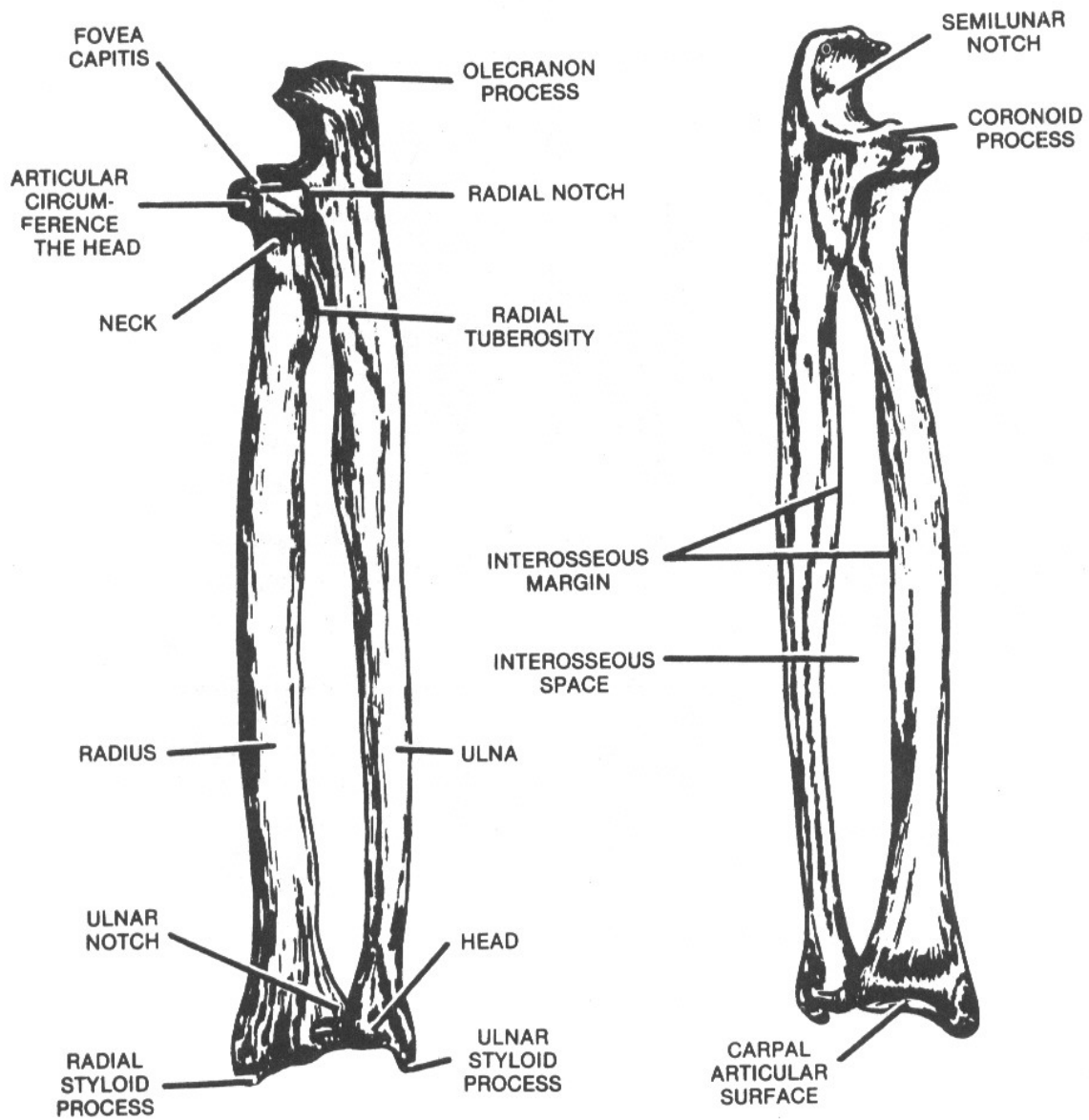


Figure 2-2. The left radius and ulna (posterolateral and anteromedial aspects)

a. The ulna, located on the medial side of the forearm, is the longer of the two bones. Its proximal end, which forms most of the elbow joint (figure 2-3), is thick and strong. It has two processes and two notches. Between its olecranon and coronoid processes lies the trochlear notch (semilunar notch), which accommodates the trochlea of the humerus. The radial notch, on the lateral side of the coronoid process, permits articulation with the radius. The distal end is much smaller than the proximal end, bearing a head and a styloid process. Laterally, the head articulates with the ulnar notch of the radius distally with the articular disk separating it from the wrist joint.

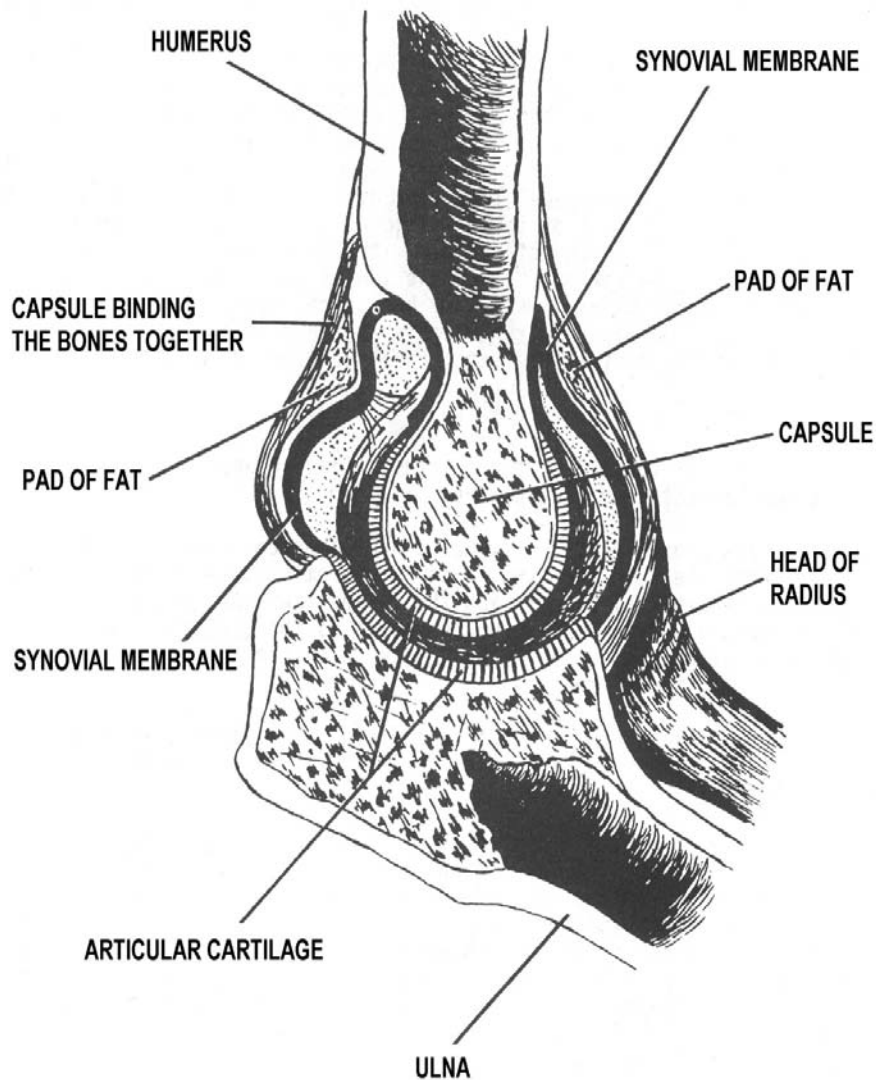


Figure 2-3. The elbow joint.

b. The radius is located on the lateral side of the forearm parallel to the ulna. The proximal end is small and has a head, neck, and tuberosity. The shallow cup, or fovea, on the proximal surface of the head articulates with the capitulum of the humerus. On the broad medial surface, the head articulates with the radial notch of the ulna. Below the neck on the medial side is the radial tuberosity (or tubercle). The distal end is large and club-shaped and forms the largest part of the wrist joint. It has two articular surfaces, one broad area that articulates with two carpal bones (the navicular and lunate) and a smaller surface on the medial side, the ulnar notch, that articulates with the ulna. Distally, the lateral surface extends into the styloid process. Colles fracture occurs at the distal radius with posterior displacement of the distal fragments, a "silver fork deformity."

### **2-3. THE ARM**

The bone of the arm is the humerus (figures 2-4 and 2-5). It is the longest and largest bone of the upper limb.

a. Its proximal extremity has a hemispherical head. The anatomical neck separates the head from two large bony prominences. The greater tubercle, situated on the lateral aspect, and the lesser tubercle, situated on the anterior surface. Between the two tubercles is the bicipital, or intertubercular groove. The surgical neck below the tuberosity is frequently the site of fractures.

b. Proximally, the shaft is almost cylindrical, but it becomes flat distally. Approximately in the middle lateral third of the shaft is the deltoid tuberosity.

c. The broad distal extremity consists laterally of the capitulum and medially of the trochlea. The capitulum articulates with the fovea on the head of the radius and the trochlea with the trochlear notch on the ulna. Proximal to these two eminences on the anterior aspect are the radial and the coronoid fossa (which receive the head of the radius) and the coronoid process of the ulna, respectively, when the forearm is flexed. Posterior to the trochlea is the olecranon fossa, which receives the olecranon process of the ulna when the forearm is extended. On the sides of the distal end are two prominences, the lateral and medial epicondyles.

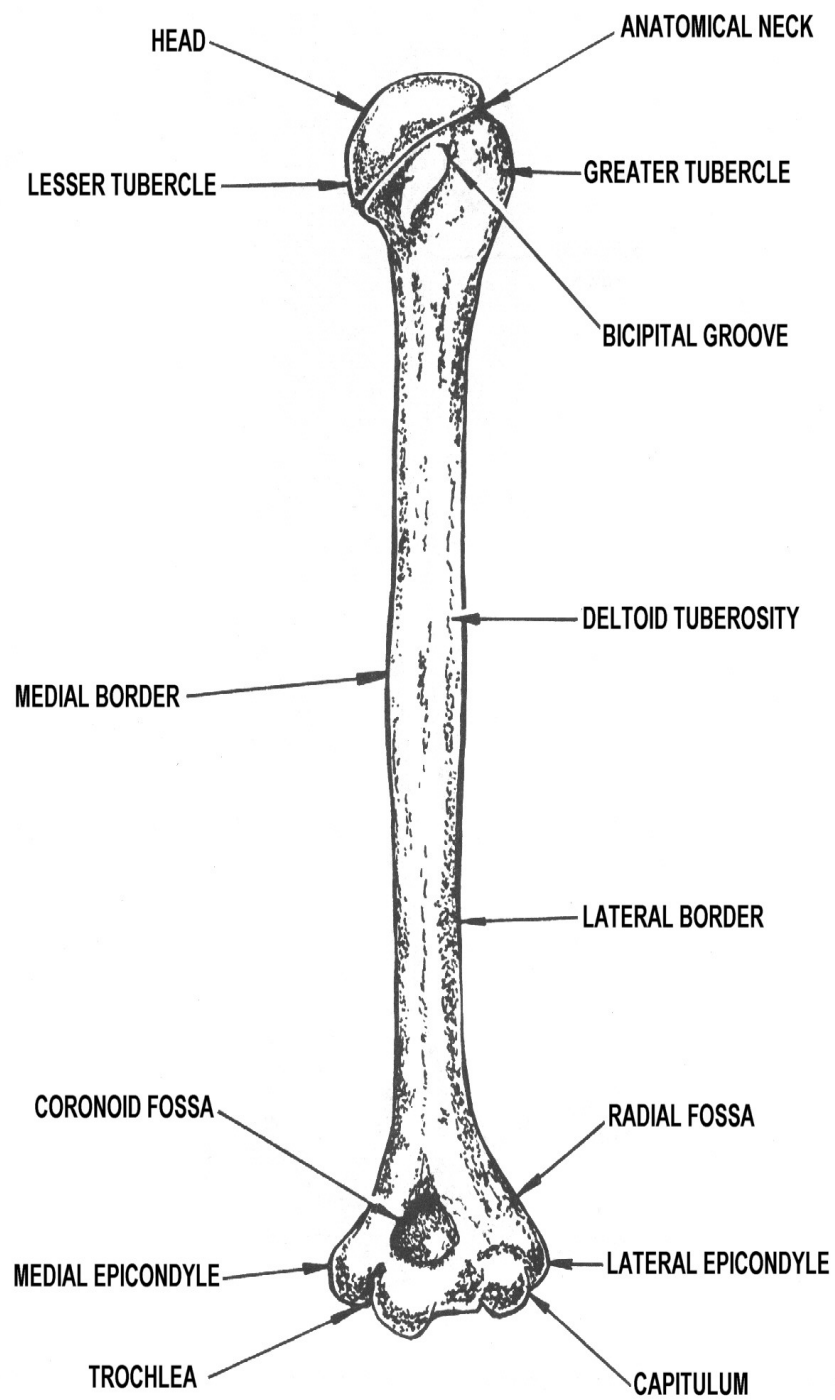


Figure 2-4. The left humerus (ventral aspect showing anterior surface).

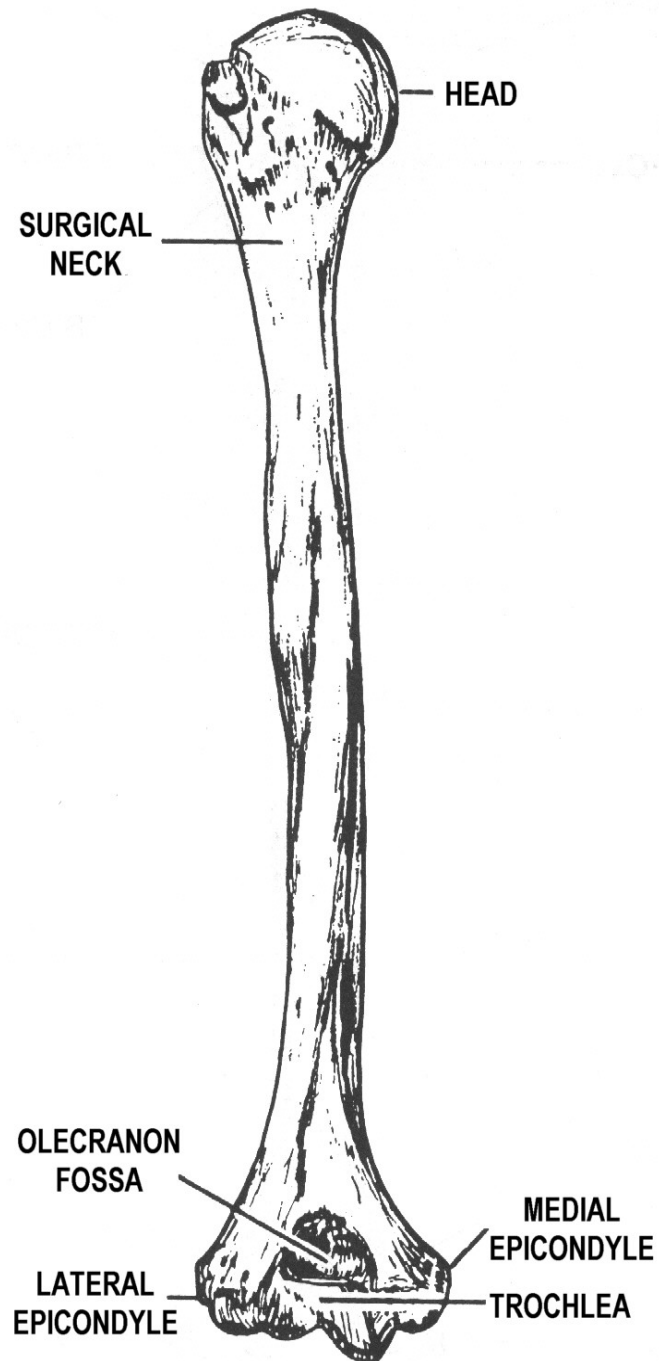


Figure 2-5. The left humerus (dorsal aspect showing posterior surface).

## 2-4. THE SHOULDER GIRDLE

a. **General.** The shoulder girdle attaches the free upper extremity (arm) to the trunk. The scapula has no direct or indirect connection with its counterpart of the opposite side. It is only indirectly attached to the trunk by means of the clavicle that closes the girdle ventrally (in front). The girdle remains open dorsally (in back) and is freely movable.

**NOTE:** The terms "tubercle" and "tuberosity" are used interchangeably.

### b. The Scapula.

(1) The scapula, or shoulder blade (figure 2-6), is a large, flat, triangular-shaped bone with several marked processes. It is situated on the dorsal aspect of the thorax and is attached by muscles only. It lies between the levels of the second and seventh ribs with its vertebral border about two inches lateral to the vertebral column. In thin subjects, it can be easily palpated. It has two surfaces, three borders, and three angles which can be recognized.

(2) The anterior surface of the scapula is directed toward the ribs and is comparatively smooth. It is marked by a concave and somewhat shallow depression, termed the subscapular fossa. The posterior surface is slightly convex and is divided into two unequal areas by a narrow ridge or crest of bone called the spine. The spine of the scapula terminates laterally in a large triangular projection, the acromion process, which forms the tip of the shoulder and can be felt through the skin. The portion of the posterior surface above the spine is called the supraspinous fossa; and below it, the infraspinous fossa.

(3) The three borders are designated as the vertebral, the axillary, and the superior. The vertebral border is approximately parallel to the vertebral column. The upper (superior) border is the shortest and is thin and sharp. At its lateral end, there is a depression, the scapular notch, and a thick beaklike projection, the coracoid process. The coracoid process curls forward beneath the clavicle and can be palpated in a depression on the thorax (the infraclavicular fossa). Frequently, in thin subjects, it may form a rather prominent projection. The axillary border is the thickest and lies close to the armpit, or axilla.

(4) The three angles are designated medial, inferior, and lateral.

(a) The medial angle is formed by the junction of the superior and vertebral borders.

(b) The inferior angle is formed by the union of the vertebral and axillary borders.

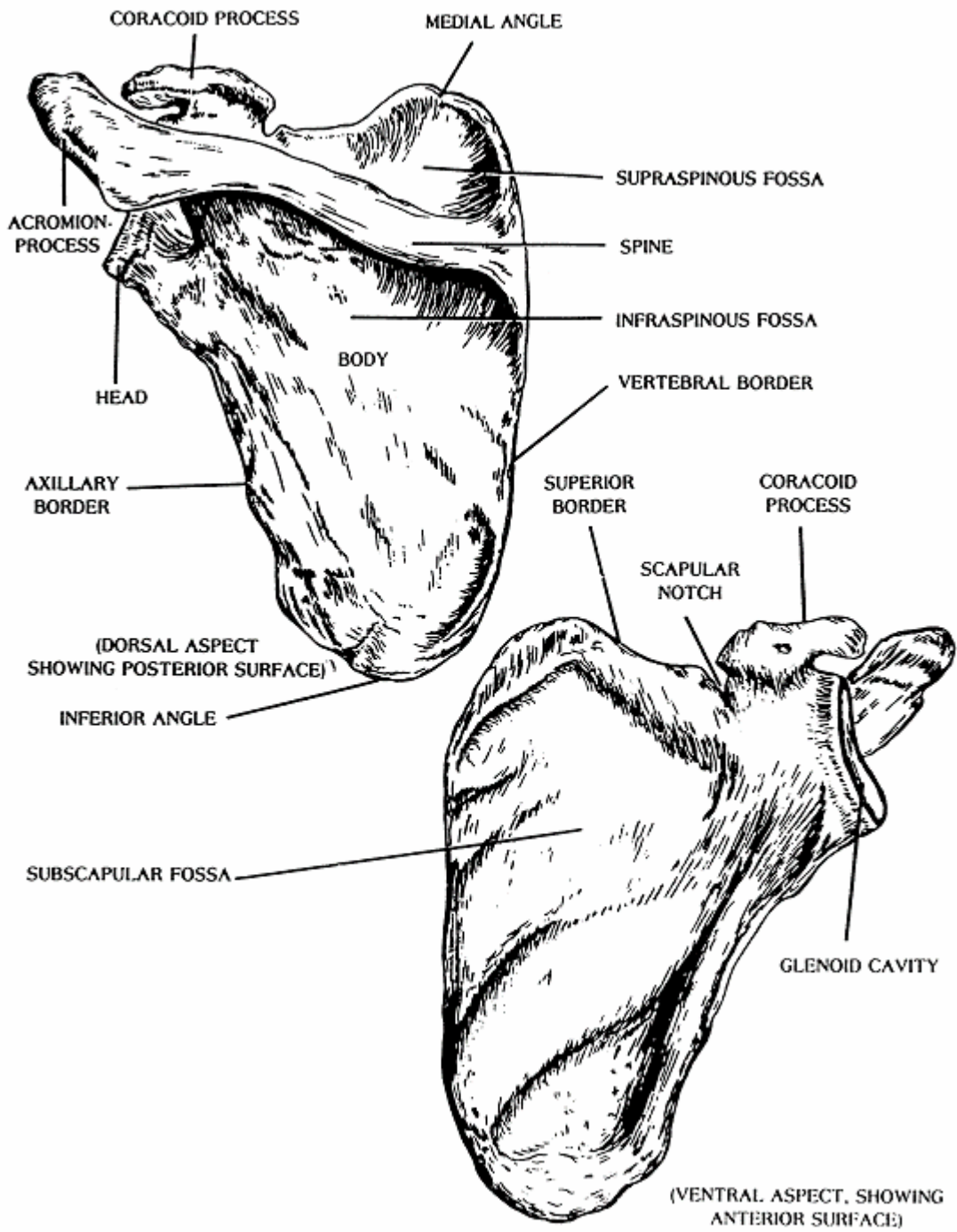


Figure 2-6. The left scapula (ventral and dorsal aspects).



(c) The lateral angle, formed by the junction of the superior and axillary borders, is the thickest part of the bone and is sometimes called the head of the scapula. The head presents a smooth, slightly depressed, articular surface, the glenoid fossa or cavity, which accommodates the head of the humerus. The glenoid lip is a fibrocartilaginous rim attached around the margin of the glenoid cavity. The head is separated from the main portion (body) of the bone by a thickened, slightly constricted part, called the neck.

c. **The Clavicle.** The clavicle or collarbone (figure 2-7) is a long, slender S-shaped bone with a middle portion, the shaft or body, and two extremities. The sternal extremity is rounded. The acromial extremity is flat. The shaft, or body, has two surfaces, a superior and an inferior, separated by anterior and posterior borders. The medial two-thirds of the anterior border presents a convexity and the lateral one-third presents a concavity. The superior surface is comparatively smooth and can be easily palpated. Near its sternal end, a broad, roughened area called the costal tuberosity marks the inferior surface. Laterally, near the posterior border is a well-marked roughened eminence, the coronoid tubercle.

## 2-5. ARTICULATIONS OF THE HAND

a. **Sternoclavicular.** The sternoclavicular joint works with a sliding movement. It represents the articulation of the clavicle with the clavicular notch of the sternum and with the cartilage of the first rib. An articular disk of fibrocartilage is interposed between the clavicle and the sternum.

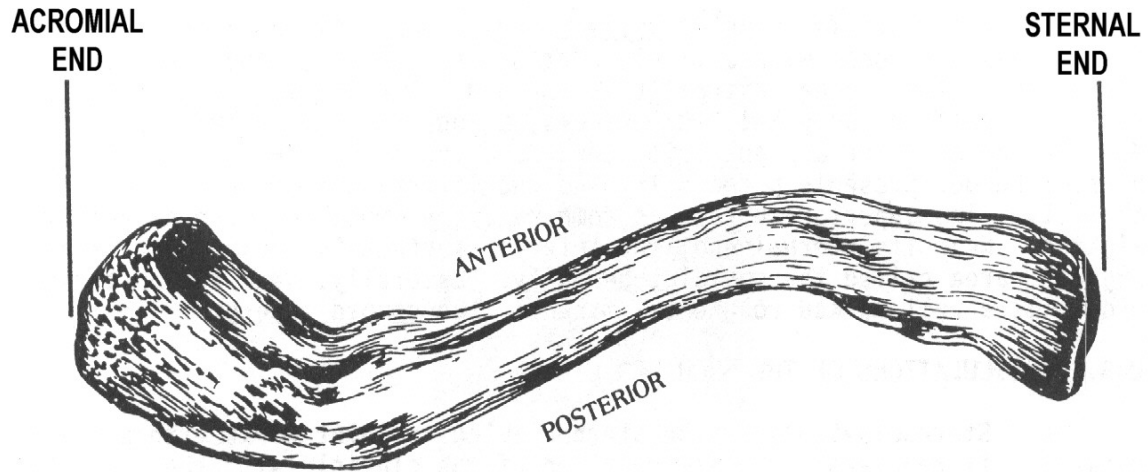
b. **Acromioclavicular.** The acromioclavicular joint also glides. It is the articulation between the acromial end of the clavicle and the medial edge of the acromion process of the scapula.

c. **Movements of the Shoulder Girdle.** The movements of the clavicle at the sternoclavicular joint are those of elevation, depression, protraction (forward), retraction (backward), and circumduction. The scapula at the acromioclavicular joint moves in a gliding manner.

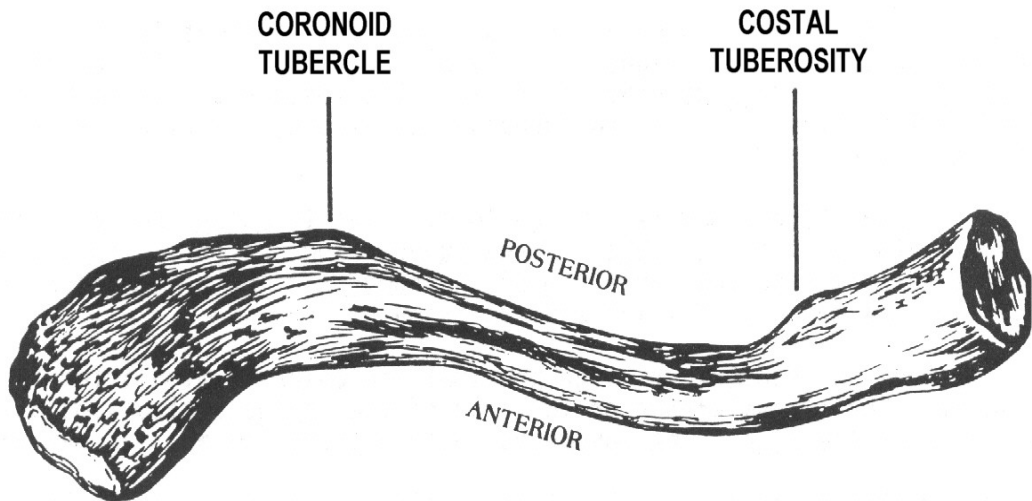
## 2-6. ARTICULATIONS OF THE UPPER FREE EXTREMITY

a. **Shoulder.** The shoulder is a ball-and-socket joint between the head of the humerus and the glenoid cavity of the scapula. A fibrocartilaginous lip (glenoid labrum) deepens the fossa. The movements allowed by the shoulder include flexion (swinging forward), extension, abduction, adduction, and circumduction.

b. **Elbow.** The elbow is a hinge joint. The trochlear notch of the ulna articulates with the trochlea of the humerus and the fovea capitis of the radius articulates with the capitulum of the humerus. The movements permitted by the elbow are those of flexion and extension.



(SUPERIOR ASPECT)



(INFERIOR ASPECT)

Figure 2-7. The left clavicle (superior and inferior aspects).

c. **Proximal Radioulnar.** The proximal radioulnar articulation is a pivot joint. The circumference of the head of the radius articulates with the radial notch of the ulna. The movements include pronation and supination.

d. **Distal Radioulnar.** The distal radioulnar articulation is a pivot joint between the head of the ulna and the ulnar notch of the radius. The movements of the distal radioulnar joint are pronation and supination.

e. **Wrist.** The wrist is a condyloid joint. The scaphoid and lunate fossae on the distal end of the radius articulate with the scaphoid lunate bones. The movements allowed by the wrist are flexion, extension, hyperextension, abduction, adduction, and circumduction.

## 2-7. ARTICULATIONS OF THE HAND

a. **Intercarpal.** These are gliding joints between the individual carpal bones. Very limited gliding movement is permitted at these joints.

b. **Carpometacarpal.** The bases of the metacarpals are attached to the distal row of carpals. The trapezium, attached to the first metacarpal, is a special joint (saddle) which gives man an opposable thumb. The movements allowed by this joint are flexion, extension, abduction, adduction, and circumduction. The joints between the carpus and the second, third, fourth, and fifth metacarpal bones are gliding, and their movements are limited to slight flexion and extension.

c. **Intermetacarpal.** The bases of the second, third, fourth, and fifth metacarpal bones are connected with one another. The intermetacarpal joints permit only a slight gliding movement.

d. **Metacarpophalangeal.** The heads of the metacarpals are articulate with the proximal row of phalanges. They are condyloid joints. The movements allowed are flexion, extension, abduction, adduction, and circumduction.

e. **Interphalangeal.** The joints between the phalanges are called interphalangeal. They are hinge-type joints. The movements of the phalanges are flexion and extension.

## 2-8. PALPATION POINTS OF THE UPPER EXTREMITY

Palpation points of the upper extremity are shown in figures 2-8, 2-9, and 2-10. Be sure to study these carefully.

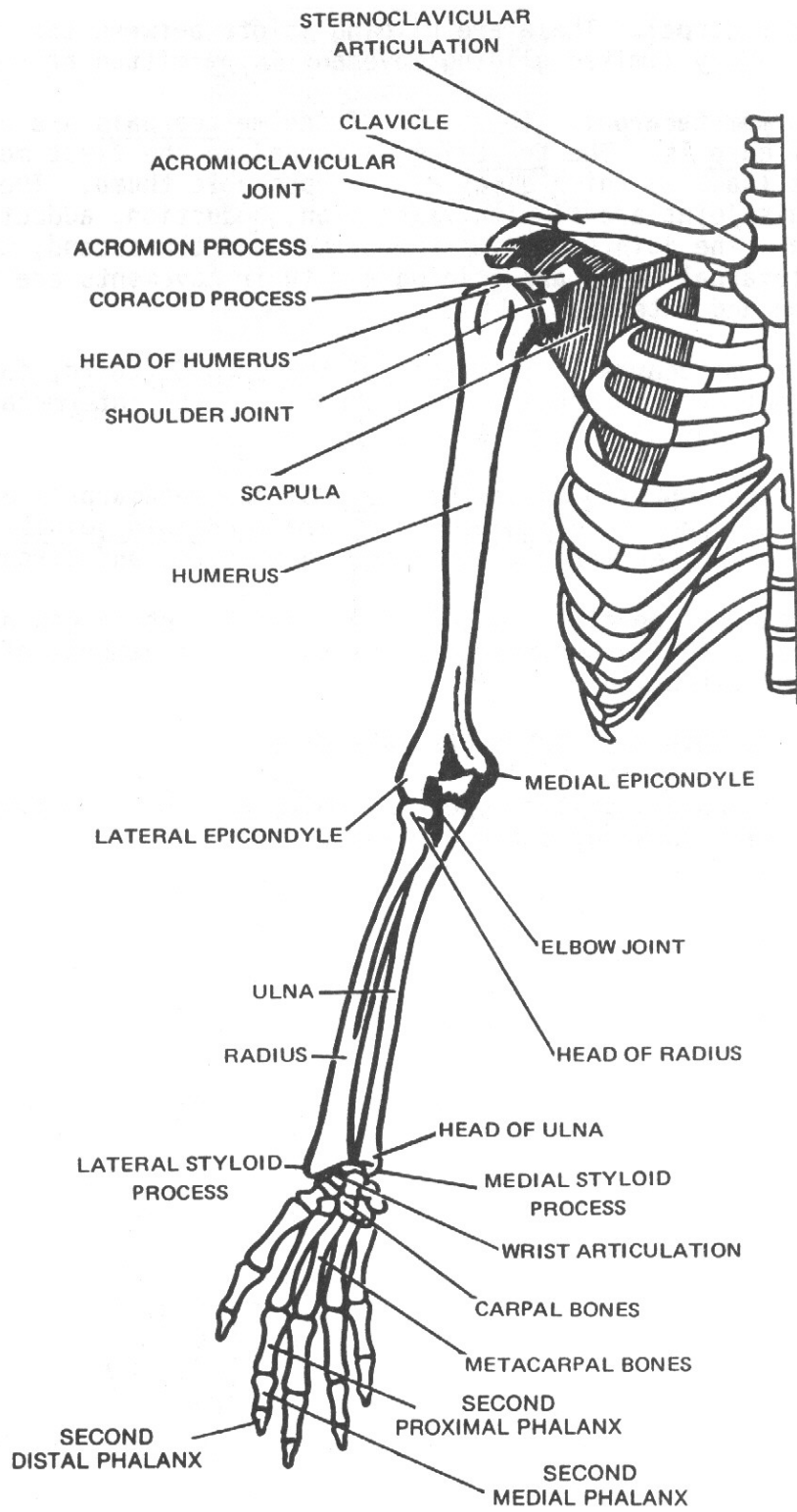


Figure 2-8. Skeletal landmarks and palpation points of the upper extremity.

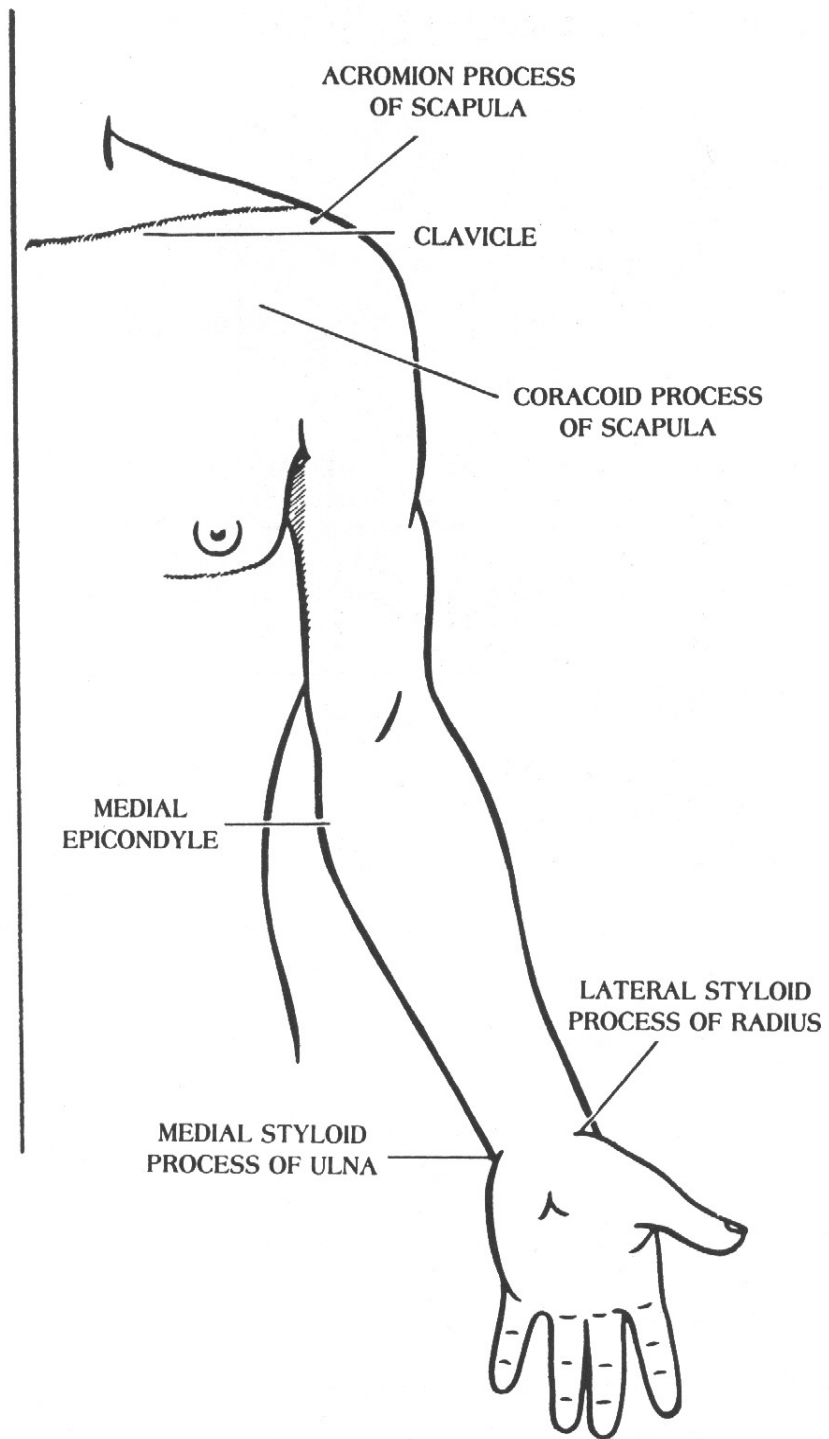
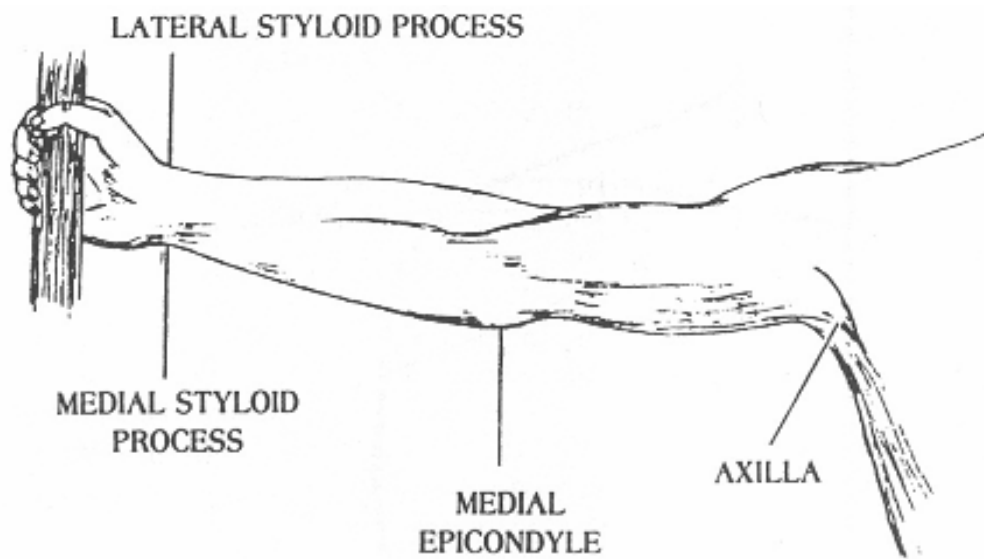
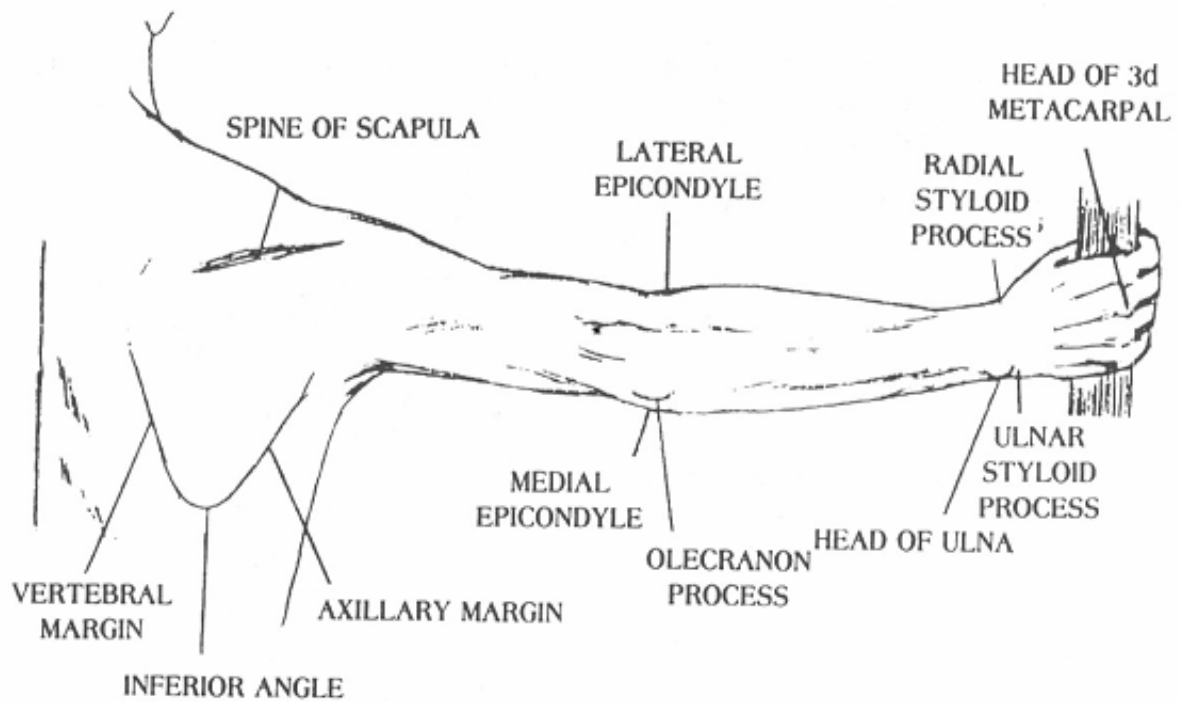


Figure 2-9. External landmarks and palpation points of the upper extremity.



A. Anterior view of the upper extremity.



B. Posterior view of the upper extremity.

Figure 2-10. Anterior and posterior views of the upper extremity.

## Section II. LOWER EXTREMITY

### 2-9. GENERAL

The bones of the lower extremity may be divided into four groups:

a. **The Pelvic Girdle.** The pelvic girdle is composed of the two os coxae (hip bones), the sacrum, and the coccyx. The sacrum and coccyx are also considered as part of the vertebral column.

b. **The Thigh.** The bone of the thigh is the femur, a long bone extending between the hip and the knee. The patella, or kneecap, is included here for convenience.

c. **The Leg.** The leg extends from the knee to the ankle and consists of the tibia, or shin bone (medial portion), and the fibula, or calf bone (lateral portion).

d. **The Foot.** The foot may be divided into three groups of bones: the tarsus (seven tarsal bones); the metatarsus or foot proper (five metatarsal bones); and the digits or toes (14 phalanges).

### 2-10. THE FOOT (figure 2-11)

a. **The Tarsus.** The tarsus is composed of seven bones, referred to collectively as the tarsal bones. The tarsal bones may be divided into two-groups: the proximal region consisting of the calcaneus, the talus, and the navicular; and a distal row (named from medial to lateral) consisting of the first, second, and third cuneiform bones and the cuboid.

(1) The calcaneus (os calcis) or heel bone is the largest of the tarsal bones. Its large posterior end forms the heel, and is marked by an expanded portion, the calcaneal tuberosity.

(2) The talus (astragalus) is the second largest of the tarsal bones. It consists of a body, a head, and a neck. The superior aspect of the body presents an articular surface, called the trochlea. The head is the rounded anterior end which is received into the posterior concavity of the navicular bone.

(3) The navicular bone is somewhat boat-shaped. It is situated on the medial side of the foot between the talus posteriorly and the cuneiform bones anteriorly. Posteriorly, it presents an oval, concave surface for articulation with the rounded head of the talus.

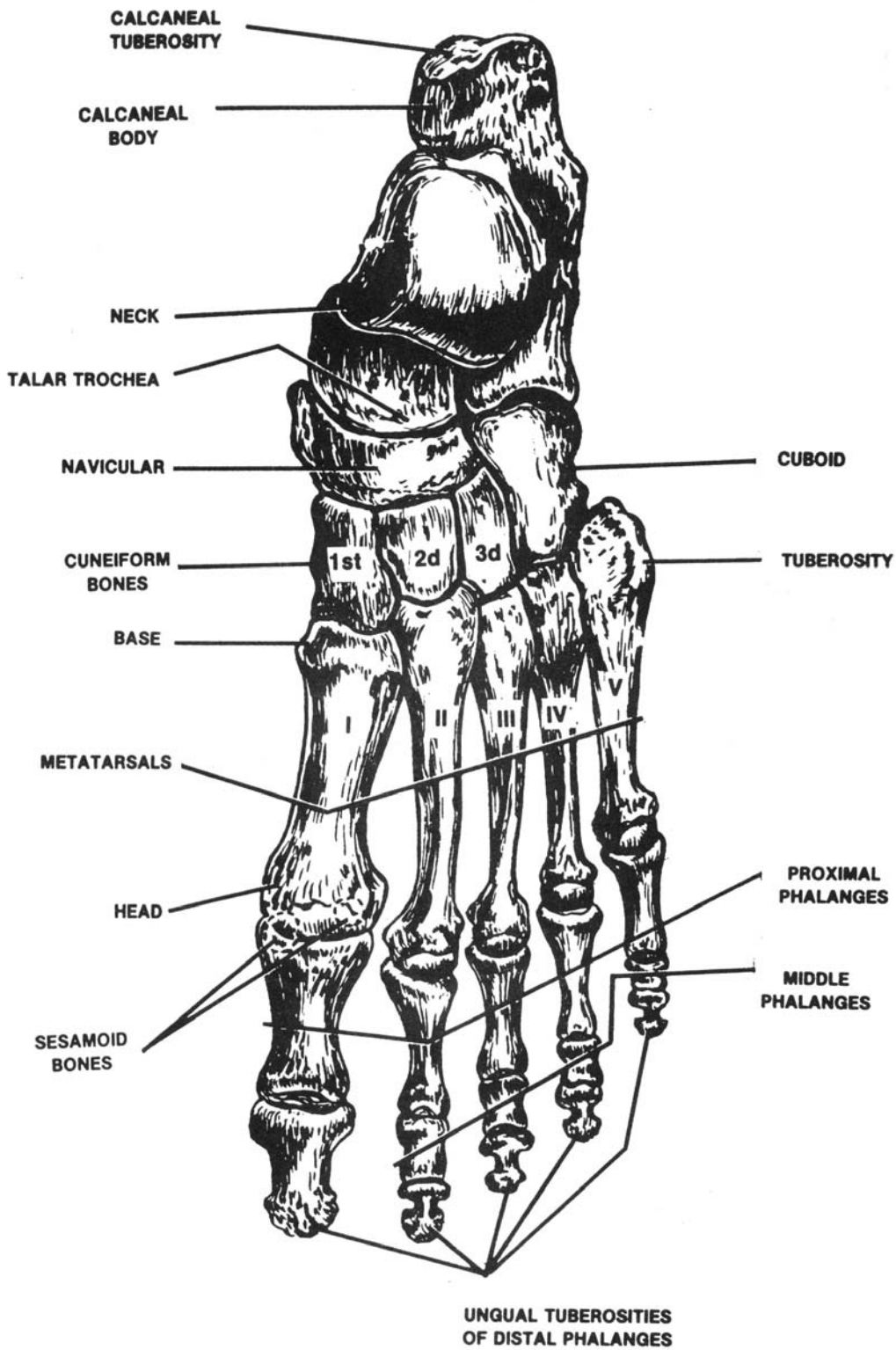


Figure 2-11. Left foot (dorsal surface).



(4) The cuboid bone is a cube-shaped bone. It is situated on the lateral side of the foot in front of the calcaneus and behind the fourth and fifth metatarsal bones.

(5) The cuneiform bones are placed at the anterior portion of the tarsus lying side by side between the navicular bone and the bases of the first three metatarsals. The first cuneiform bone is the largest. The smaller second cuneiform bone is placed with its base (broad end) directed superiorly and its apex (thin end) directed downwards. The third cuneiform bone is the second largest. Like the second cuneiform, its base is directed superiorly and its apex inferiorly.

b. **The Metatarsus.** The foot proper is formed by the metatarsus. The metatarsal bones are numbered one through five, from the medial to the lateral side. Each metatarsal bone consists of a shaft, or body, and two extremities. The base or proximal extremity is wedge-shaped and the head, or distal extremity, is rounded. The first metatarsal, which provides attachment for the great toe, is the strongest and shortest of the metatarsal bones. It serves as the main support of the body when in the walking position. The large rounded head that forms the "ball of the foot" presents two grooves on its inferior, or plantar surface, on which glide two sesamoid bones in the tendon of the flexor hallucis brevis muscle. The heads of the second and third metatarsals generally extend beyond the first.

c. **The Digits.** The digits, or toes, are composed of 14 phalanges. There are two phalanges in the great toe and three in each of the other toes (the proximal, the middle, and the distal). Each phalanx consists of a shaft and two extremities. The proximal extremity of each proximal phalanx presents a concave facet for articulation with the head of the corresponding metatarsal. The distal end presents a trochlear articular surface for articulation with the middle phalanx. The distal end of each distal phalanx is flattened and presents the unguis tuberosity for the support of the toenail.

d. **The Foot As a Whole.** The bones of the foot are so arranged and adapted to each other that they form two distinct arches, the longitudinal arch and the transverse arch. These arches form a firm basis of support for the human body in the standing position, give elasticity to the step, and accommodate the plantar blood vessels, nerves, tendons, and muscles. Abnormally high arches are called pes cavus. The longitudinal arch is the principal one and can be seen when the foot is viewed from the medial, or inner side. It consists of an anterior pillar formed by the heads of the metatarsals, a posterior pillar formed by the calcaneus, and a keystone formed by the talus. The three cuneiform bones and the cuboid (with the proximal ends of the metatarsal bones) form the transverse arch. The "top" of the foot is referred to as the dorsal aspect, the "bottom" as the plantar aspect. The term "march fracture" is defined as a fracture of the distal portion of the second and third metatarsals without a history of trauma.

## 2-11. THE LEG

a. **General.** Anatomically, the word leg is reserved for that portion of the lower extremity (limb) between the knee and the ankle. The leg (figure 2-12) has two bones, the tibia and the fibula).

b. **The Tibia.** The tibia, or shinbone, is situated in the medial portion of the leg. It is a long bone consisting of a shaft and two extremities.

(1) The superior extremity is expanded into the medial and lateral condyles. Between the condyles is a projection called the intercondylar eminence. Inferior to the condyles on the anterior aspect of the upper tibia is a roughened prominence called the tibial tuberosity. The fibular facet is situated on the posteroinferior aspect of the lateral condyle. The shaft, or body, is somewhat triangular in shape and presents three borders and three surfaces. The anterior border, the most prominent one, is sharp and is called the anterior margin. The interosseous margin, or lateral border, is directed toward the interosseous margin of the fibula and gives attachment to the interosseous membrane connecting the tibia and fibula.

(2) Situated on the distal extremity is a process called the medial malleolus, which forms the prominence on the medial side of the ankle. The fibular notch is a small depression on the lateral border of the distal end of the tibia. The inferior articular surface of the tibia is quadrilateral in shape.

c. **The Fibula.** The fibula, or calf bone, is situated on the lateral side of the leg. It is a long, slender bone consisting of a shaft and two extremities. The proximal extremity is somewhat rounded and is called the head. The fibular styloid process, or apex, projects from the superior surface of the head. The distal end, called the lateral malleolus, forms the prominence on the lateral side of the ankle. A common fracture occurring in the leg is called Pott's fracture. This is a fracture of the distal fibula with frequent involvement of the medial malleolus of the tibia.

## 2-12. THE THIGH

a. **The Femur.** The femur (figure 2-13) is the longest and strongest bone in the body and extends from the hip joint to the knee joint. The femur consists of a shaft and two extremities, superior and inferior.

(1) The superior (proximal) extremity bears a rounded prominence, the head. The head is attached to the shaft by the neck. At the junction of the neck and the shaft of the femur is a roughened prominence called the greater trochanter, which can be felt through the skin. The greater trochanter is the palpation point for the hip joint. Inferior to the greater trochanter and situated on the posterior and medial aspect of the bone is an eminence named the lesser trochanter.

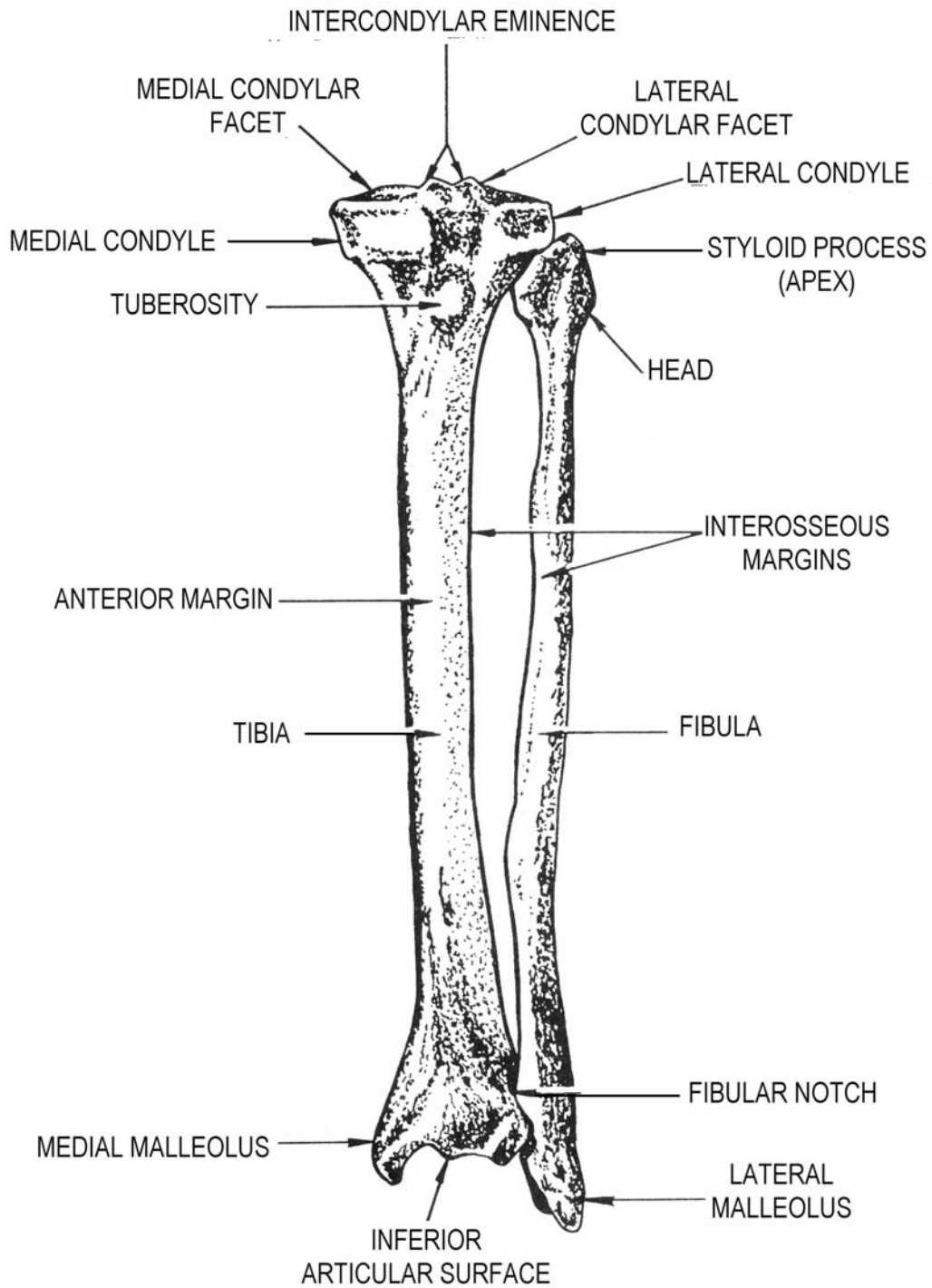


Figure 2-12. Left tibia and fibula (anterior aspect).

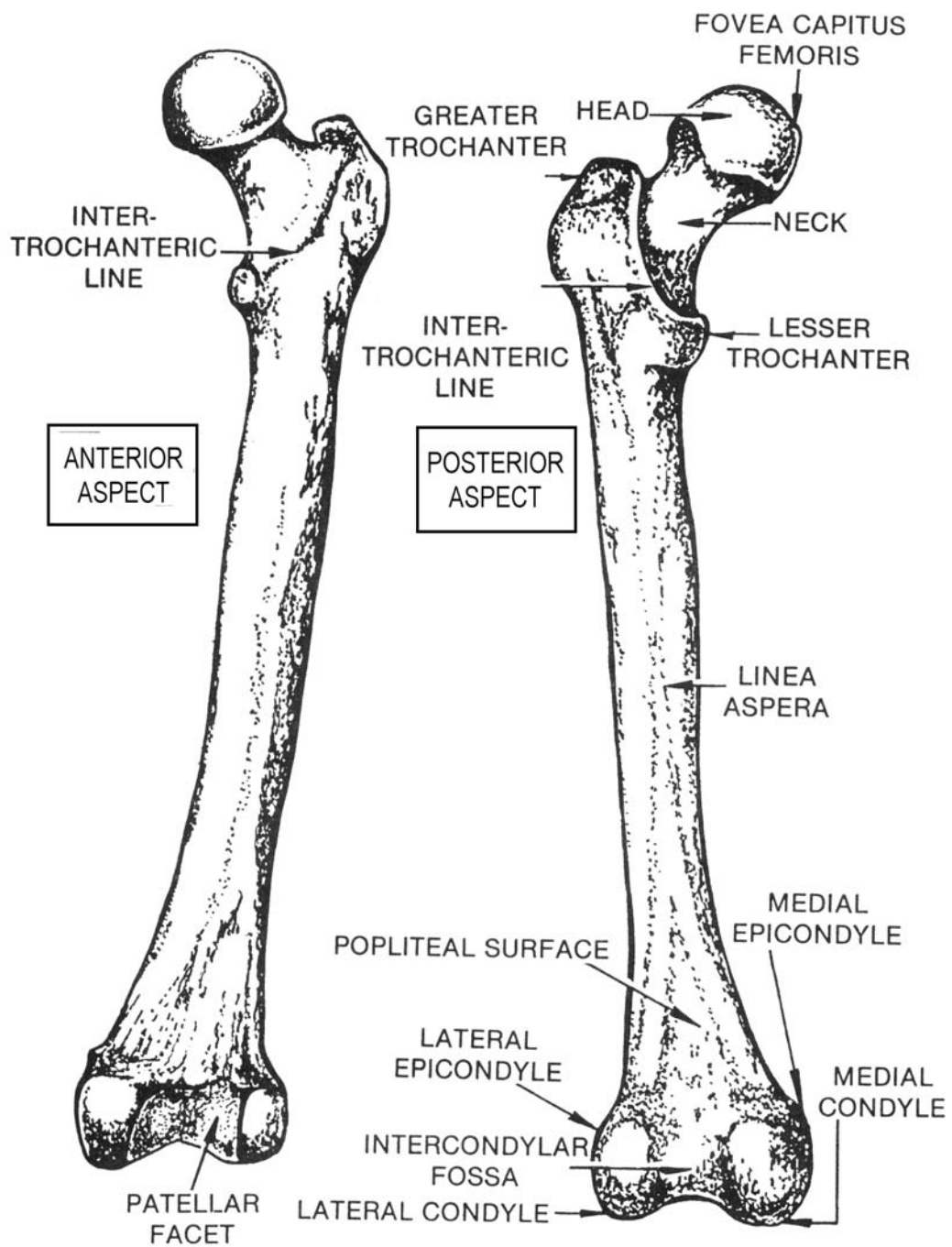


Figure 2-13. Left femur (anterior and posterior aspects).

(2) A prominent longitudinal ridge or crest, the linea aspera, presenting an inner and an outer lip, mark the posterior surface of the shaft. The inferior or lower extremity presents two condyles, the lateral and medial, and the patellar facet. The condyles are separated on the posterior surface by the intercondylar fossa. Each condyle is surmounted by an elevation, the lateral and medial epicondyles. Above the condyles and the intercondylar fossa on the posterior aspect is a triangular area called the popliteal surface.

b. **The Patella.** The patella, or kneecap, is a sesamoid bone developed in the extensor tendon of the knee and is situated on the front of the knee joint. It is somewhat triangular in shape, with its pointed apex directed inferiorly, and its broad base superiorly. The posterior surface presents a smooth, oval, articular surface for articulation with the patellar surface and the condyles of the femur. The anterior surface is convex and rough. The knee joint is shown in figure 1-13.

## 2-13. THE PELVIC GIRDLE OR PELVIS

a. **General.** The pelvic girdle (figure 2-14), or pelvis, is a complete bony girdle made up of the two os coxae bones laterally and in front, and the sacrum and coccyx behind. The two os coxae bones are joined anteriorly at the symphysis pubis. Posteriorly, the iliac portions of the os coxae are joined to the sacrum at the sacroiliac joints. The pelvis is divided by an oblique plane, which passes through the prominence of the sacrum (sacral promontory), the arcuate lines, and the superior plane of the pubic or pubes bones. Above this plane is the greater (false) pelvis, and below is the lesser (true) pelvis. The circumference of this plane is termed the pelvic brim or ring. The interior diameter of the female true pelvis is important in prenatal pelvimetry.

b. **The Os Coxa.** The os coxa consists of three parts: the ilium, ischium, and pubis (figures 2-15 and 2-16). These are three separate, distinct bones in the young subject, but are fused and consolidated in the adult. The bodies of these three portions meet and unite in and around a large cup-shaped socket, the acetabulum (figure 2-16), which is situated near the middle of the lateral surface of the bone. The ilium, or flank bone, is the upper expanded portion of the bone and its body forms the upper two-fifths of the acetabulum. The ischium forms the lower and back part of the bone; its body also contributes about two-fifths to the acetabulum. The pubis forms the anterior and inferior portion of the bone and its body contributes one-fifth to the acetabulum.

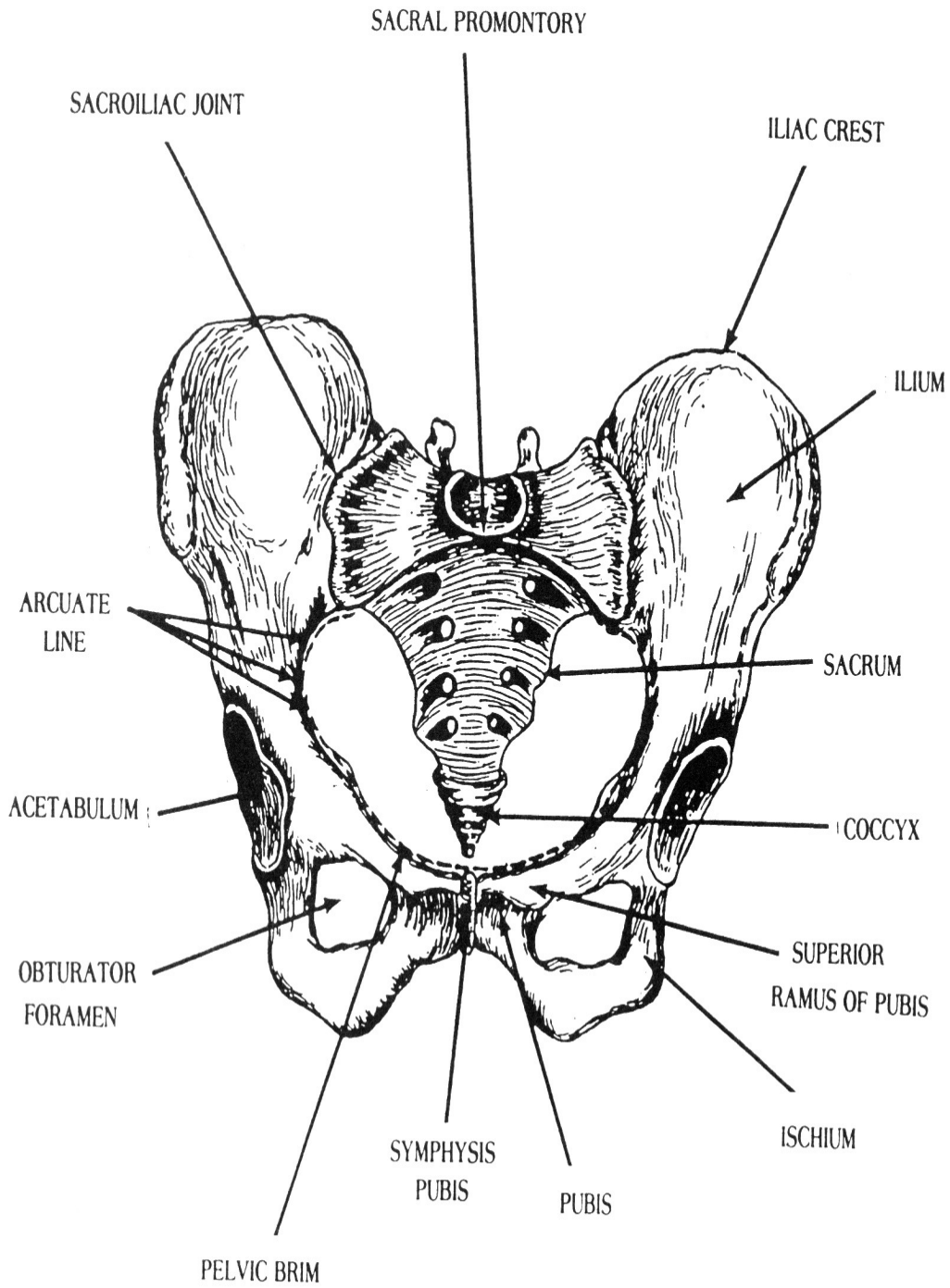


Figure 2-14. The pelvic girdle.

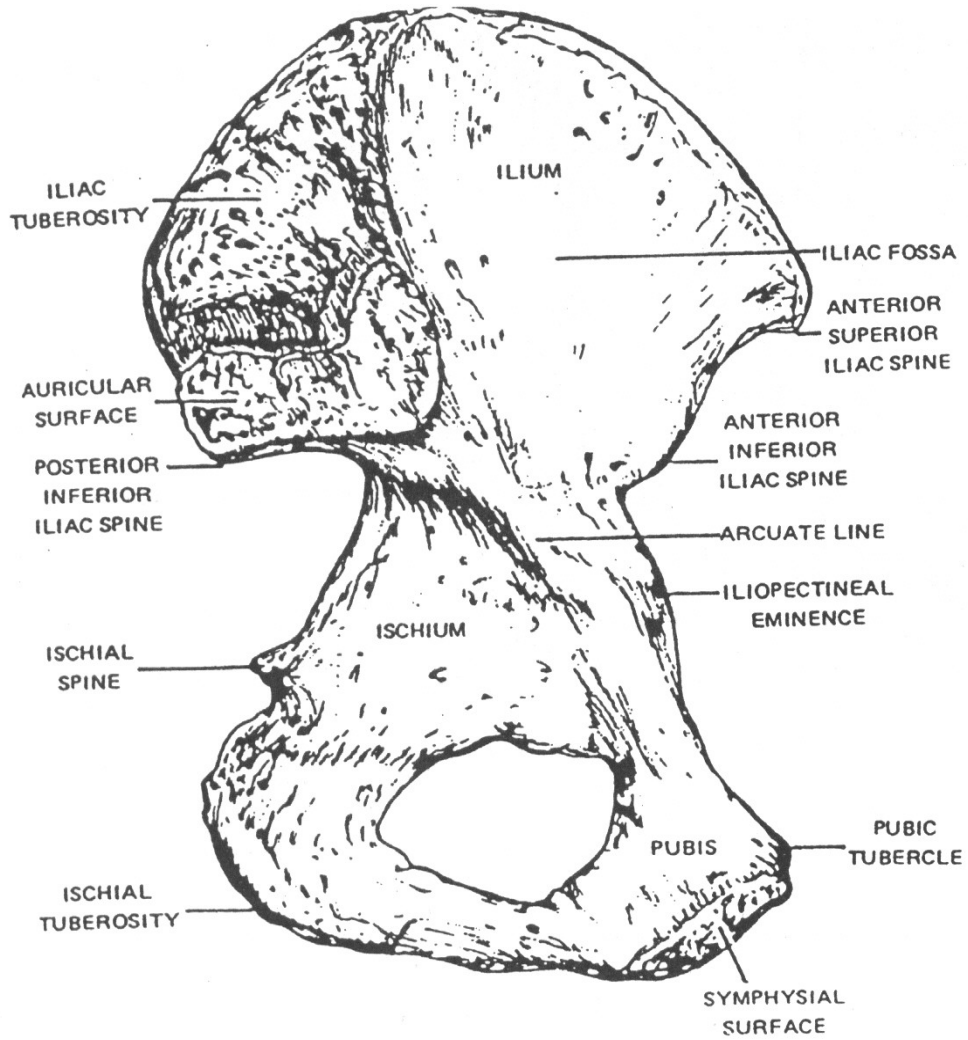


Figure 2-15. Left os coxa bone (medial aspect).

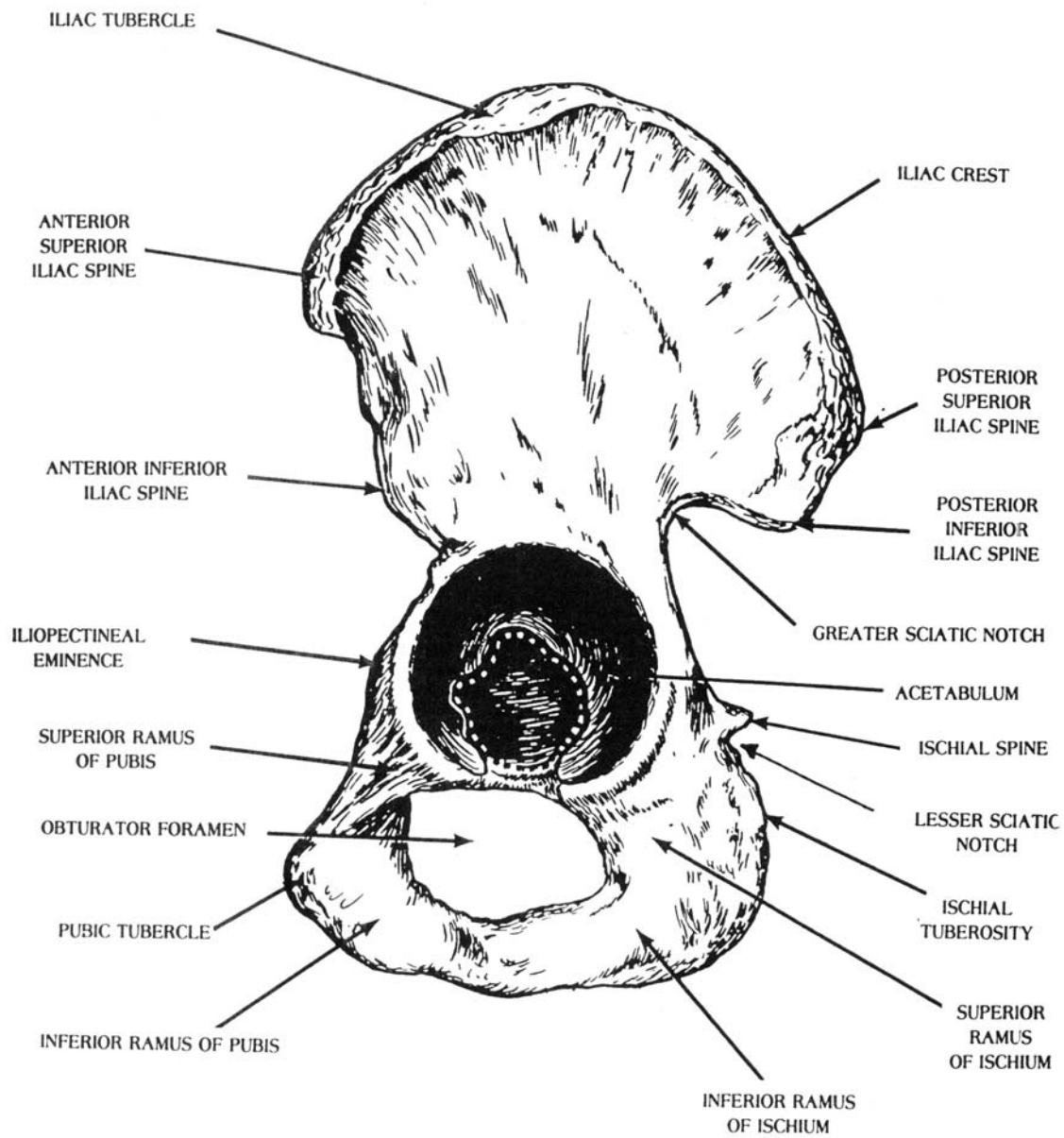


Figure 2-16. Left os coxa bone (lateral aspect).



(1) The ilium is divided into a body and a flared portion called the ala, or wing. The upper border of the ala is called the iliac crest. This crest terminates anteriorly as the anterior superior iliac spine (ASIS), below which is situated the anterior inferior iliac spine (AIIS). The crest of the ilium terminates posteriorly as the posterior superior iliac spine (PSIS), below which is situated the posterior inferior iliac spine (PIIS). The greater sciatic notch is situated below the posterior inferior iliac spine (figure 2-16). The internal or medial surface of the ilium presents a large, smooth, concave depression called the iliac fossa. Behind the iliac fossa is a rough surface divided into two portions. The superior portion is the iliac tuberosity and the inferior portion is the auricular surface. A curved line, the arcuate line, that marks the inferior boundary of the major or false pelvis indicates the inferior boundary of the iliac fossa. The obturator foramen is a large aperture situated between the ischium and the pubis and inferior to the acetabulum.

(2) The ischium is composed of a body, a superior ramus, and an inferior ramus. The ischial spine or sciatic spine projects posteriorly from the body. Situated below the spine is the lesser sciatic notch. The superior ramus branches downward from the body. The ischial tuberosity is situated on the posterior aspect of the superior ramus. The inferior ramus extends from the lower part of the superior ramus to join the inferior ramus of the pubis.

(3) The pubis is divided into a body (which forms part of the acetabulum), a superior ramus, and an inferior ramus. The superior ramus projects anteromedially from the pubic body. The lateral portion of the superior ramus is marked by a rough iliopectineal eminence that indicates the fusion of the ilium and the pubis. The medial portion presents a pubic tubercle, which projects ventrally. The symphyseal surface is the articulating surface by means of which the left pubis and right pubis are joined.

## 2-14. ARTICULATIONS OF THE LOWER EXTREMITY

a. **Sacroiliac.** The union of the auricular surfaces of the sacrum and the ilium forms the sacroiliac joint. It is a slightly movable joint.

b. **Symphysis Pubis.** The junction of the symphyseal surfaces of the pubic bones forms the symphysis pubis. The pubic fibrocartilaginous lamina is interposed between the symphyseal surfaces. This is a slightly movable joint.

c. **Hip.** The hip is formed by the head of the femur articulating with the acetabulum of the os coxa. It is a ball-and-socket joint. The movements permitted by the hip include flexion (swinging forward), extension, abduction, adduction, rotation, and circumduction.

d. **Knee.** The knee may be considered as consisting of three joints in one.

(1) Two condylar articulations are found between the lateral and medial condyles of the femur, articulating with the corresponding articular facets of the condyles of the tibia. This hinge-type joint flexes and extends.

(2) The patellofemoral articulation is between the posterior surface of the patella and the patellar surface of the femur. This joint is best described as gliding.

e. **Superior Tibiofibular.** This is the joint between the lateral condyle of the tibia and the head of the fibula. It is a gliding joint, limited to a slight gliding movement.

f. **Tibiofibular Syndesmosis.** This joint is formed by the junction of the distal end of the fibula and the fibular notch of the tibia. It is a slightly movable joint (synarthrosis).

g. **Ankle Joint.** The ankle joint is between the trochlea of the talus articulating with the ankle mortise. The mortise is the arch-like structure formed by the medial malleolus and inferior articular surface of the tibia and the lateral malleolus of the fibula. The ankle is a hinge joint. The movements permitted are flexion and extension.

h. **Foot.**

(1) Intertarsal. The intertarsal articulations are between the individual tarsal bones. They are gliding joints or condyloid joints.

(2) Tarsometatarsal. The tarsometatarsal articulations are between the bases of the metatarsals and the distal row of the tarsal bones. They are gliding joints.

(3) Intermetatarsal. The intermetatarsal articulations are between adjacent bases of the metatarsals. They are gliding joints.

(4) Metatarsophalangeal. The metatarsophalangeal joints are between the heads of the metatarsals and the bases of the proximal phalanges. They are (condyle-like) condyloid articulations. The movements permitted are flexion and extension.

(5) Interphalangeal. The interphalangeal joints are between the proximal and middle phalanges. They are hinge joints. The movements permitted are flexion and extension.

## 2-15. PALPATION POINTS OF THE PELVIS AND LOWER EXTREMITY

The important landmarks and palpation points of the pelvis and lower extremity are shown in figure 2-17. You should study these with care.

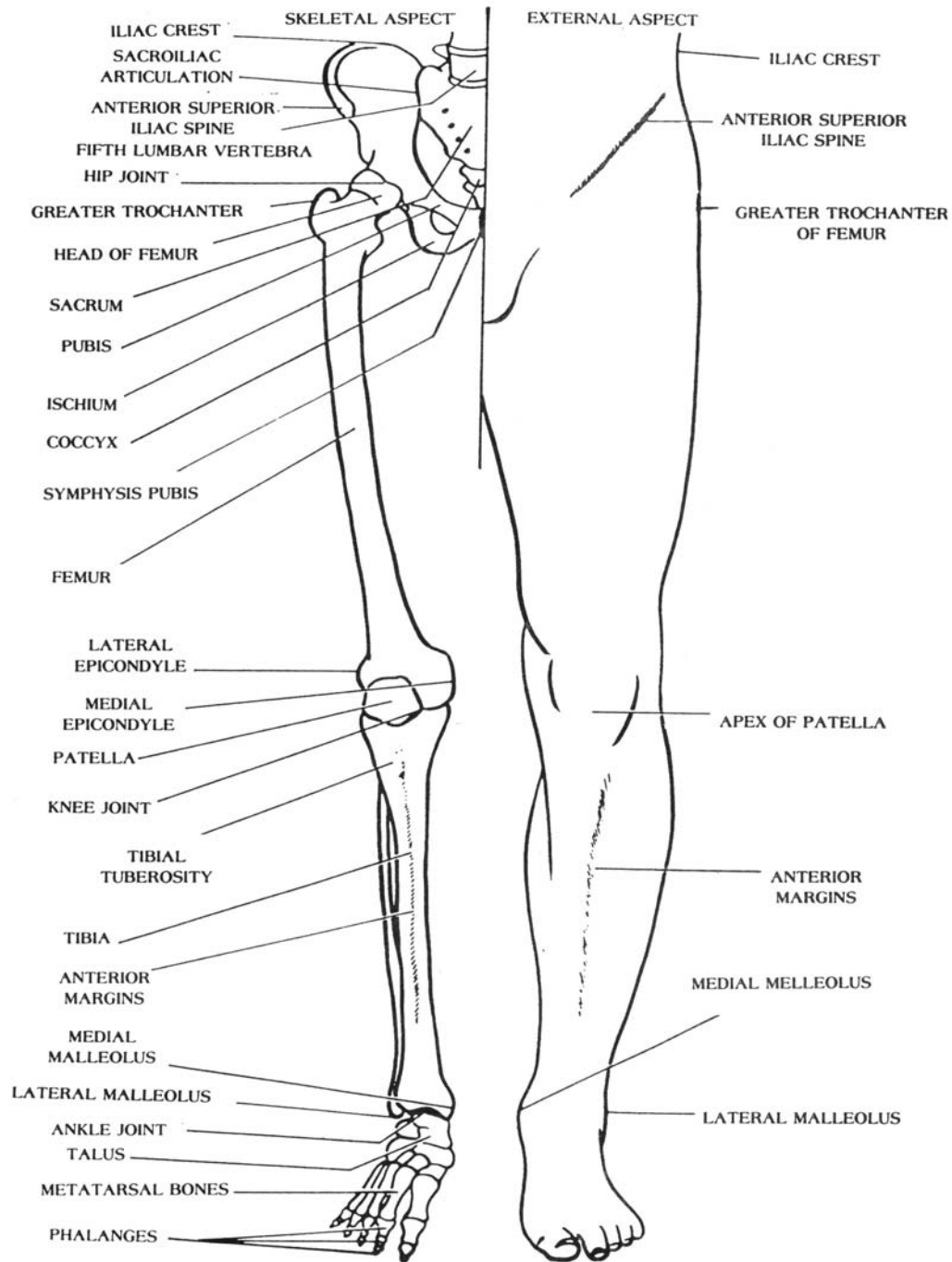


Figure 2-17. Landmarks and palpation points of the pelvis and lower extremity.

## Section III. THE VERTEBRAL COLUMN

### 2-16. OVERVIEW

a. **General.** Twenty-six vertebrae make up the vertebral column. These bones are grouped under the names cervical, thoracic, lumbar, sacral, and coccygeal according to the regions they occupy. When viewed from the side (figure 2-18), the vertebral column presents four normal curves that correspond with the different regions of the column: cervical, thoracic, lumbar, and sacral (or pelvic). Anteriorly, the cervical curve is convex, the thoracic curve is concave, the lumbar curve is convex, and the sacral curve is concave (this curve includes the coccyx). The thoracic and sacral curves are termed primary curves because they develop before birth. They are sometimes indicated as the accommodation curvatures because they tend to increase the size of the thoracic and pelvic cavities. The cervical and lumbar curves are known as secondary curves because they develop after birth. The cervical curve develops when the infant is able to hold up its head (at 3 or 4 months) and sit upright (at about 9 months). The lumbar curve develops when the child begins to walk (at 12 to 18 months). In addition to these alternate curvatures, the vertebral column normally has a slight lateral curvature when viewed from the anterior aspect. In most cases, the convexity of the lateral curvature is directed toward the right side and is associated with right-handedness. It is considered to be produced by the normal pull of the muscles.

b. **Abnormal Curves of the Vertebral Column.** A complex lateral curvature of the entire vertebral column, curves in thoracic and lumbar regions is called scoliosis. An exaggerated dorsal curvature is called kyphosis, or "humpback". Exaggerated curvature of the lumbar region is called lordosis, or swayback.

c. **Numbering System for Vertebrae.** Region and number generally designate vertebrae. For convenience, abbreviations are used. Beginning superiorly at the first cervical vertebra, or atlas, the abbreviation is C-1; the second cervical vertebra, or axis is C-2; and numbering continues inferiorly to C-7. Because C-7 has a prominent spine, it is called vertebra prominens. In the thoracic region, the abbreviations are T-1 to T-12. The vertebrae in the lumbar region are abbreviated L-1 inferiorly to L-5.

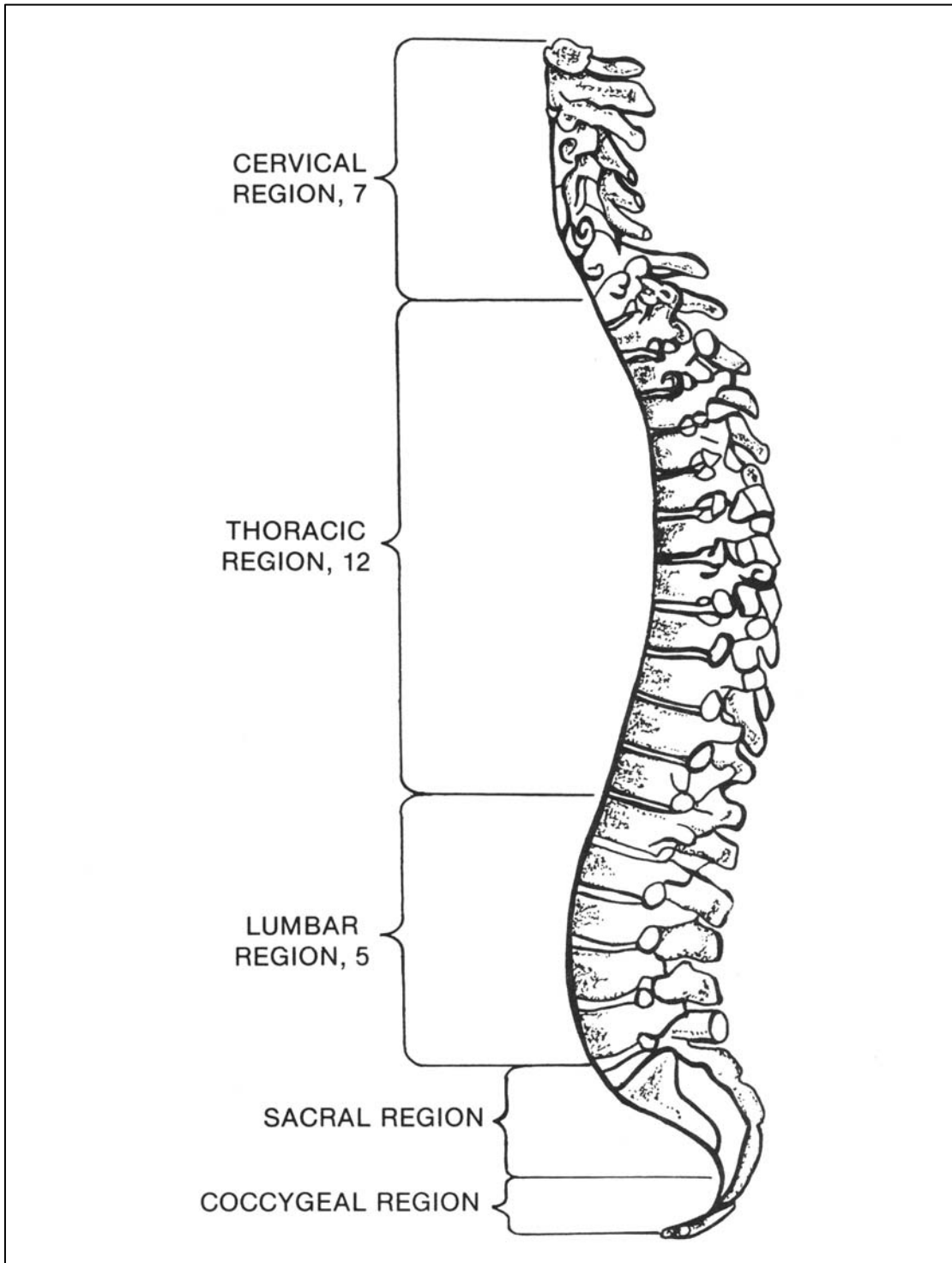


Figure 2-18. Lateral aspect of the vertebral column demonstrating normal curves.

## 2-17. FUNCTIONS OF THE VERTEBRAL COLUMN

The vertebral column functions as a strong pillar for the support of the trunk and the cranium, provides articular surfaces for the attachment of the ribs, and affords protection for the spinal cord and the roots of the spinal nerves. It transmits the weight of the trunk to the inferior extremities. Although forming a continuous support-bearing column, it is flexible enough to permit bending of the trunk in various directions. The vertebral canal, which follows the different curves of the column, accommodates and protects the spinal cord; it is formed by the superimposition of the vertebrae in each of which there is a vertebral foramen. Despite its flexibility, the vertebral column is sufficiently firm and strong to serve as a base for the origin of many ligaments and muscles and as a lever for the spinal muscles, which function to maintain the upright position of the trunk.

## 2-18. VERTEBRAL STRUCTURE

a. **General.** Most of the vertebrae have a similar general structure, that is, they all present certain characteristics. Thus, certain ones can be used as a pattern and are called typical vertebrae. In spite of this general similarity, the vertebrae in the different regions are so modified and present characteristics so peculiar to the region which they occupy that, when examined separately, it is possible to determine the region to which each belongs.

b. **Typical Vertebrae.** Except for slight modifications due to position and function, all of the typical vertebrae (figure 2-19) have the same general structure. They are indicated as follows: C-3 to C-7, T-1 to T-12, and L-1 to L-5. A typical vertebra is composed of:

- (1) A centrum, or body, which is the disk-like central portion.
- (2) The neural arch, which is made up of two roots or pedicles (small feet) and two laminae (layers of bone).
- (3) The vertebral foramen, an opening behind the body that is bounded laterally and posteriorly by the neural arch and anteriorly by the body. The apposition of all the vertebrae forms the vertebral canal that accommodates the spinal cord.
- (4) The vertebral notches, one on the superior border of each pedicle and one on the inferior border which, by the apposition of the adjacent vertebrae, form the intervertebral foramina (singular, foramen) for the transmission of the spinal nerves and vessels.

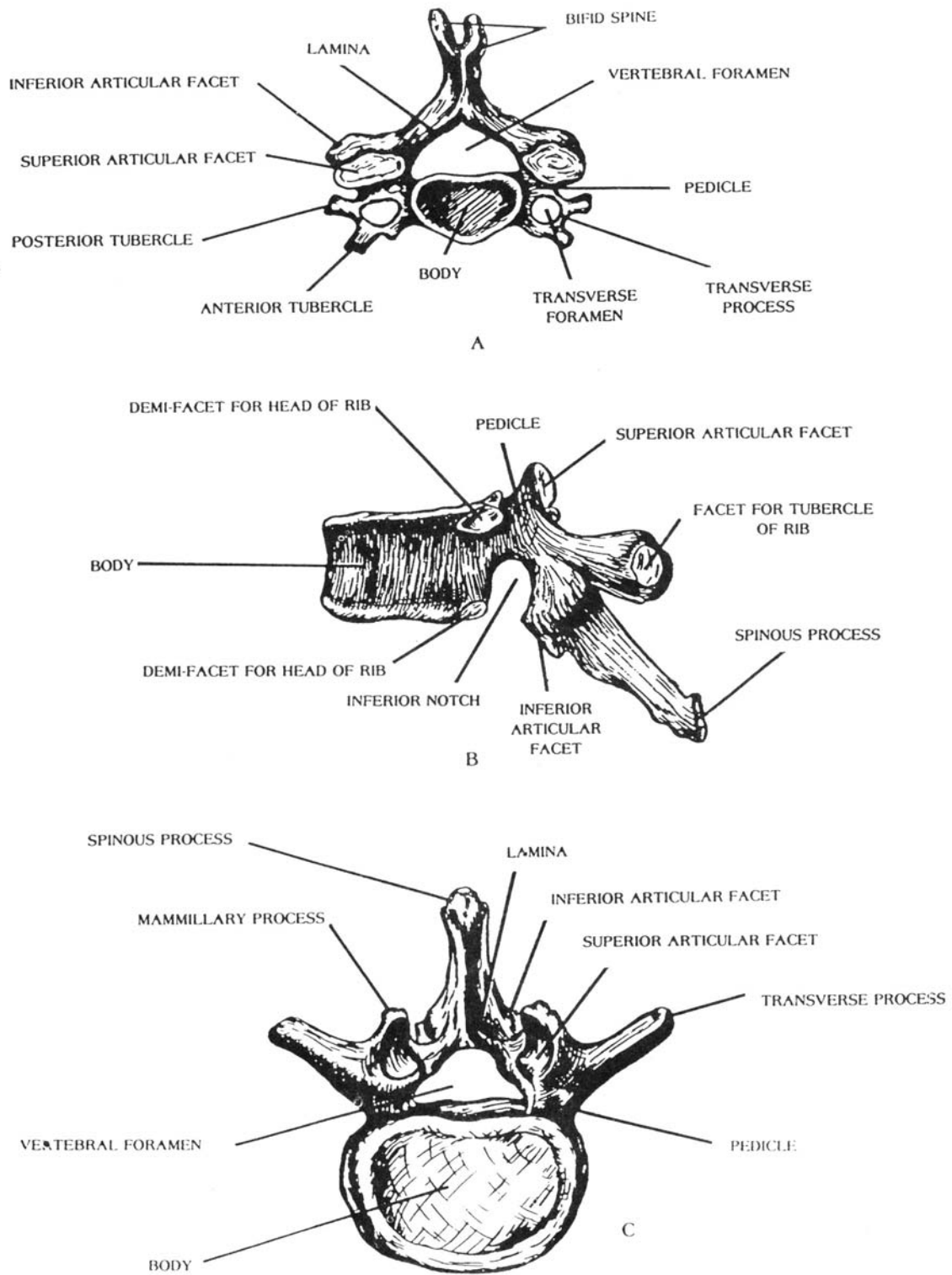


Figure 2-19. The typical vertebrae. (A, typical cervical vertebra; B, typical thoracic or dorsal vertebra; C, typical lumbar vertebra).

(5) The processes consist of the following:

(a) A spinous process that is directed dorsally and is formed at the junction of the two laminae.

(b) Two transverse processes that project laterally and are formed at the junction of the pedicles and laminae.

(c) Two superior articular (apophyseal) processes (with articular surfaces) that project upward and face dorsally.

(d) Two inferior articular (apophyseal) processes (with articular surfaces) that project downward and face ventrally.

c. **Articulation of Typical Vertebrae.** A typical vertebra articulates with contiguous vertebrae as follows:

(1) The superior and inferior surfaces of the body articulate with the bodies of the adjacent superior and inferior vertebrae through intervertebral disks of elastic fibrocartilage interposed between the bodies of the articular vertebrae to act as cushions.

(2) The articular surfaces of the superior articular processes articulate with the articular surfaces of the inferior articular processes of the vertebra above.

(3) The articular surfaces of the inferior articular processes articulate with the articular surfaces of the superior articular processes of the vertebra below.

## 2-19. DIFFERENTIATING CHARACTERISTICS OF TYPICAL VERTEBRAE BY REGIONS

a. **Cervical Vertebrae.** C-3 to C-7 (figure 2-19A) have small oval-shaped bodies and the spinous processes of all these, except C-7, are short and bifid (cleft). C-7 has a long, thick, prominent, nonbifurcated process that is a vertebral landmark. Each of the cervical vertebrae has a hole in the transverse process called the transverse foramen.

b. **Thoracic Vertebrae.** The thoracic vertebrae, designated as T-1 to T-12 (figure 2-19B) have large bodies. Their spinous process point inferiorly and all of them present facets (most also demifacets) on the lateral aspects of their bodies that articulate with the ribs.

c. **Lumbar Vertebrae.** Vertebrae designated L-1 to L-5 (figure 2-19C) have very large bodies. Their spinous processes are broad and project horizontally. The superior articular process presents on its posterior margin, the mammillary process.



## 2-20. ATYPICAL VERTEBRAE

Atypical vertebrae (figure 2-20) are those vertebrae whose structure is highly modified by function and position. They consist of the first cervical vertebra (C-1) or atlas, the second cervical vertebra (C-2) or axis, the sacrum, and the coccyx.

### a. The Atlas.

(1) The first cervical vertebra (C-1) is named the atlas because it supports the head (figure 2-20A). It is characterized by the absence of both body and spinous process and consists of an anterior and posterior arch, two lateral masses, and a vertebral foramen. The anterior surface of the anterior arch presents a slight projection, the anterior tubercle. The posterior surface is marked by a dental facet for articulation with the dens or odontoid process of the axis. On the superior surface are two grooves for the vertebral arteries.

(2) The morphology of the atlas affords freedom of movement of the skull. The body of the atlas is transferred to the axis (second cervical vertebra) where it becomes the dens (odontoid process), which articulates with the dental facet (facet for odontoid) of the anterior arch of the atlas, thus making possible the rotary movements of the skull. The superior articular surfaces of the atlas are concave for reception of the condyles of the occipital bones, permitting flexion, extension, and hyperextensions of the skull.

b. **The Axis.** The second cervical vertebra (C-2) is named the axis, or epistropheus, because it forms the pivot upon which the atlas rotates when the head is turned from side to side (figure 2-20B). The axis differs primarily from a typical vertebra by the presence of a tooth like projection, called the dens or odontoid process, which rises perpendicularly from the upper surface of the body. On its anterior surface, the dens presents an oval facet for articulation with the dental facet on the anterior arch of the atlas. On its posterior surface is a shallow groove that receives the transverse ligament of this articulation. The relationship of the atlas and axis to the skull is shown in figure 2-21A. Other spinal articulations are also illustrated in figure 2-21.

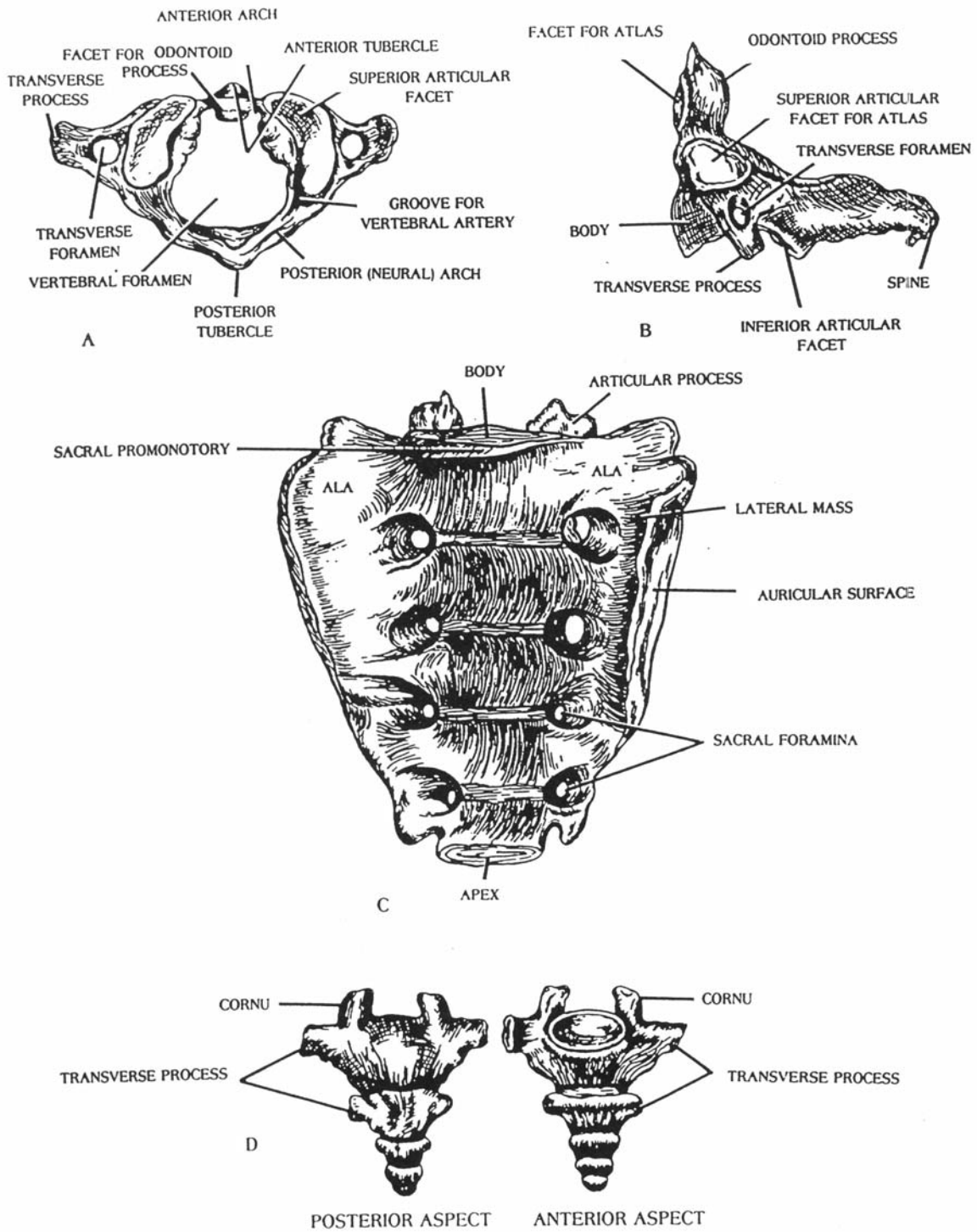


Figure 2-20. The atypical vertebrae. (A, first cervical vertebra, or atlas; B, second cervical vertebra, or axis; C, sacrum; D, coccyx).

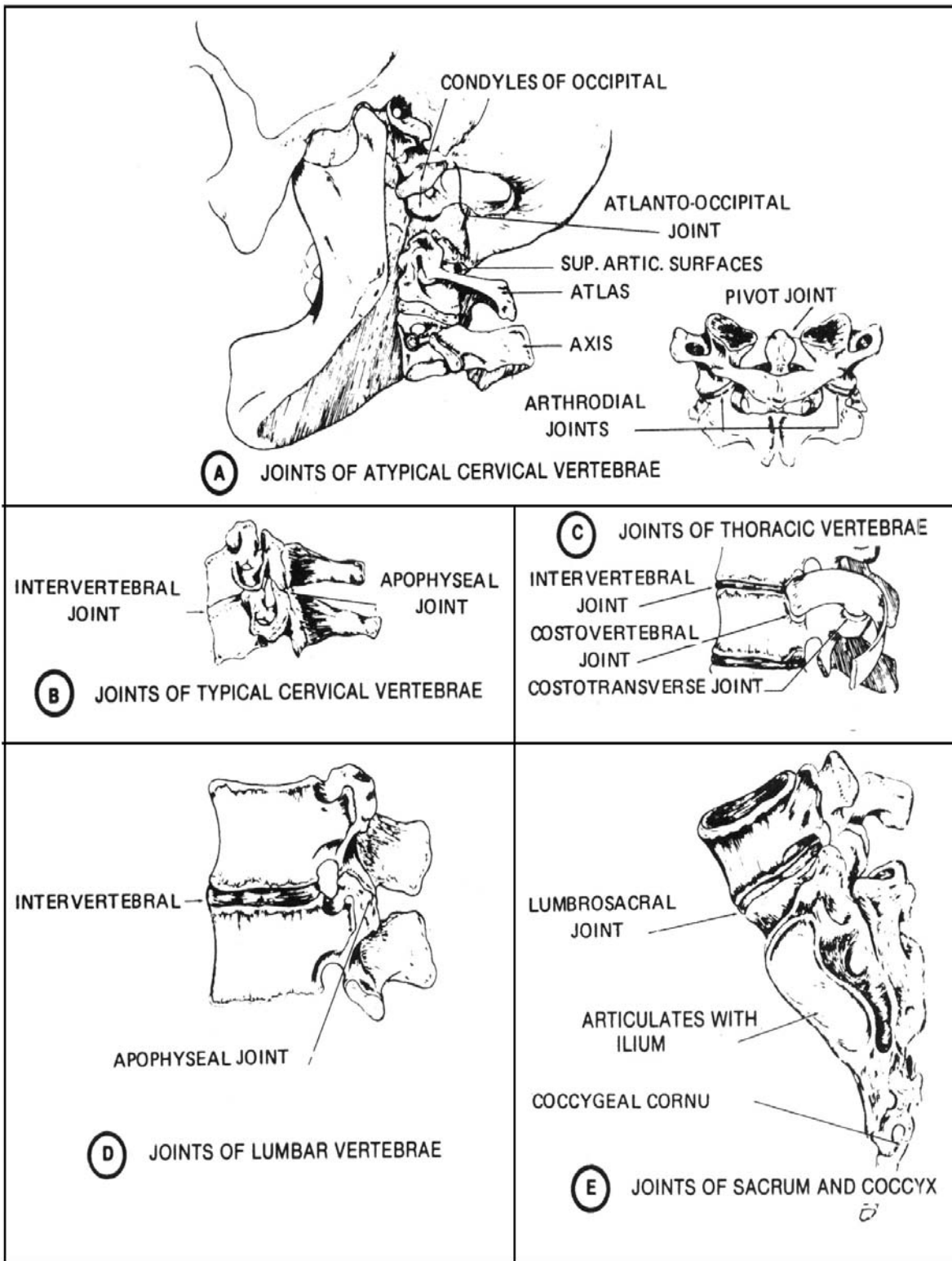


Figure 2-21. Joints of the spine.

c. **The Sacrum.** In the adult, the sacrum (figure 2-20C) is a single bone formed by the fusion of the five sacral segments. It is a large wedge-shaped (triangular) bone situated in the lower part of the vertebral column and at the upper and back part of the pelvic cavity where it is wedged between the two hipbones. Its base is directed upward and its apex is directed downward. In the center, the base presents the kidney-shaped body; behind this is the superior opening of the sacral canal, which is bounded laterally by the articular processes. The sacral promontory is a prominent ridge at the upper anterior margin of the body. The body articulates with the body of L-5 to form the lumbosacral articulation. On either side of the body is a wing-like surface called the ala (wing) of the sacrum.

(1) The dorsal surface of the sacrum is rough and convex. In the middle line, the dorsal surface displays a ridge, the median sacral crest, made up of three or four rudimentary spinous processes that are more or less fused to form the crest. There are four posterior sacral foramina, which transmit several sacral nerves.

(2) The ventral or pelvic surface of the sacrum is smooth and concave. The anterior sacral foramina transmit some of the sacral nerves.

(3) The lateral surface or margin of the sacrum presents in front an ear shaped surface for articulation with the articular surface of the ilium.

d. **The Coccyx.** The coccyx usually consists of three to five rudimentary coccygeal segments that fuse in adult life (figure 2-20D). From its base downward to its apex, the coccyx diminishes in size. It curves downward and forward from its articulation with the sacrum, often deviating from the median plane of the body.

## 2-21. VERTEBRAL LANDMARKS

The important landmarks of the vertebral column are shown in figure 2-22. Study these carefully. Note other structures at similar levels.

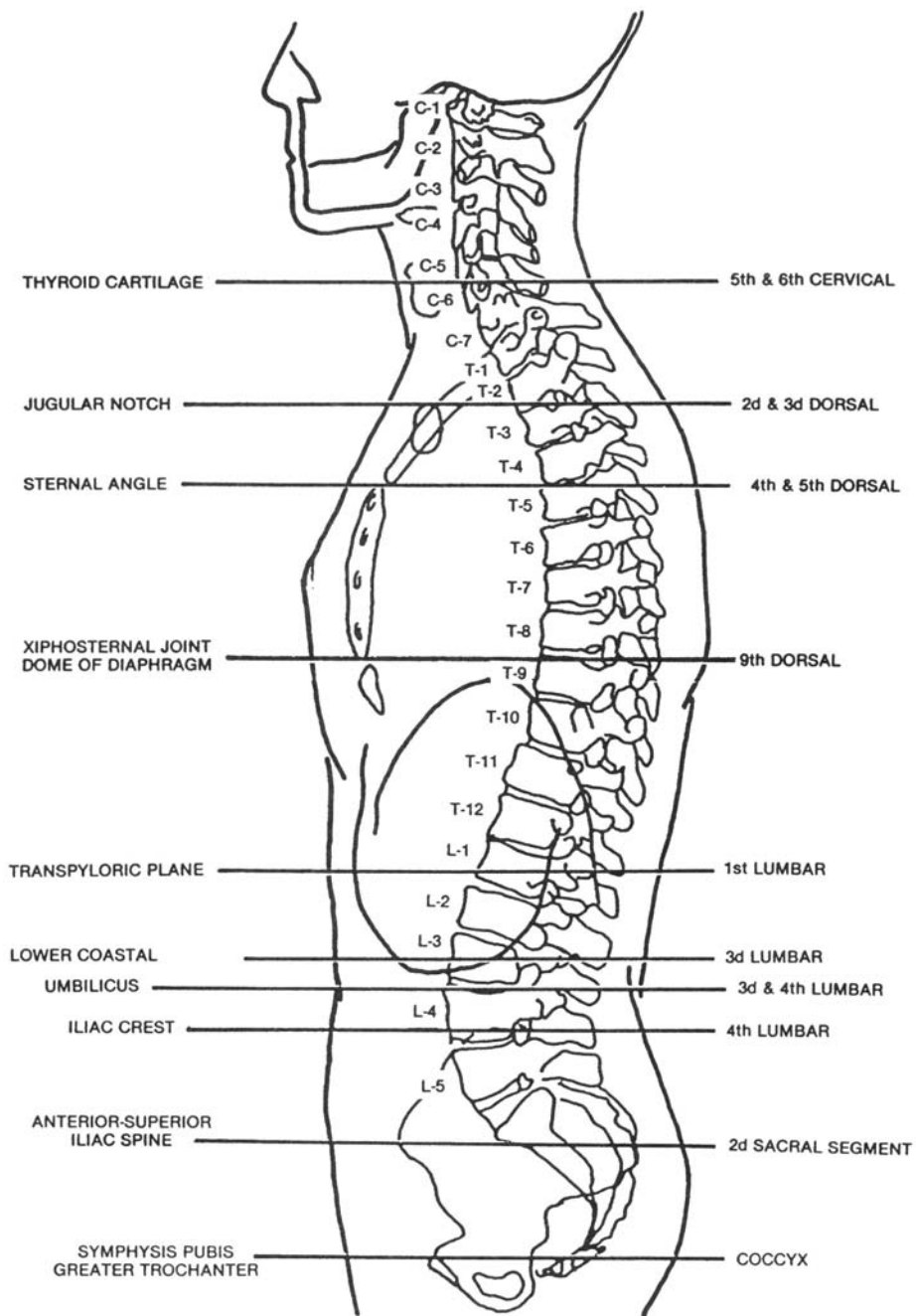


Figure 2-22. Vertebral landmarks.

## Section IV. THE THORAX

### 2-22. GENERAL

The bony thorax (figure 2-23) is a cone-shaped cage formed by the sternum, the costal cartilages, the 12 pairs of ribs, and the bodies of the 12 thoracic vertebrae. The thorax contains and protects the heart, lungs, and great vessels. It serves for the attachment of muscles and acts as a mechanical agent in the breathing process. The shape and mobility of the ribs make possible the enlargement of the thoracic cavity when they are elevated. The bony thorax, together with the intercostal muscles, plays an important part in respiration.

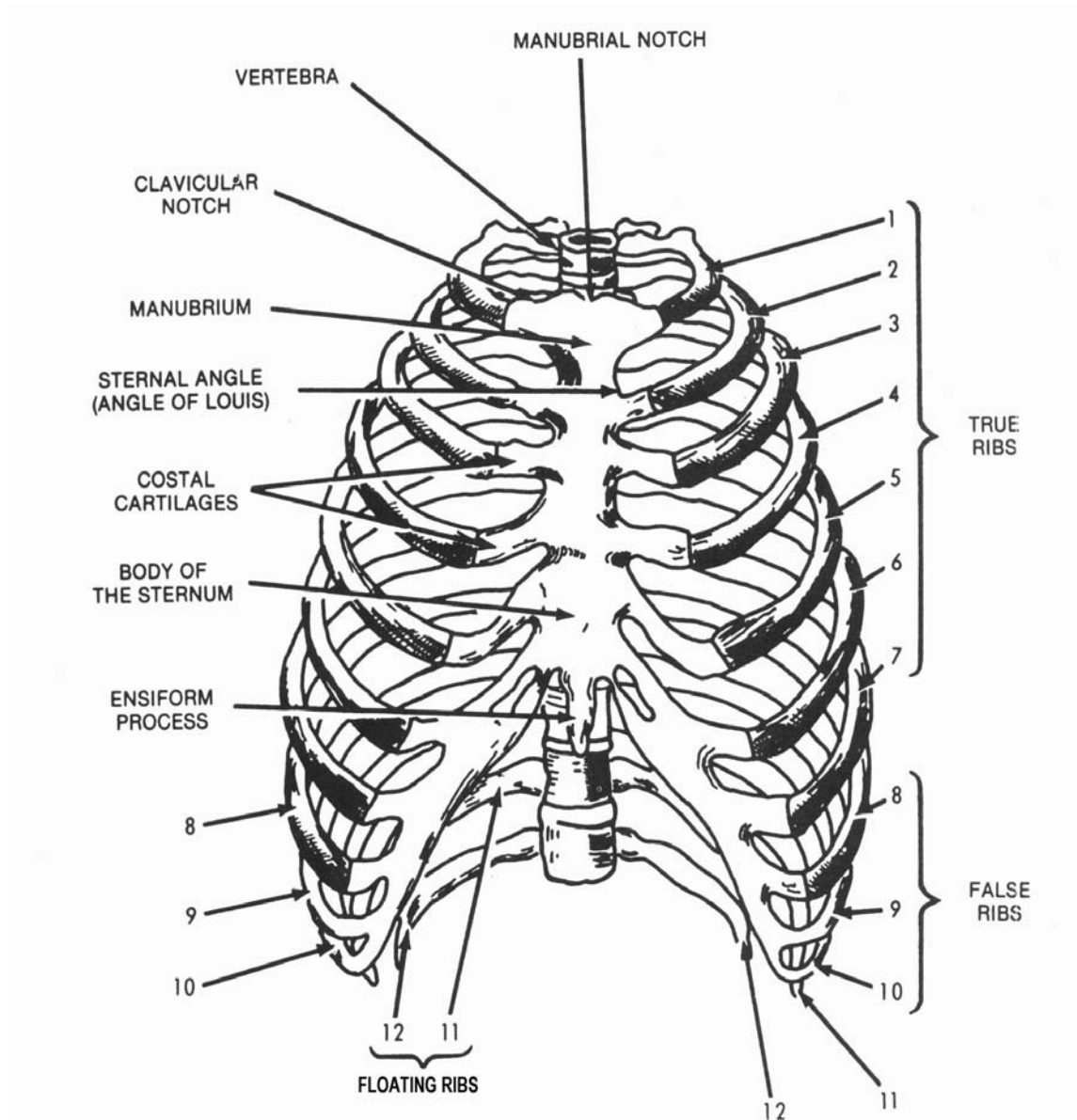


Figure 2-23. Anterior aspects of the thoracic cage.

## 2-23. THE STERNUM

a. **Parts of the Sternum.** The sternum, or breastbone (figure 2-24), is an elongated, flattened bone situated in the median line in the front of the chest. It consists of three parts, named: from top to bottom, the manubrium, the body or gladiolus, and the ensiform process or xiphoid process. The superior border of the manubrium presents three notches, the middle jugular or manubrial notch and two lateral clavicular notches for the reception of the sternal ends of the clavicles. The inferior border of the manubrium articulates with the superior border of the body of the sternum, forming an angle (called the sternal angle or angle of Louis) that may be readily palpated. The sternal angle marks the position of the second ribs, as well as the junction of the manubrium, and the body of the sternum. The ensiform process, or xiphoid process, the smallest of the three parts, varies much in form: it may be partly or wholly cartilaginous, perforated by a foramen, broad and thin, pointed, bifid, deflected considerably to one side or another, or inverted.

b. **Articulations of the Sternum.** The sternum articulates on either side with the clavicle at the clavicular notch and with the upper seven costal cartilages at the costal notches on the lateral border of the manubrium and the body (figure 2-24).

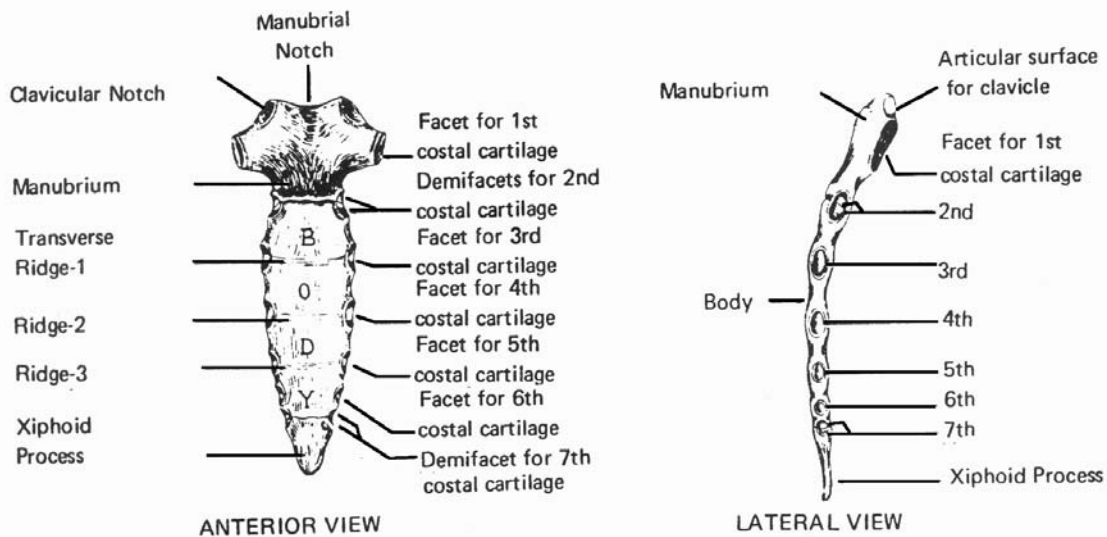


Figure 2-24. The sternum.

## 2-24. THE RIBS

a. There are 12 pairs of ribs (figure 2-23). They are numbered from above downward as the first, second, third, and so forth., and as the right or the left. The 1st, 11th, and 12th ribs articulate posteriorly with the body of the corresponding vertebrae, while the remaining ribs articulate with the corresponding vertebrae as well as with the vertebrae immediately above. The first seven pairs are the true (sternal) ribs; their anterior extremities articulate with the sternum by means of the costal cartilages. The remaining five pairs are the false (asternal) ribs; they are not connected directly to the sternum. The 8th, 9th, and 10th ribs have their cartilages attached to the cartilage of the rib above and are called the vertebrochondral ribs. The 11th and 12th ribs are free at their anterior extremities and are floating (vertebral) ribs.

b. A typical rib (figure 2-25) possesses the following common characteristics.

(1) A vertebral extremity that presents for examination a head that articulates with the superior demifacet of the corresponding vertebra and the inferior demifacet of the vertebra above a short constricted part called the neck, and a tubercle, consisting of a medial articular portion and a lateral nonarticular portion. The articular portion is for articulation with the costal facet on the transverse process of the corresponding thoracic vertebra. The nonarticular portion is for the attachment of ligaments.

(2) A body or shaft, the long, flattened, curved part of the rib is marked by an angle and a costal groove.

(3) An oval pit into which the costal cartilage is received marks a flattened sternal extremity.

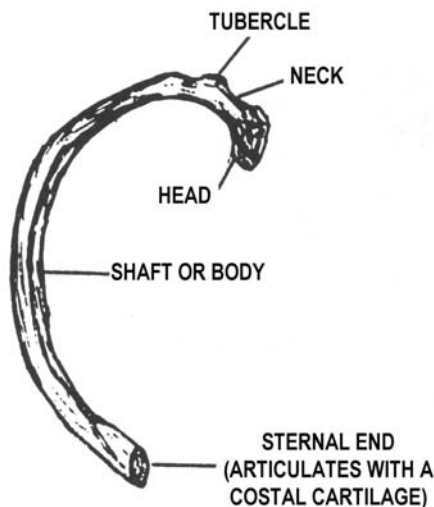


Figure 2-25. A typical rib.



## 2-25. LANDMARKS OF THE TRUNK

Landmarks and palpation points of the trunk are shown in figure 2-26. As with other figures showing palpation points, this is worthy of your careful study.

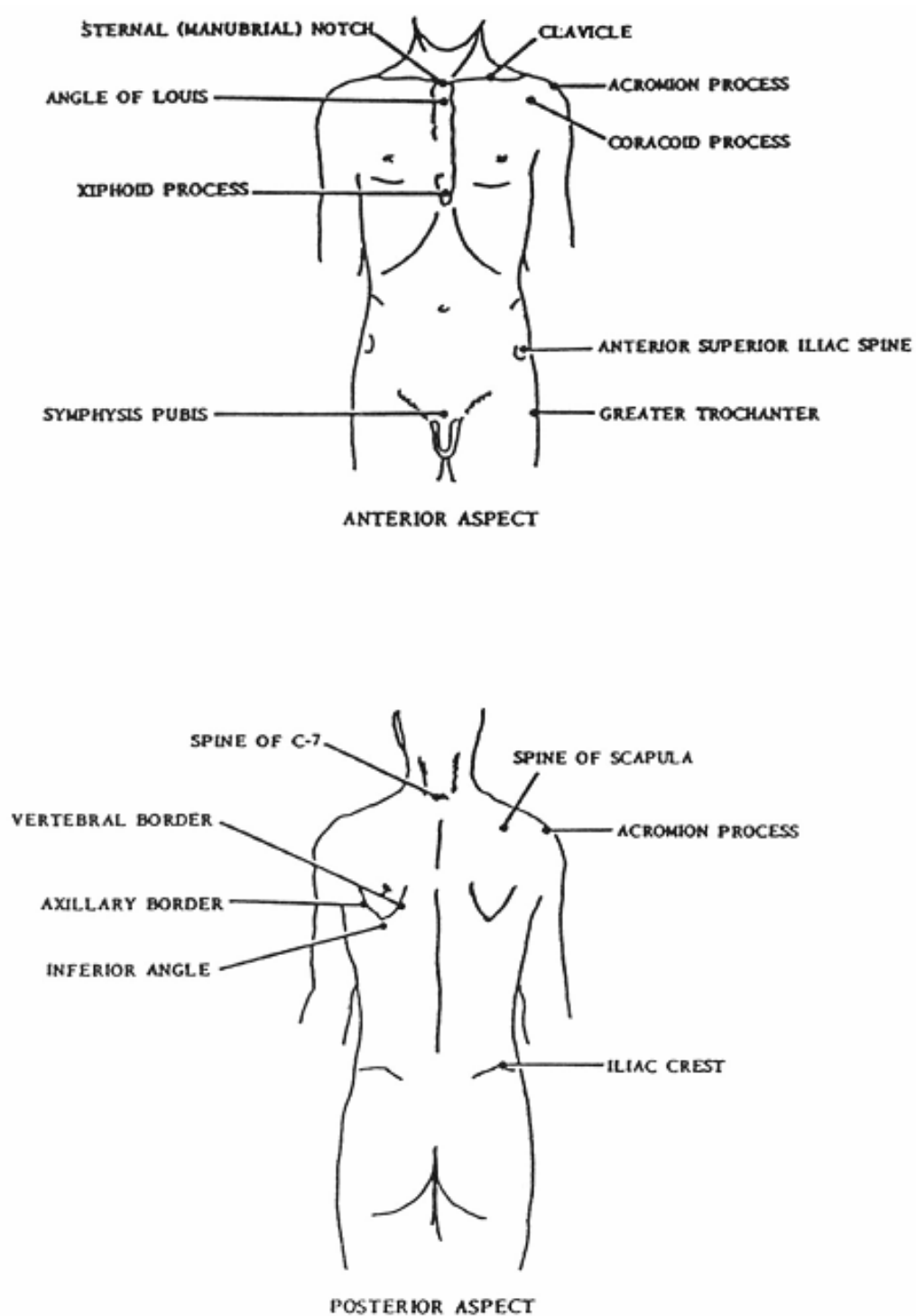


Figure 2-26. Landmarks and palpation points of the trunk.

## Section V. THE SKULL

### 2-26. GENERAL

The skull (figures 2-27, 2-28, 2-29, 2-30, and 2-31) is supported by the vertebral column. It is divided into two parts: the cranium, which lodges and protects the brain, and the facial skeleton. The cranium is composed of eight bones: one frontal, two parietal, two temporal, one occipital, one sphenoid, and one ethmoid. The facial skeleton is composed of 14 bones: two nasal bones, two lacrimal bones, two zygomatic bones, two maxillae, two palatine bones, two inferior nasal conchae, one vomer, and one mandible.

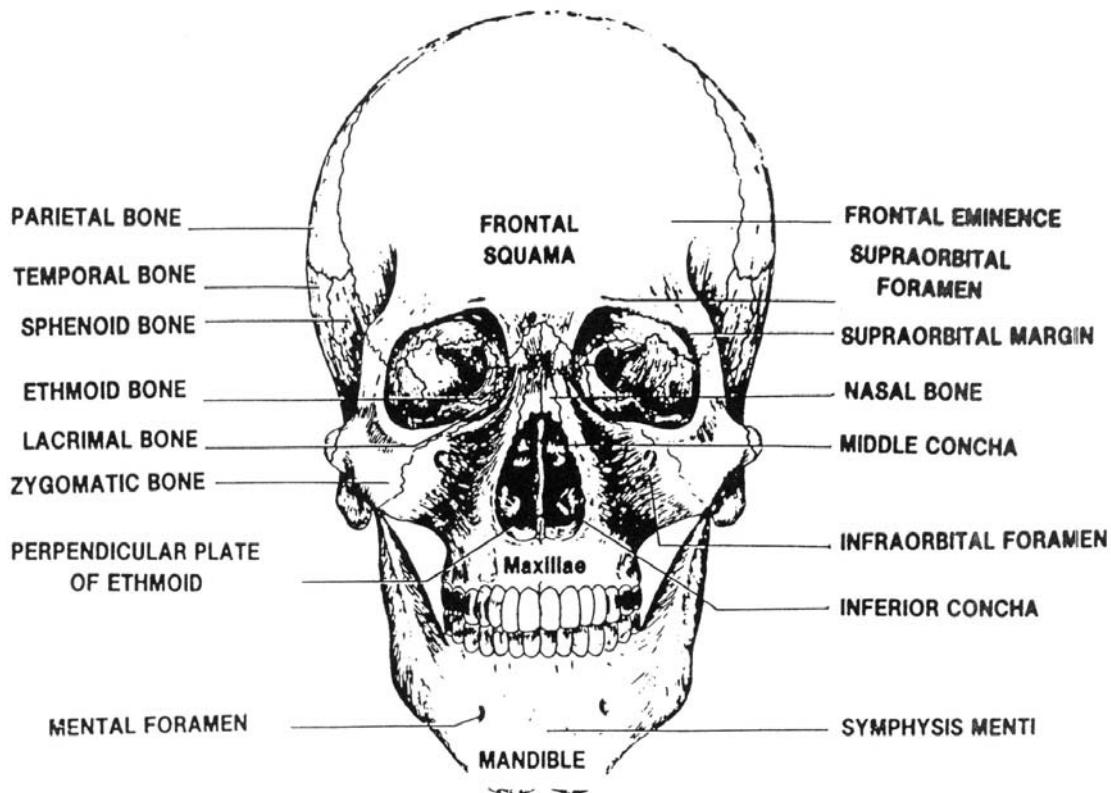


Figure 2-27. Frontal view of the skull.

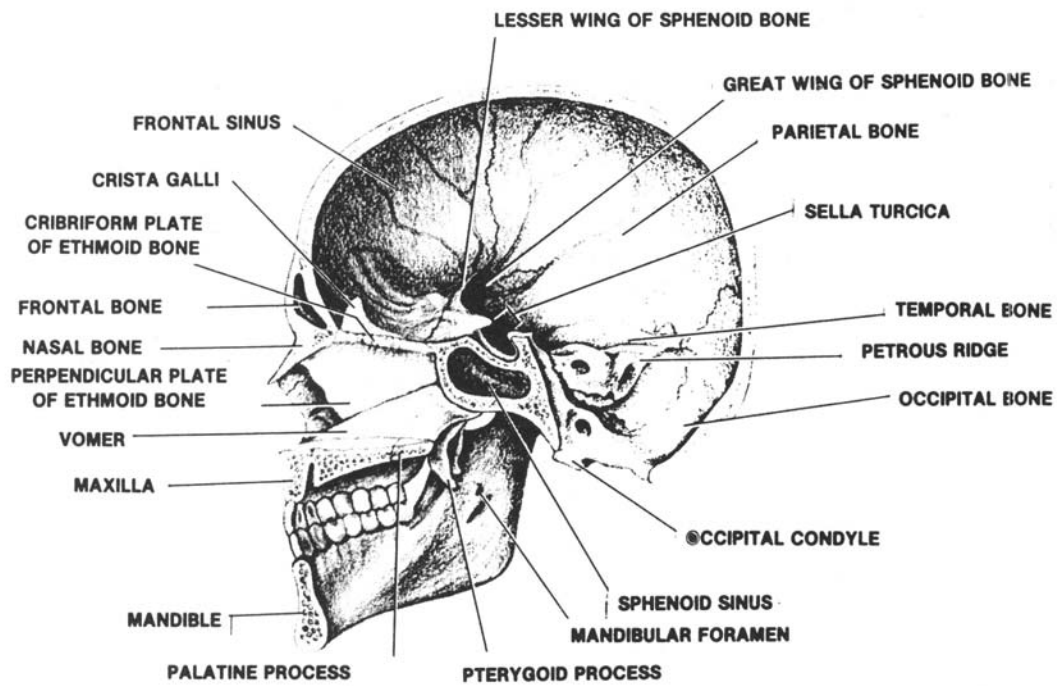


Figure 2-28. Medial view of the skull.

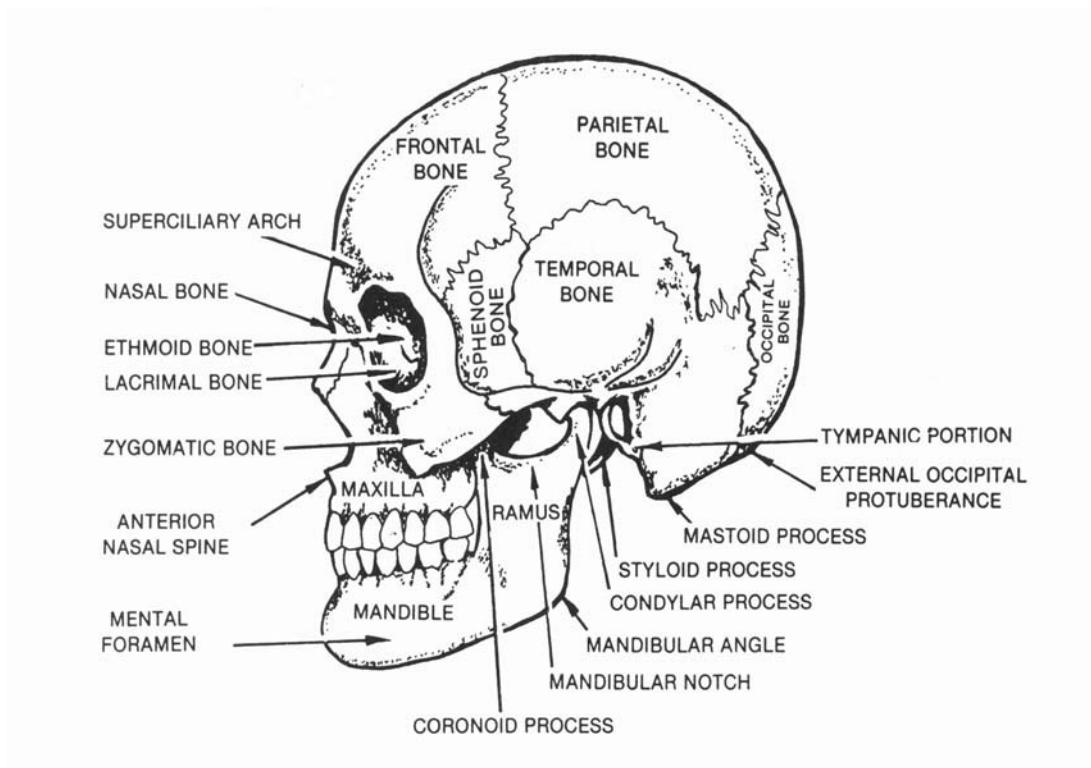


Figure 2-29. Lateral view of the skull.

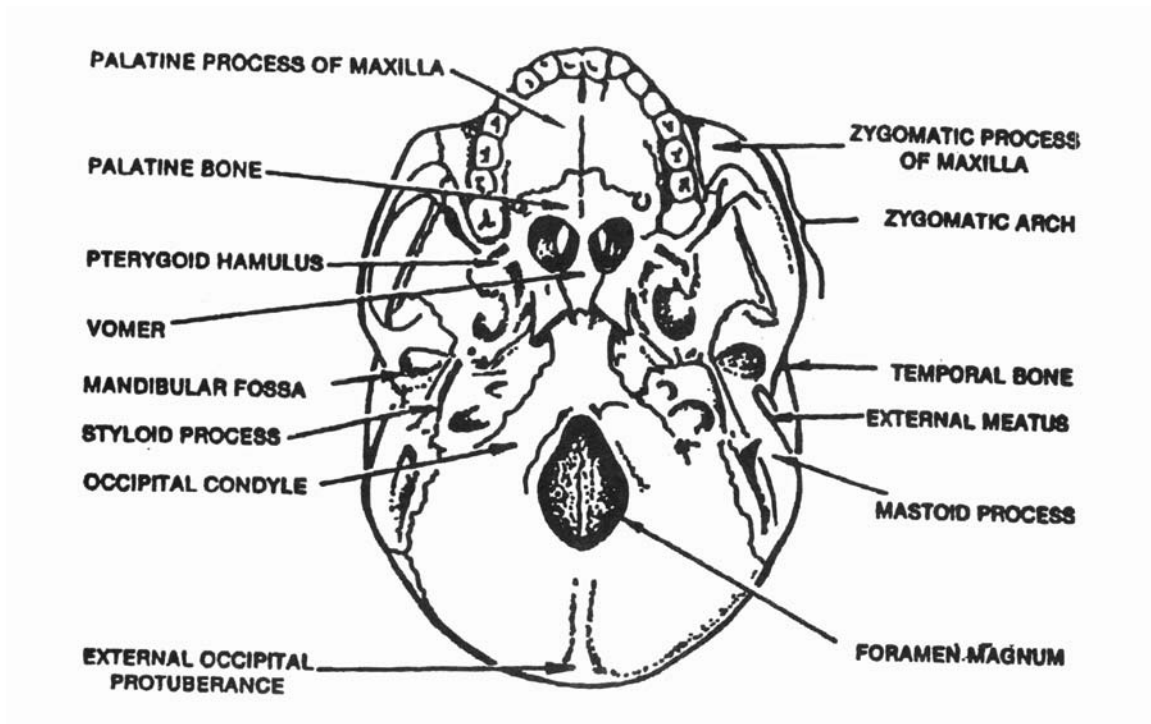


Figure 2-30. Inferior view of the skull.

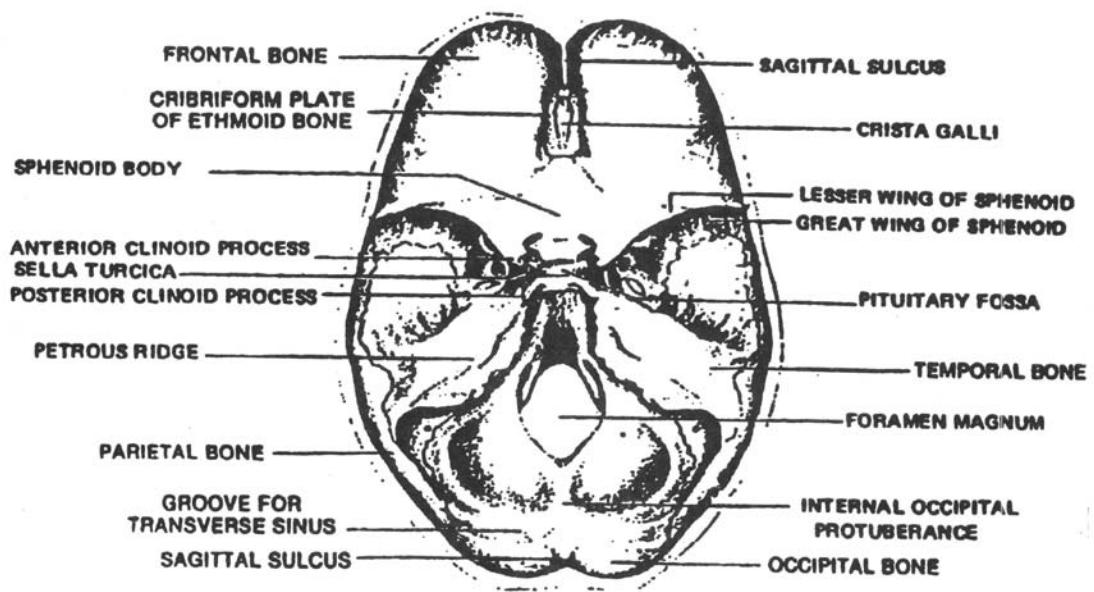


Figure 2-31. Inner surface of the cranial base.

## 2-27. INDIVIDUAL CRANIAL BONES

a. **Frontal.** The frontal bone consists of two portions: a convex portion, the squama which constitutes the region of the forehead and an orbital, or horizontal portion, which enters into the formation of the roofs of the orbits and the nasal cavity (figure 2-27).

(1) The external surface of the squama is smooth and convex anteriorly. Above the orbits are two arched elevations, the superciliary and arches (figure 2-29) which are joined by the glabella (figures 2-33 and 2-34). The frontal sinuses (figure 2-35) are situated internally behind the glabella and the superciliary arches. The supraorbital margin (figure 2-27) that forms the upper boundary of each orbit is perforated by a supraorbital notch, or foramen. The supraorbital margins terminate in the zygomatic process that joins the frontal bone and the zygomatic bone.

(2) The orbital portion consists of two orbital plates that are separated by a median gap, the ethmoidal notch. The orbital plates contribute to the formation of the roofs of the orbits and the nasal cavity. The ethmoidal notch is filled by the cribriform plate (figure 2-28) of the ethmoid bone.

b. **Parietal.** The parietal bones (figures 2-27 and 2-29) are two flat bones that unite to form the sides and the roof of the cranium. The four borders are: the sagittal (medial), squamous (lateral), frontal (anterior), and occipital (posterior). These borders form the frontal angle, the sphenoidal angle, the mastoid angle, and the occipital angle.

c. **Temporal.** Each of the two temporal bones (figures 2-27 and 2-28) consists of four divisions: the squama, mastoid, tympenic, and petrous portions.

(1) The squama forms the anterior and superior portion of the temporal bone. The zygomatic process projects from the lower part of the squama, which presents inferiorly a large oval depression, the mandibular fossa (glenoid fossa).

(2) The mastoid portion constitutes the posterior part of the temporal bone. The mastoid process (figure 2-29) is a cone-shaped projection that provides attachment for several muscles. A coronal section of the mastoid portion reveals a large number of mastoid air cells and a tympenic antrum.

(3) The tympenic portion (figure 2-29) is a curved plate lying below the squama and anterior to the mastoid process. The external acoustic (auditory) meatus (EAM) is situated in the tympenic portion. The styloid process (figure 2-30) is a slender, pointed projection attached to the inferior surface of the tympenic portion.

(4) The petrous portion (pars petrosa) (figure 2-28) resembles a pyramid hewn from rock. The base of the pyramid is fused with the internal borders of the mastoid and squamous portions. The apex, which presents the anterior opening of the carotid (arterial) canal, is directed medially and anteriorly. In most skulls, the petrous portions form approximately a 45° angle with the side of the skull. The anterior and posterior surfaces of the pyramid meet superiorly to form a dense ridge that is referred

to in radiography as the petrous ridge. The level of the petrous ridge (figure 2-31) is about 1¼ inches above the apex of the mastoid tip. On the posterior surface near the center is a large orifice, the internal acoustic meatus. Within the petrous portion are the auditory ossicles (the malleus, the incus, and the stapes), the cochlea, and the semicircular canals. The auditory ossicles and the cochlea are essential portions of the hearing mechanism and the semicircular canals are concerned with equilibrium.

(5) The styloid process (figure 2-30) is a slender, pointed, process attached to the inferior surface of the tympanic portion.

d. **Occipital.** The occipital bone (figures 2-28, 2-29, and 2-30) is at the posterior and inferior portion of the cranium. A large hole, the foramen magnum (figures 2-30 and 2-31), pierces the occipital bone. The occipital bone is divided into four parts: the squama (behind the foramen magnum), the basilar portion (anterior to the foramen), and two lateral portions, one on each side of the foramen magnum. The curved expanded squama presents externally the external occipital protuberance (EOP). Situated on the internal surface of the squama, which is deeply concave, are the internal occipital protuberance and the grooves which lodge the blood sinuses. On the inferior surfaces of the lateral portions are the occipital condyles that articulate with the atlas (C-1) of the spine. The basilar portion extends anteriorly and superiorly from the foramen magnum and is attached to the body of the sphenoid bone.

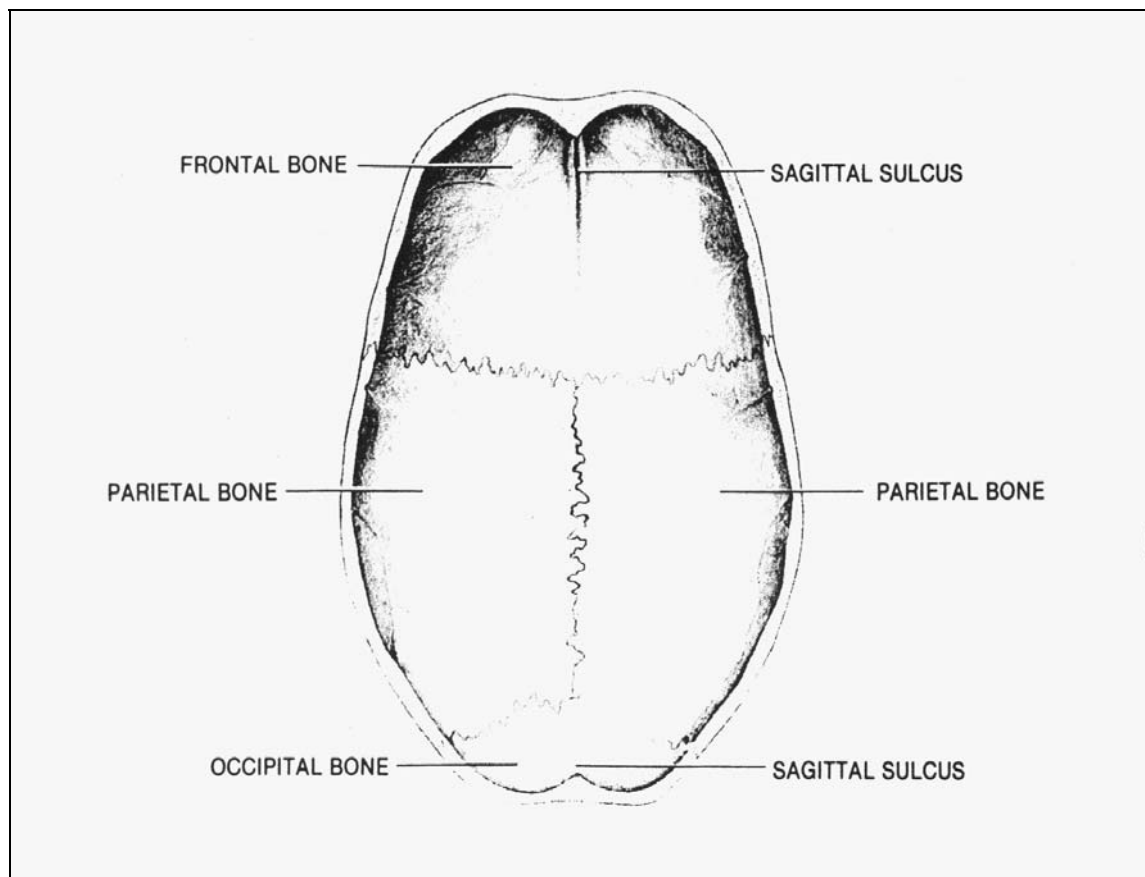


Figure 2-32. Inner surface of the cranial roof.

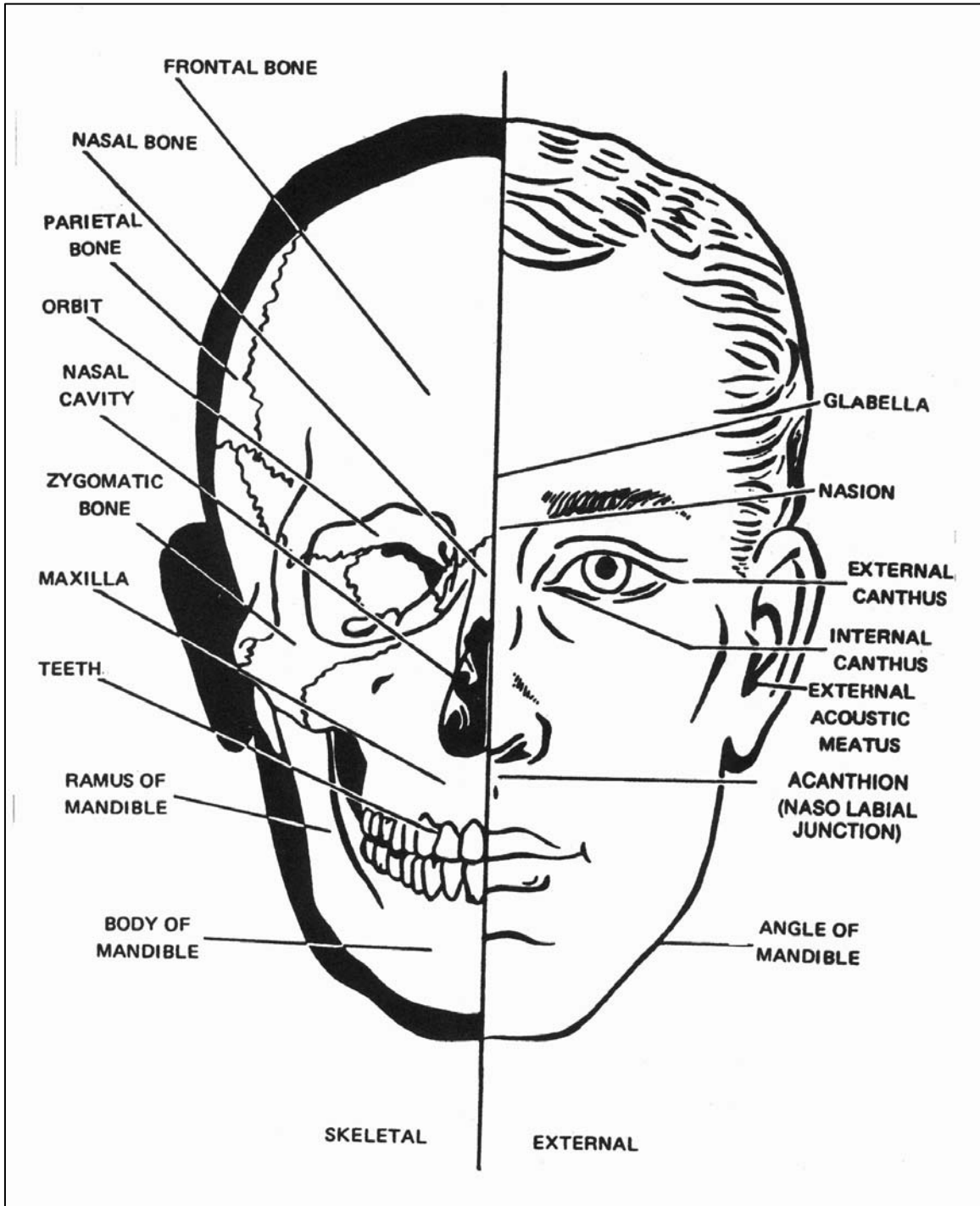


Figure 2-33. Landmarks of the skull (frontal aspect).

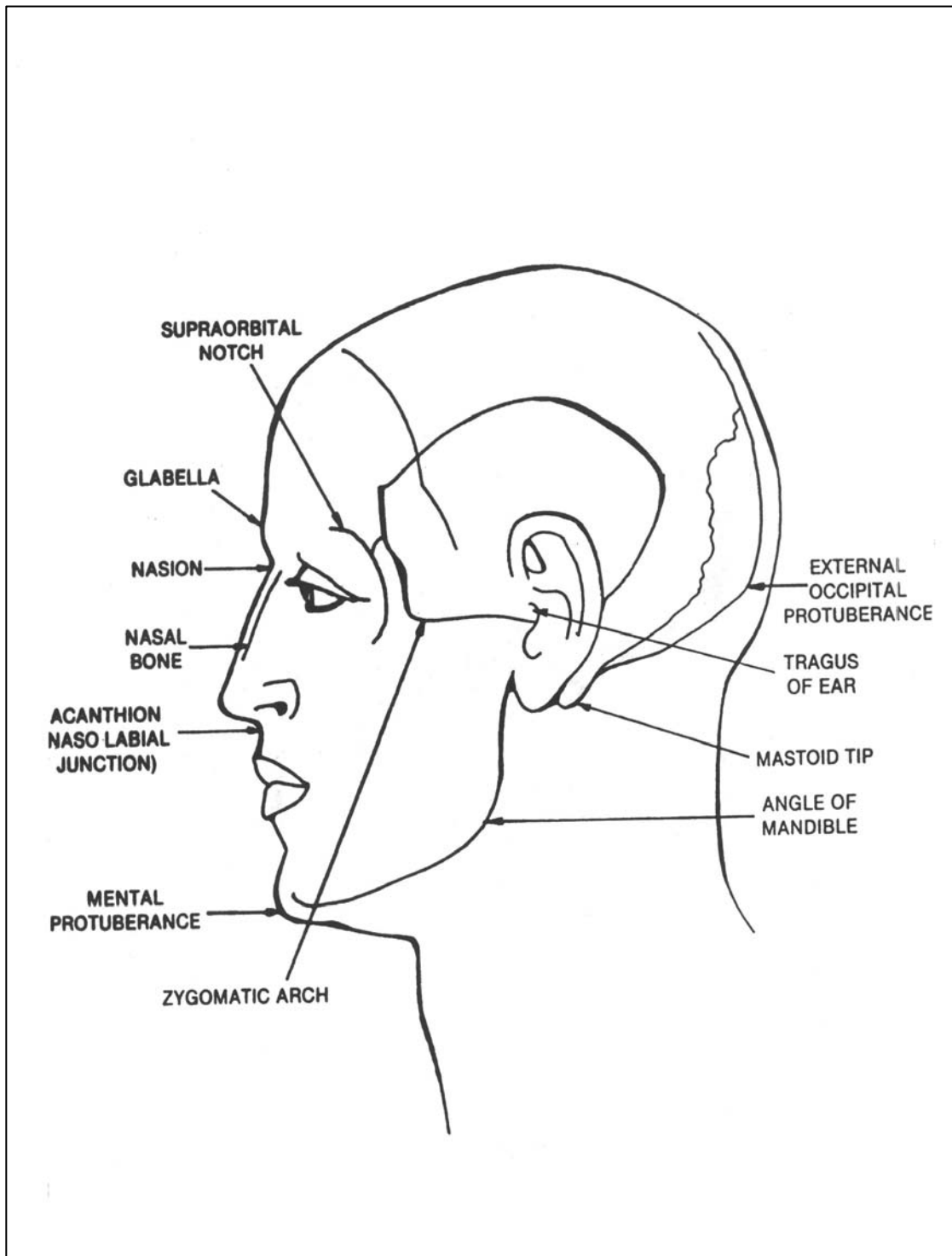


Figure 2-34. Landmarks of the skull (lateral aspect).



e. **Sphenoid.** The sphenoid bone (figures 2-27, 2-28, 2-29, and 2-30) is at the base of the skull in front of the temporals and the basilar part of the occipital bone. In form, it resembles a bat with its wings extended. It is divided into a body, two greater wings, two lesser wings, and two pterygoid processes.

(1) The cubical-shaped body (figure 2-31) is hollowed out internally to form two large cavities, the sphenoidal air sinuses (figure 2-35). On the superior surface of the body is the sella turcica (Turkish saddle) (figures 2-28 and 2-31). Situated within the saddle is the pituitary fossa, that receives the pituitary gland. Anteriorly, the sella turcica is bounded by an eminence, the tuberculum sellae. Anterior, to the tuberculum sellae, is a transverse groove called the optic(chiasmatic) groove, which terminates laterally in the optic foramen. Each optic nerve leaves the posterior aspect of the eye, goes through the optic foramen, crosses in the chiasmatic groove (one-half of the fibers do not cross), and terminates in the brain.

(2) The lesser wings (figure 2-31) project laterally away from the anterior aspect of the body and terminate medially as the anterior clinoid processes. The optic foramen, situated in the back of the orbit, is part of the lesser wing.

(3) The greater wings (figure 2-31) project anteriorly and laterally away from the body to form, in part, the posterior aspect of the orbit and a portion of the lateral walls and floor of the cranium.

(4) The "legs" of the bat descend from the greater wings as the pterygoid processes (figure 2-28).

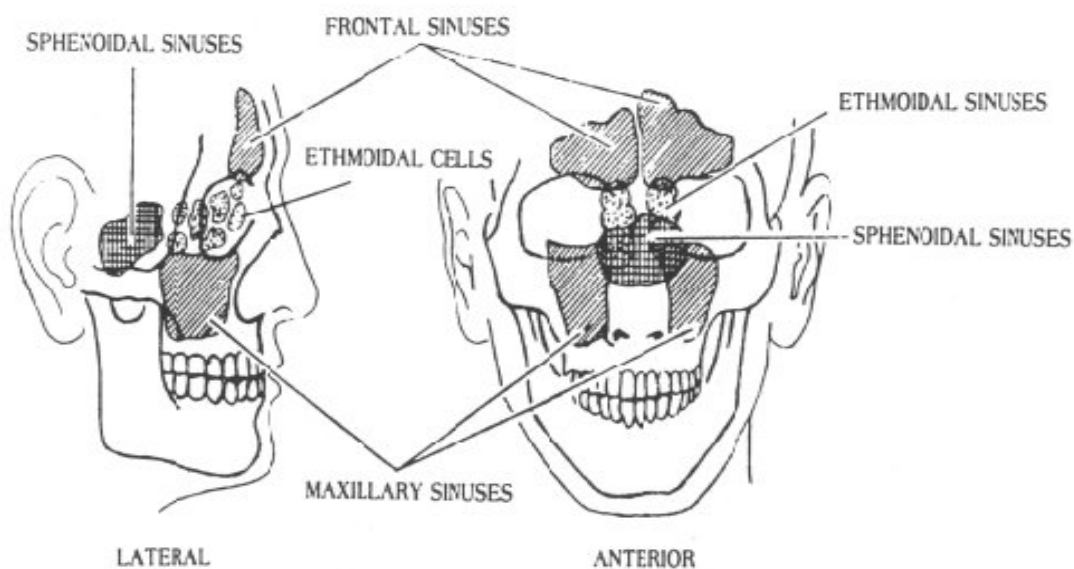


Figure 2-35. The paranasal sinuses (lateral and anterior aspects).

f. **Ethmoid.** The ethmoid bone (figures 2-27, 2-28, 2-29, and 2-30) is between the two orbits. The bone is light and spongy in appearance and cubical in shape. It consists of four parts: a horizontal or cribriform plate, a perpendicular plate, and two lateral masses.

(1) The cribriform plate (figure 2-31) is a perforated plate that is received into the ethmoidal notch of the frontal bone and the roof of the nasal cavity. The olfactory nerves pass from the brain through the perforations and into the nasal cavity. The crista galli projects superiorly from the midline of the cribriform, or horizontal plate. The fold of the dura mater dividing the hemispheres of the brain is attached to the crista galli (figure 2-31).

(2) The perpendicular plate (figure 2-28) is a thin plate that projects inferiorly from the cribriform plate. The perpendicular plate is joined inferiorly with the vomer to help form the nasal septum.

(3) The lateral masses, or labyrinths, consist of a large number of thin-walled cellular cavities. The spaces within these cells constitute the ethmoid sinuses (figure 2-35). The superior and middle nasal conchae are spiral convoluted plates projecting downward from the inner walls of the masses.

g. **Special Joints (Sutures) of the Cranial Bones.** The cranial bones are held rigidly together by means of special interlocking, immovable joints known as sutures (figures 1-14 and 2-36). The most important of these sutures are the sagittal suture (between the medial adjacent border of the two parietal bones), the coronal suture (between the posterior border of the frontal bone and the anterior borders of the two parietal bones), the lambdoidal suture (between the posterior-inferior border of the two parietal bones and the posterior-superior border of the occipital bone), and the squamous suture (between the lateral inferior border of the parietal and the upper squamous part of the temporal bone). The point of junction of the coronal and sagittal sutures is known as the bregma and indicates the position of the anterior fontanelle in the fetal skull, which represents an unossified membranous interval between these bones before ossification is complete (normally at about 18 months of age). The point of junction of the sagittal and lambdoidal sutures is the lambda (figure 1-14), which indicates the position of the posterior fontanelle.

## 2-28. INDIVIDUAL FACIAL BONES

a. **Nasal Bones.** The nasal bones (figures 2-27, 2-28, and 2-29) are two small, oblong, flat bones that constitute the upper portion, or bridge, of the nose. The point at which they articulate with the frontal bone is called the nasion.

b. **Lacrimal Bones.** The lacrimal bones (figures 2-27 and 2-28) are two very thin, fragile bones situated at the front part of the medial walls of the orbits.

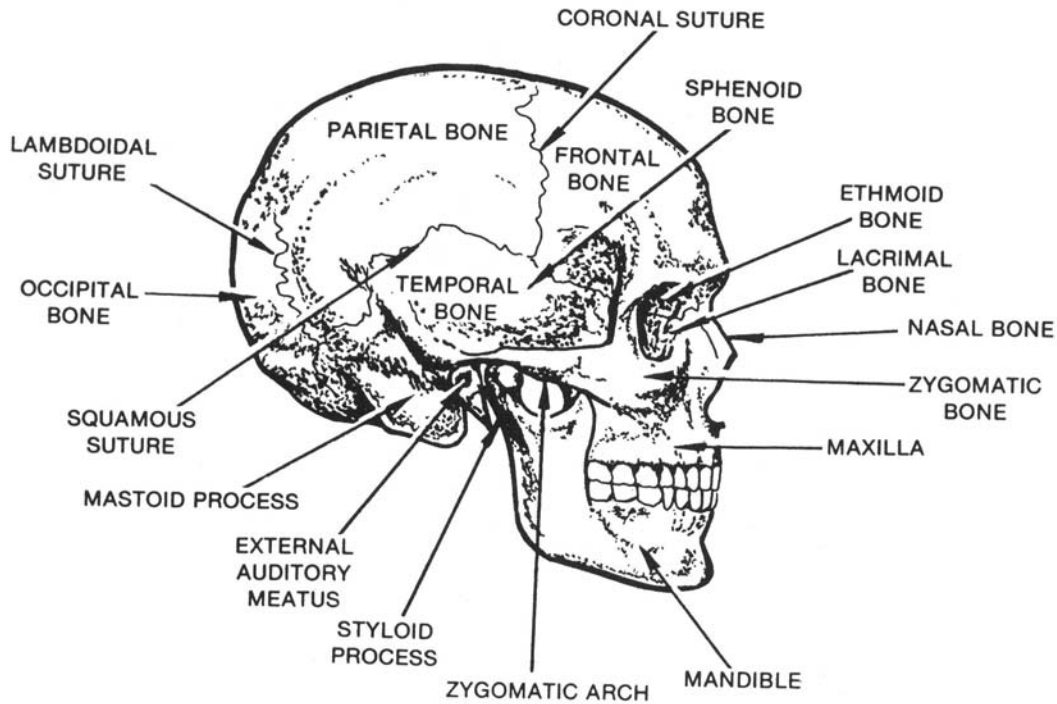


Figure 2-36. Suture joints of the skull (lateral aspect).

c. **Zygomatic Bones.** The two zygomatic, or malar bones (figures 2-27 and 2-28) form the prominence of the cheeks and contribute to the lateral walls and floor of the orbits. Each zygomatic bone has several processes: the frontal (which projects superiorly), the temporal (which projects posteriorly), and the maxillary (which projects anteriorly and medially).

d. **Maxillae.** The upper jaw is formed by the union of the two maxillary bones (figures 2-27, 2-28, 2-29, and 2-30). Each maxilla assists in forming the boundaries of the nasal cavity (the floor and lateral wall), the oral cavity (the roof), and the orbit (the floor). Each maxilla consists of a body and four processes: zygomatic, frontal, alveolar, and palatine.

(1) The body contains a large cavity, the maxillary sinus (figure 2-35) or antrum of Highmore. The anterior surface of the body is perforated by the infraorbital foramen, which transmits nerves and blood vessels. Medially and anteriorly, there is a sharp process that, with its fellow of the opposite side, constitutes the anterior nasal spine. The top of the body, the orbital surface, is a smooth, triangular surface that forms the greater part of the floor of the orbit. The nasal surface presents a large opening that leads into the maxillary sinus. The deep lacrima groove is situated in front of the sinus opening. This groove, along with the lacrimal bone, constitutes the canal that transmits the nasolacrimal duct. Tears from the lacrimal sac of the eye are drained through the nasolacrimal duct into the nasal cavity.

(2) The zygomatic process is a rough triangular eminence that joins the zygomatic bone. The frontal process projects superiorly from the body. It is connected to the frontal bone and one of the nasal bones. The alveolar process is a thick spongy ridge of bone that contains the cavities for the reception of the upper teeth. The palatine process (figure 2-30) forms a considerable portion of the floor of the nasal cavity and the roof of the mouth. When the two maxillae are joined together, the incisive foramen is seen on the midline at the anterior border of the palatine process.

e. **Palatine Bones.** The palatine bones (figure 2-30) are two L-shaped bones that contribute to the formation of the lateral wall of the nasal cavity and the roof of the mouth. Each palatine bone is divided into two parts, a perpendicular plate and a horizontal plate.

f. **Inferior Nasal Conchae.** The inferior nasal conchae (figure 2-27) are two scroll-shaped bones attached to the nasal surface of the body of the maxilla.

g. **Vomer.** The vomer (figure 2-28) is a flat bone that contributes to the formation of the nasal septum. It is situated on the midline and is joined posteriorly with the body of the sphenoid superiorly, with the perpendicular plate of the ethmoid, and, inferiorly, with the palatine processes of the maxillae and the horizontal plates of the palatine bones.

h. **Mandible.** The mandible, or lower jaw bone, (figures 2-27, 2-28, and 2-29) is the largest bone of the face. It consists of a curved, horizontal body and two perpendicular rami. The upper portion of each ramus (figure 2-29) is divided by a deep semilunar depression, the mandibular notch, and is surmounted by two processes, the coronoid and the condylar. The coronoid process is situated anterior to the mandibular notch, and the condylar process is situated posterior to the mandibular notch. The internal (medial) surface of the ramus presents the mandibular foramen. This foramen communicates with a mandibular canal that lies within the ramus and the body of the mandible. This canal accommodates blood vessels and nerves to the teeth. The junction of the posterior border of the mandibular body and the inferior border of the ramus marks the angle of the mandible. The anterior tip of the body is called the mental protuberance (chin). A mental foramen is situated on either side of the chin. Along the superior border of the body is the alveolar ridge, which includes depressions for the reception of the lower teeth.

## 2-29. HYOID

The hyoid bone is a horseshoe-shaped bone below the mandible and above the styloid processes of the temporal bone. It provides surfaces for the attachment of some of the tongue muscles.

## 2-30. THE TEMPOROMANDIBULAR JOINT

The temporomandibular articulation (joint) is formed by the condyle of the mandible and the mandibular fossa of the temporal bone. It is of the ginglymoarthrodial variety of joint.

## 2-31. ASPECTS OF THE SKULL

a. **Anterior Aspect.** When considered as a whole and viewed from the anterior or frontal aspect, the skull presents the following bony parts (figure 2-27). The forehead is formed by the squama of the frontal bone and exhibits two arched elevations (the superciliary arches). Beneath each superciliary arch is a curved and prominent margin, the supraorbital margin, in which is the supraorbital notch, or foramen. The supraorbital margins are joined medially to form the glabella. The zygomatic bone forms the prominence of the cheek. The infraorbital margin is formed by the zygomatic bone and the maxilla. The eyes are embedded in orbits. Each orbit is a pyramid-shaped cavity that has four walls, an apex, and a base that is formed by the supraorbital and infraorbital margins. The frontal and ethmoidal bones form the superior wall, or roof. The maxillary, zygomatic, and palatine bones form the inferior wall, or floor. The zygomatic and sphenoid bones form the lateral wall. The medial wall is formed by the maxillary, lacrimal, and sphenoid bones. At the apex of the orbit is the optic canal (a short, cylindrical canal that transmits the optic nerve and the ophthalmic artery). The inferior orbital fissure, which transmits nerves and blood vessels, is situated at the junction on the floor and the lateral wall of the orbit. At the junction of the roof and the lateral wall, near the apex of the orbit, is the supraorbital fissure, which transmits several nerves.

b. **Lateral Aspect.** The frontal, parietal, occipital, temporal, sphenoidal, ethmoidal, lacrimal, nasal, maxillary, zygomatic, and mandibular bones are partly visible in the lateral view of the skull (figure 2-29). The prominent zygomatic arch (figure 2-30), which is formed by the temporal process of the zygomatic bone and the zygomatic process of the temporal bone, should be noted. Posterior to the zygomatic process is the opening of the external acoustic (auditory) meatus (EAM) of the temporal bone. Posteroinferior to the external acoustic meatus is the mastoid process.

c. **Inferior Aspect.** The inferior, or basal, aspect of the skull (figure 2-30) presents the following bony parts, passing from the anterior to the posterior aspects. The palatine processes of the maxillae and the horizontal plates of the palatine bones form the hard palate, or roof, of the mouth. The bones that compose the hard palate fuse at the median palatine suture. The posterior portion of the vomer can be seen. The occipital bone, situated at the back and base of the skull, presents the foramen magnum, the squama, and the occipital condyles. Extending posteriorly and laterally from the foramen magnum, is a flat, expanded part named the squama, on which is the external occipital protuberance (EOP). The temporal bones are situated at the sides and base of the skull. The following structures of the temporal bones are visible. The apex of each mastoid tip is situated laterally. Anterior to the mastoid tip is the glenoid (or mandibular) fossa. The styloid process is anterior and medial to the mastoid tip. Extending anteromedially from the base of the styloid process to the basilar portion of the occipital bone is the petrous portion of the temporal bone.

## 2-32. INTERIOR OF THE CRANIAL CAVITY

The floor of the cranial cavity (figure 2-31) presents three fossae: the anterior, the middle, and the posterior cranial fossae.

a. **Anterior Cranial Fossa.** The floor of the anterior cranial fossa, which supports the frontal lobes of the brain, is formed by the frontal, ethmoid, and sphenoid bones. The lateral portions of the anterior fossa correspond to the roofs of the orbits. The medial portion corresponds to the roof of the nasal cavity.

b. **Middle Cranial Fossa.** The middle cranial fossa, which is deeper than the anterior fossa, consists of a central (or medial) portion and two lateral portions. Situated centrally is the body of the sphenoid. The lateral parts of the middle cranial fossa are of considerable depth and support the temporal lobes of the brain. They are bounded anteriorly by the posterior margins of the lesser wings of the sphenoid, and the orbital plates of the frontals. They are bounded posteriorly by the petrous portions of the temporals, and laterally by the squama of the temporals, the parietals, and the greater wings of the sphenoid.

c. **Posterior Cranial Fossa.** The dorsum sellae of the sphenoid bone and the petrous portions of the temporal bones separate the posterior cranial fossa from the middle cranial fossa. It is the largest and deepest of the three fossae and lodges the cerebellum, pons, and medulla oblongata.

## 2-33. THE NASAL CAVITY

The nasal cavity is divided into two nasal chambers by a thin, vertical wall, the nasal septum. The anterior portion of the septum is cartilage and the posterior portion is bone. The bony septum is formed anterosuperiorly by the perpendicular plate of the ethmoid bone and posteroinferiorly by the vomer. The maxilla and palatine bones form the floor. The four pairs of paranasal sinuses (figure 2-35) communicate with the nasal cavity. These sinuses are lined with ciliated mucous membrane and normally contain air. They are the sphenoidal sinuses, the ethmoidal sinuses, the maxillary sinuses, and the frontal sinuses. On the lateral wall, bounded above by the conchae (turbinate bones), are three irregular passages called the superior, middle, and inferior meatuses of the nose.

## 2-34. LANDMARKS AND PALPITATION POINTS OF THE SKULL

Landmarks and palpation points of the skull are shown in figures 2-33 and 2-34. You should study these carefully as they are very important in the work of the X-ray specialist.

[Continue with Exercises](#)

## EXERCISES, LESSON 2

**INSTRUCTIONS:** Answer the following exercises by marking the lettered response that best answers the exercise, by completing the incomplete statement, or by writing the answer in the space provided at the end of the exercise.

After you have completed all the exercises, turn to "Solutions to Exercises" at the end of the lesson and check your answers. For each exercise answered incorrectly, reread the material referenced with the solution.

1. From lateral to medial, the first of the proximal row of carpal bones is the:
  - a. Trapezium.
  - b. Hamate.
  - c. Scaphoid.
  - d. Pisiform.
  
2. Which bones of the upper extremities are in the wrist?
  - a. Phalanges.
  - b. Metacarpals.
  - c. Carpals.
  - d. Sesamoids.
  
3. The olecranon process is a part of which bone?
  - a. Clavicle.
  - b. Humerus.
  - c. Radius.
  - d. Ulna.



4. The three borders of the scapula are called: the superior border, the axillary border, and the \_\_\_\_\_ border.
  - a. Medial.
  - b. Posterior.
  - c. Supraspinous.
  - d. Vertebral.
  
5. The supraspinous fossa is located on which bone?
  - a. Clavicle.
  - b. Tibia.
  - c. Humerus.
  - d. Scapula.
  
6. The \_\_\_\_\_ is formed by the union of the auricular surfaces of the sacrum and the ilium.
  - a. Acetabulum.
  - b. Ankle mortise.
  - c. Symphysis pubis.
  - d. Sacroiliac joints.
  
7. The fossa located on the scapula that accommodates the head of the humerus is called the \_\_\_\_\_ fossa.
  - a. Supraspinous.
  - b. Glenoid.
  - c. Infraclavicular.
  - d. Infraspinous.

8. A bone often referred to as the collarbone should be called the:
- a. Clavicle.
  - b. Humerus.
  - c. Radius.
  - d. Scapula.
9. What is the name of the process of the scapula which articulates with the clavicle?
- a. Acromion.
  - b. Coracoid.
  - c. Coronoid.
  - d. Deltoid.
10. Excluding the sesamoid bones, the foot consists of \_\_\_\_\_ bones.
- a. 15.
  - b. 18.
  - c. 26.
  - d. 31.
11. Which of the bones of the foot forms the heel?
- a. Calcaneus.
  - b. Navicular.
  - c. Talus.
  - d. Fifth metatarsal.

12. The semicircular canals are located in the \_\_\_\_\_ part of the temporal bone.
- a. Squama.
  - b. Petrous.
  - c. Mastoid.
  - d. Tympanic.
13. The vertebra called the atlas is identified as:
- a. C-1.
  - b. C-2.
  - c. D-1.
  - d. L-1.
14. Which of the following refers to an opening between adjacent vertebrae through which the spinal nerves pass?
- a. Intervertebral foramen.
  - b. Vertebral arch.
  - c. Foramen magnum.
  - d. Intervertebral disk.
15. Which vertebra lies in the same transverse plane as the iliac crest?
- a. T-9.
  - b. L-1.
  - c. L-3.
  - d. L-4.

16. How many pairs of ribs normally articulate with the thoracic vertebrae?
- a. 9.
  - b. 10.
  - c. 11.
  - d. 12.
17. The three parts of the sternum are the manubrium, the body, and the:
- a. Xiphoid process.
  - b. Clavicle.
  - c. Costal cartilage.
  - d. Coracoid process.
18. The sternum is composed of how many osseous parts?
- a. 5.
  - b. 4.
  - c. 3.
  - d. 2.
19. Which ribs are free of any anterior attachment?
- a. The first through seventh ribs.
  - b. The first through tenth ribs.
  - c. The eighth through tenth ribs.
  - d. The eleventh and twelfth ribs.

20. Which part of the temporal bone contains the external acoustic meatus?
- a. Mastoid.
  - b. Petrous.
  - c. Squama.
  - d. Tympanic.
21. Which of the following bones houses the pituitary gland?
- a. Ethmoid.
  - b. Occipital.
  - c. Palatine.
  - d. Sphenoid.
22. The perpendicular plate of the ethmoid bone joins with the vomer to form part of the:
- a. Crista galli.
  - b. Ethmoid sinuses.
  - c. Middle nasal conchae.
  - d. Nasal septum.
23. Which process of the maxilla serves as a foundation for the upper teeth?
- a. Alveolar.
  - b. Frontal.
  - c. Palatine.
  - d. Zygomatic.

24. Which process of the mandible is part of the temporomandibular joint?
- a. Condylar.
  - b. Mastoid.
  - c. Coronoid.
  - d. Deltoid.
25. How many pairs of sinuses are found in the paranasal sinus group?
- a. 2.
  - b. 4.
  - c. 6.
  - d. 8.
26. The joints between the phalanges are called the:
- a. Metacarpal joints.
  - b. Carpometacarpal joints.
  - c. Interphalangeal joints.
  - d. Intermetacarpal joints.

**Check Your Answers on Next Page**

## **SOLUTION TO EXERCISES: LESSON 1**

1. c (para 2-1b, figure 2-1)
2. a (para 2-1d; figures 2-1, 2-8)
3. d (para 2-2a; 2-2)
4. d (para 2-4b(3))
5. d (para 2-4b(2); figure 2-6)
6. d (para 2-14a)
7. b (paras 2-4b(4)(c); 2-6a)
8. a (para 2-4c)
9. a (para 2-5b; figure 2-8)
10. c (para 2-9d; figure 2-11)
11. a (para 2-10a(1); figure 2-11)
12. b (para 2-27c(4))
13. a. (para 2-16c)
14. a (para 2-18b(4))
15. d (figure 2-22)
16. d (paras 2-22; and 2-24)
17. a (para 2-23a)
18. b (para 2-12a(2))
19. d (para 2-24a; figure 2-23)
20. d (para 2-27c(3))
21. d (para 2-27e(1); figure 2-31)

- 22. d (para 2-27f(2); figure 2-28)
- 23. a (para 2-28d(2))
- 24. a (para 2-30)
- 25. b (para 2-33; figure 2-33)
- 26. c (para 2-7e)

**End of Lesson 2**



## **LESSON ASSIGNMENT**

### **LESSON 3**

Body Systems Other Than Skeletal.

### **LESSON ASSIGNMENT**

Paragraphs 3-1 through 3-57.

### **LESSON OBJECTIVES**

After completing this lesson, you should be able to:

- 3-1. Select correct answers to questions about the nonskeletal systems, organs, and structures, especially those that are important in radiology.

### **SUGGESTION**

After completing the assignment, complete the exercises of this lesson. These exercises will help you to achieve the lesson objectives.

## LESSON 3

### BODY SYSTEMS OTHER THAN SKELETAL

#### Section I. THE DIGESTIVE SYSTEM

##### 3-1. GENERAL

a. The digestive system receives complex food compounds and, by mechanical and chemical action, splits these compounds into simple molecules that diffuse through the wall of the intestine into the bloodstream. The mechanical forces involved are mastication (chewing), local rhythmical movements, and peristalsis (waves of contraction). The chemical action is very complex. Enzymes (organic compounds that aid chemical reactions without themselves being utilized) play an outstanding role in digestion. Certain acids and salts also play vital roles.

b. The digestive system (figure 3-1) consists of the alimentary tract or canal which extends from the mouth to the anus and the accessory organs of digestion: the liver, gallbladder, pancreas, and salivary glands. The alimentary tract consists of the mouth, pharynx, esophagus, stomach, small intestine, large intestine, rectum, and anus.

##### 3-2. THE MOUTH

The mouth, in which the food is masticated and mixed with saliva into a bolus, is the first division of the alimentary tract. It is divided into the vestibule and the oral cavity. The vestibule is the space between the teeth and the mucous membrane of the cheeks and the lips. The oral cavity (figure 3-2) lies within the dental arches and below the palate. Portions of the maxillary and palatine bones form the hard palate. The soft palate is a movable fold attached to the back of the hard palate and the sides of the mouth. In swallowing, the soft palate is raised, isolating the nasopharynx.

##### 3-3. THE TONGUE

The tongue is a freely movable muscular organ intimately associated with the functions of taste, speech, mastication, salivation, and deglutition (swallowing). It is in the floor of the oral cavity (figure 3-2) with its base directed backward and its apex forward.

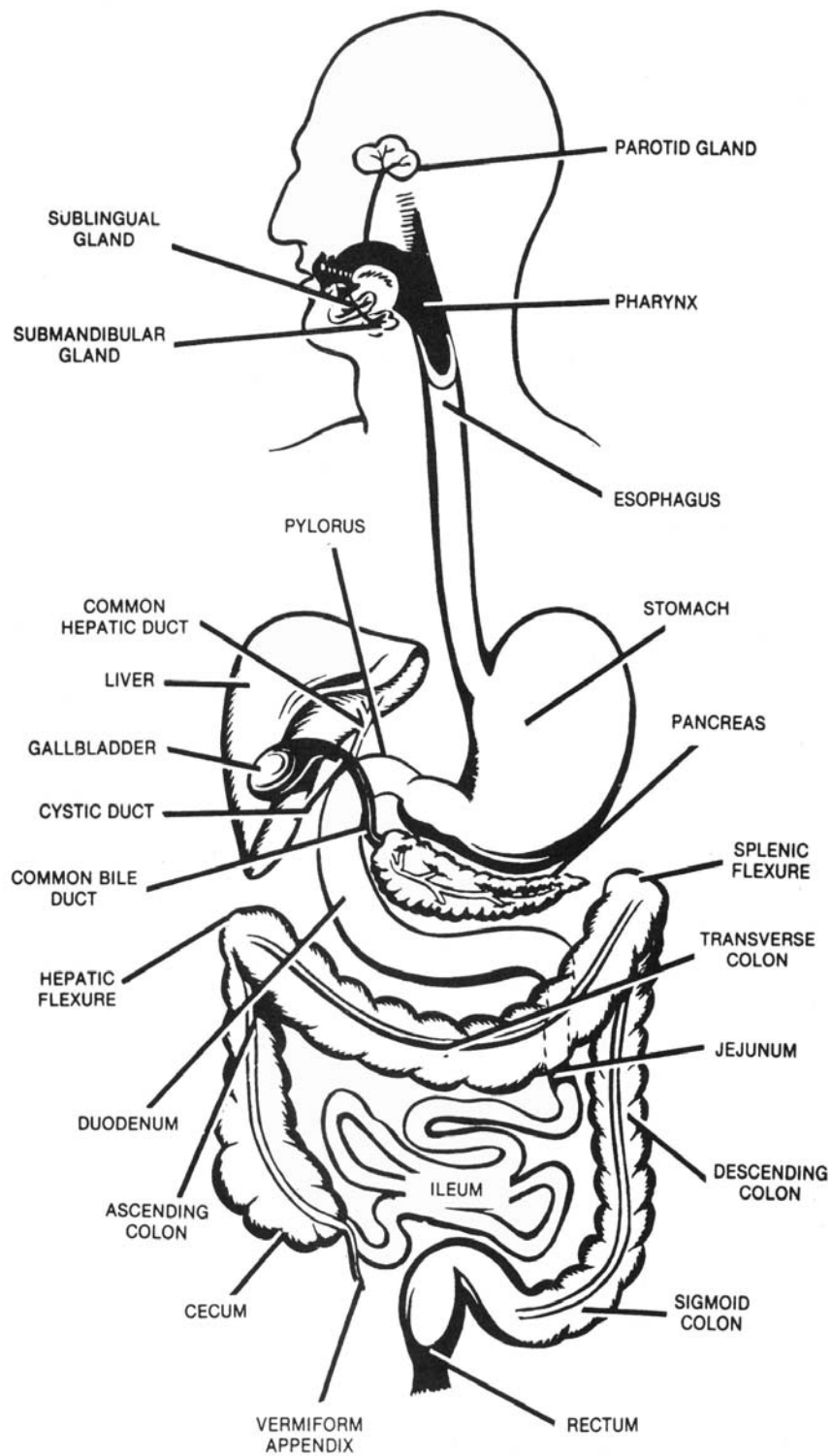


Figure 3-1. The alimentary tract and accessory organs of digestion.

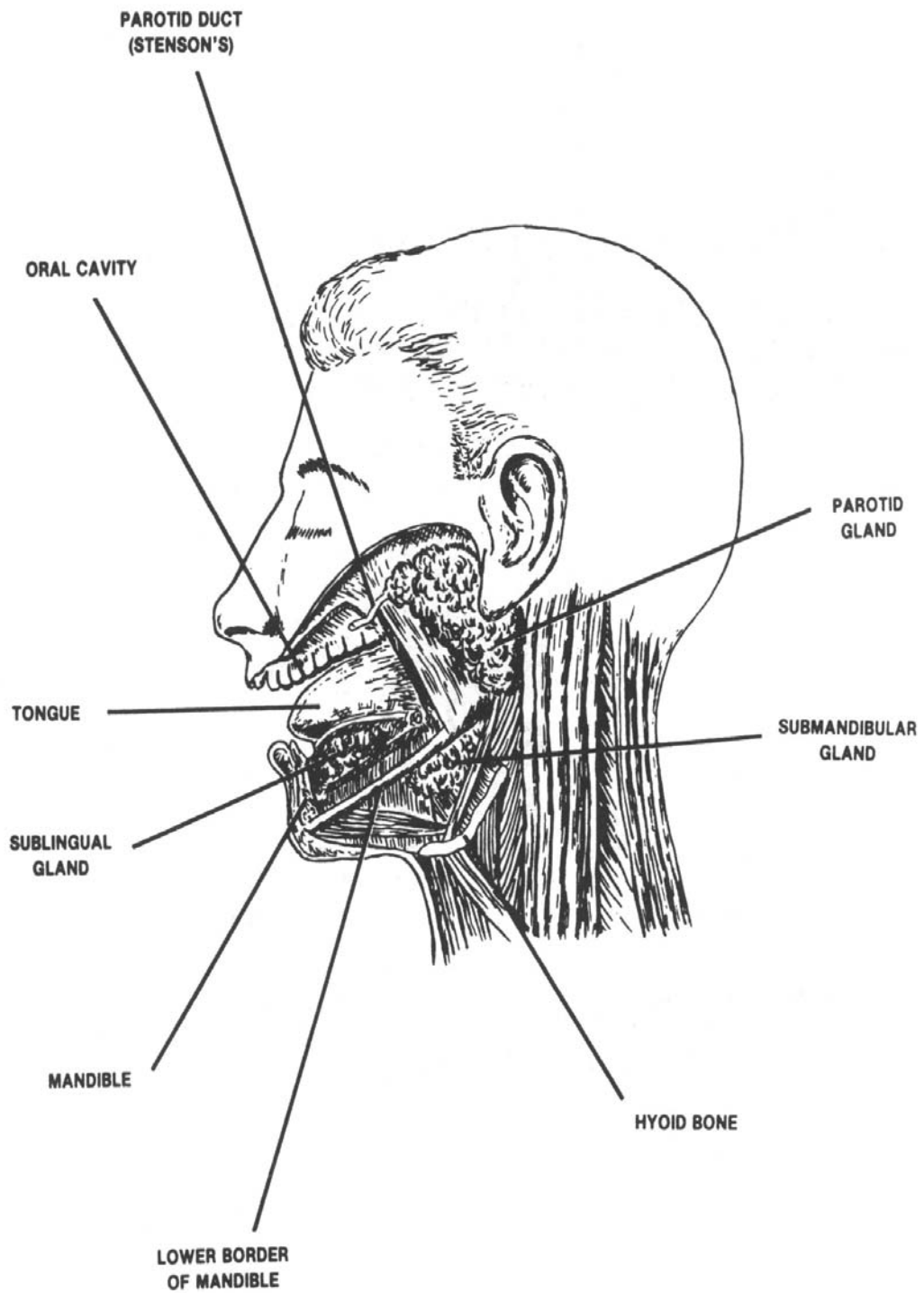


Figure 3-2. The oral cavity showing the salivary glands and ducts of the left side.

### 3-4. THE SALIVARY GLANDS

a. **General.** There are three primary pairs of salivary glands, the submandibular, the sublingual, and the parotid, as well as numerous other glands in the mucous membrane of the oral cavity. All of these glands contribute to the formation of saliva.

(1) The parotid glands are irregular, lobated salivary glands located in front of each ear. By means of Stensen's duct, the serous secretions of the parotid gland are channeled through the muscles of the cheek into the mouth by way of small papillae adjacent to the second upper molar tooth.

(2) The submandibular glands, irregular in form and shaped like walnuts, lie close to the internal surface of each half of the mandible. They send saliva into the mouth by way of Wharton's duct through a small orifice at the side of the frenulum of the tongue.

(3) The sublingual glands are the smallest of the three pairs of salivary glands. They lie just anterior to the base of the tongue and empty directly into the oral cavity by means of many ducts, the ducts of Rivinus.

b. **Content and Functions of the Saliva.** The quantity of saliva secreted daily is about 1,200 milliliters (ml). It contains mucin, serous fluid, mineral salts, and an enzyme called ptyalin. During the chewing of food, saliva moistens, softens, and lubricates the bolus of food so the act of swallowing is facilitated. Some digestion of starches occurs in the mouth, and the ptyalin from the saliva continues to work in the stomach for some 30 to 50 minutes.

### 3-5. THE TEETH

The teeth are the organs of mastication. The permanent teeth are 32 in number: four incisors, two canines, four premolars, and six molars in each jaw (figure 3-3). Each tooth consists of a crown, neck, and root.

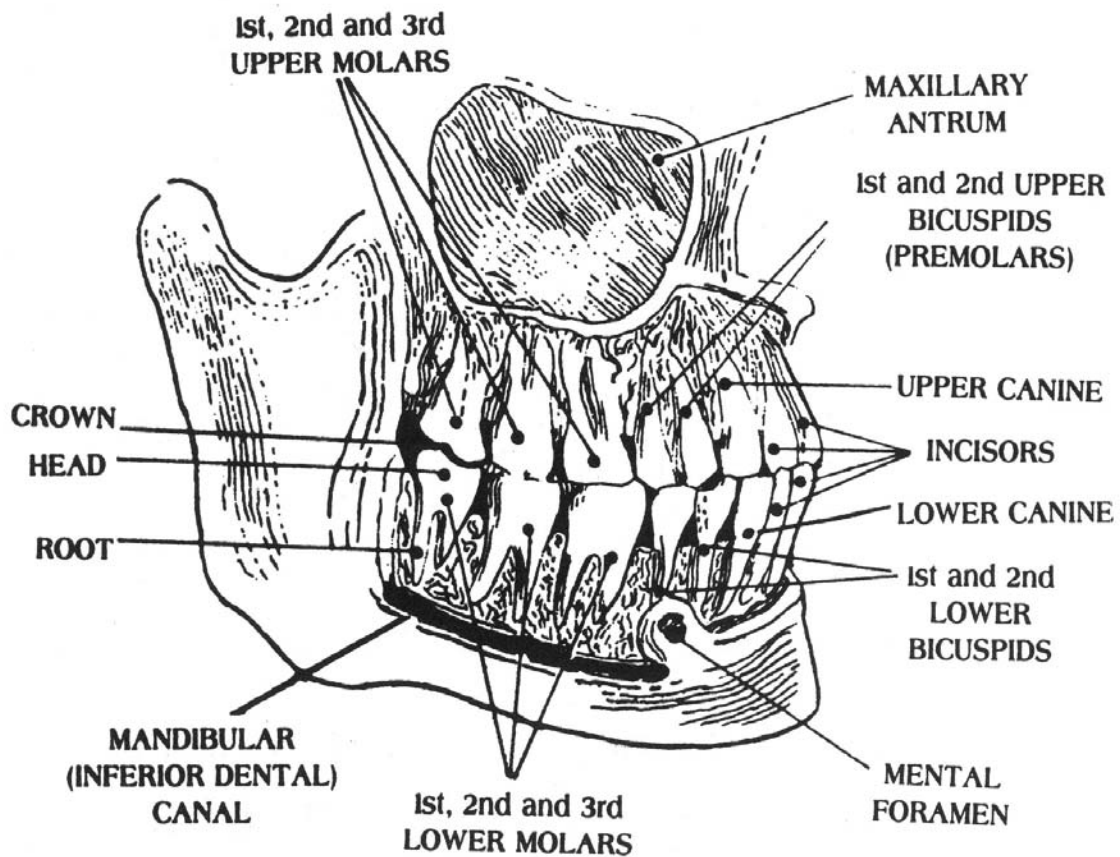


Figure 3-3. The permanent teeth.

### 3-6. THE PHARYNX

The pharynx lies behind the nasal cavities, mouth, and larynx and extends into the esophagus. The cavity of the pharynx may be subdivided, from above downward, into three parts: nasal, oral, and laryngeal.

a. The nasopharynx (nasal) extends upward from the soft palate and is an air passage.

b. The oropharynx (oral) reaches from the level of the soft palate (level of the body of the axis) to that of the hyoid bone. It is a common passage for air and food.

c. The laryngopharynx (laryngeal) extends from the level of the hyoid bone to that of the lower border of the cricoid cartilage opposite the sixth cervical vertebra. It lies posterior to the larynx and opens into the esophagus.

### 3-7. THE ESOPHAGUS

The esophagus is a musculomembranous tube about 10 inches in length that extends from the pharynx to the stomach (figure 3-1). It begins at the lower border of the cricoid cartilage opposite the sixth cervical vertebra; descends in front of the vertebral column; passes through the diaphragm at the level of the tenth thoracic vertebra; and terminates at the cardiac orifice of the stomach opposite the eleventh thoracic vertebra. The area where the esophagus traverses the diaphragm is called a hiatus. A hiatal hernia is formed when any structure (usually a part of the stomach) protrudes through the hiatus.

### 3-8. THE STOMACH

#### a. Description

(1) The stomach is the most dilated part of the digestive tube, extending between the end of the esophagus and the beginning of the small intestine (figures 3-2 and 3-4). It lies within the epigastric, umbilical, and left hypochondriac regions of the abdomen (figure 1-7) with a small portion of the greater curvature extending into the left lumbar region. The size, shape, and position of the stomach depend upon bodily habitus (type) and vary with content and posture.

(2) There are two openings in the stomach. The upper opening at the juncture of the esophagus is the cardiac orifice. The cardiac orifice is at the level of the seventh left costal cartilage about 1 inch from the side of the sternum (the level of the tenth thoracic vertebra). The lower opening that communicates with the duodenum is the pyloric orifice. The pyloric orifice lies about 1 inch to the right of the midline at the level of the upper border of the first lumbar vertebra (the level of the upper horizontal line) (figure 2-22).

(3) The stomach has two borders, or curvatures. The lesser curvature extends between the cardiac and pyloric orifices forming the concave border of the stomach. The greater curvature forms the lower convex border of the stomach (figure 3-4).

(4) The stomach is divided into three parts: the upper part or fundus, the middle part or body, and the lower part or pylorus. The fundus is the dome-shaped portion lying directly beneath the dome of the diaphragm and above the cardiac orifice. The fundus is marked off from the body by a plane of demarcation passing horizontally through the cardiac orifice. The lower (smaller) end of the stomach, the pyloric portion, is marked off from the body by a plane of demarcation passing through the angular notch of the lesser curvature to the opposite dilation of the greater curvature.

b. **Function of the Stomach.** The stomach, by mechanical (contractions and peristalsis) and chemical action, plays an important part in digestion. Gastric juice contains hydrochloric acid and several enzymes. The acid attacks proteins, which swell to a gelatinous mass. Pepsin converts proteins to proteoses and peptones. Gastric lipase hydrolyzes finely divided fats (as in egg yolk) to fatty acids and glycerine. The food is reduced to a thin liquid mass (chyme). At intervals, the relaxation of the pyloric sphincter allows chyme to enter the duodenum. The time required for gastric digestion averages about 5 to 7 hours for a meal.

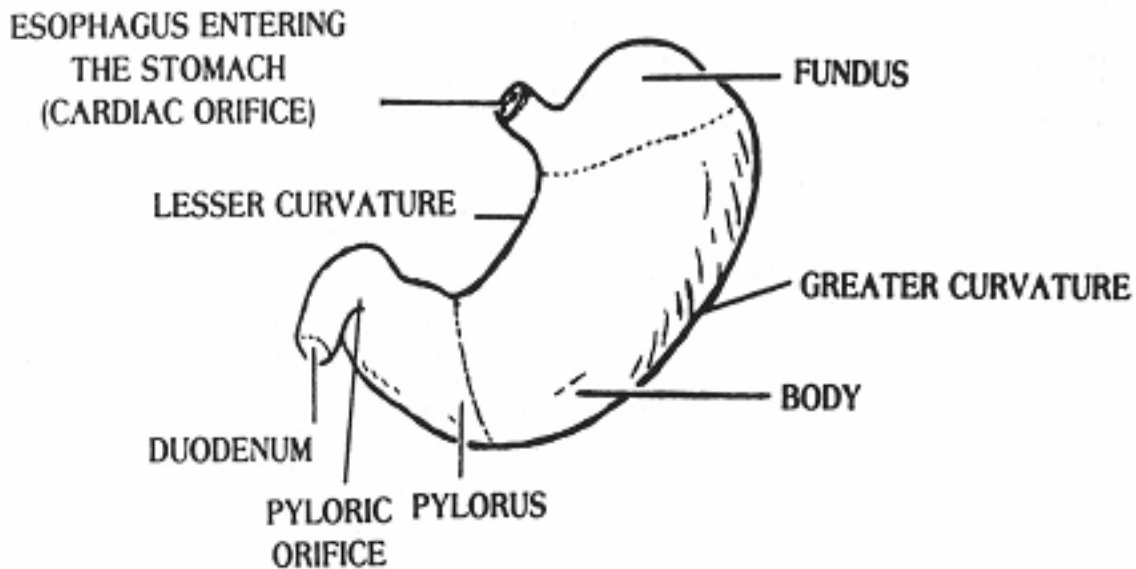


Figure 3-4. Anterior aspect of the stomach.

### 3-9. THE SMALL INTESTINE

The small intestine extends from the pylorus to the ileocecal valve where it joins the large intestine. It is divided into the duodenum, the jejunum, and the ileum (figure 3-1). The small intestine is a primary site of both digestion and absorption.

a. The duodenum is the shortest part (8 to 10 inches) of the small intestine. It begins at the termination of the pylorus and unites with the jejunum at the duodenojejunal flexure. It is a C-shaped organ in the umbilical region of the abdomen, extending from the level of the first lumbar vertebra to that of the fourth lumbar vertebra. The first portion of the duodenum, the duodenal bulb or cap, is often the site of duodenal ulcers. The accessory organs (liver and pancreas) of the digestive system have a common opening into the duodenum (figure 3-5), adding their secretions to the stomach juices that also continue to work in the duodenum.

b. The jejunum is the second portion of the small intestine. It extends from the duodenojejunal flexure to the ileum. The jejunum is about 7-1/2 feet long and constitutes about two-fifths of the small intestine.



c. The ileum is the third, or distal, portion of the small intestine. It is about 16 feet in length and constitutes about three-fifths of the small intestine. It begins at the distal end of the jejunum and terminates at the ileocecal valve, which guards the opening between the ileum and the proximal portion of the large intestine. The ileum and the jejunum are coiled throughout the central and lower portions of the abdominal cavity.

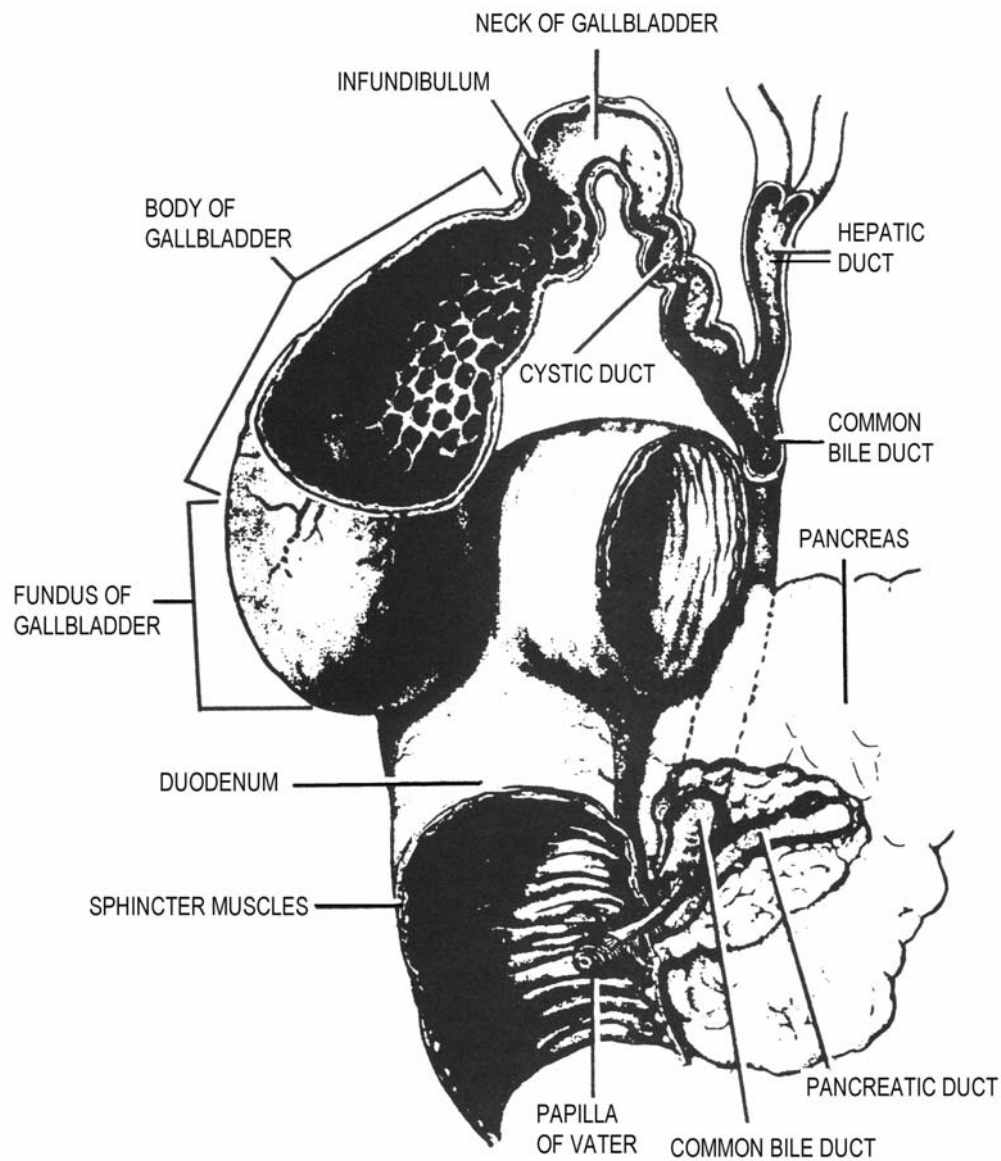


Figure 3-5. The duodenum in relation to the accessory organs of digestion.

### 3-10. THE LARGE INTESTINE

The large intestine is about 5 feet long and extends from the end of the ileum to the anus. It is divided into the cecum, colon, rectum, and anal canal (figure 3-1). At the beginning of the large intestine, the food is moved slowly and some undigested materials are digested (by enzymes carried over from the small intestine) and absorbed. The main function of the large intestine is to absorb water from the residue.

a. The cecum, the commencement of the large intestine, is a large, blind pouch in the right iliac fossa. A worm-shaped tube, the appendix or vermiform process, is attached to the lower end of the cecum on the posteromedial aspect. The distal end of the ileum communicates with the cecum by way of the ileocecal valve.

b. The colon, although one continuous tube, is subdivided into ascending, transverse, descending, and sigmoid parts.

(1) The ascending colon begins at the cecum opposite the ileocecal valve and passes upward to the lower surface of the right lobe of the liver, where it bends abruptly forward and to the left forming the right colic, or hepatic, flexure.

(2) Beginning at the hepatic flexure, the transverse colon passes with a downward convexity across the abdomen into the left hypochondriac region of the abdomen, where it bends abruptly on itself beneath the lower end of the spleen to form the splenic flexure.

(3) From its beginning at the splenic flexure (left colic), the descending colon passes down the left side of the abdomen to its junction with the sigmoid colon.

(4) The sigmoid colon begins at the terminus of the descending colon. It forms an S-shaped loop and normally lies within the pelvis. It passes across the front of the sacrum to the right side of the pelvis; it then curves on itself and follows a leftward course to the midline at the level of the third sacral segment, where it bends downward and ends in the rectum.

(5) The rectum extends downward to the anal canal. It is continuous with the sigmoid colon and anal canal. The rectum is about 4-1/2 inches (12 cm) long and, at its distal end, it is dilated to form the rectal ampulla.

c. The anal canal is the terminal portion of the large intestine and measures from 2.5 to 4 centimeters in length. It extends from the distal end of the rectum and terminates in the external opening of the alimentary tract, the anus (figure 3-1).

### 3-11. THE ACCESSORY ORGANS OF DIGESTION

The accessory organs of digestion are the liver, the gallbladder, and the pancreas (figures 3-1 and 3-5).

a. **The Liver.** The liver is the largest gland in the body, weighing ordinarily from 3 to 4 pounds in men and somewhat less in women. Its consistency is like that of a wet sponge and its color is dark reddish brown. The liver is divided into a right lobe and a smaller left lobe. It is in the upper right quadrant of the abdominal cavity and lies immediately beneath the diaphragm. It occupies almost the whole of the right hypo-chondrium and the greater part of the epigastrium; it frequently extends into the left hypochondriac region (figure 1-7). Two tubes of nearly equal size issue from the right and left lobes of the liver. These two tubes unite to form the common hepatic duct. The principal condition for which the liver may be examined radiographically is hepatic enlargement.

#### b. The Gallbladder.

(1) The gallbladder is a pear-shaped musculomembranous sac situated on the undersurface of the right lobe of the liver. It is about 3 to 4 inches in length and about 1-1/2 inches in diameter at its largest part. It serves as a reservoir for bile, accommodating about 30 to 35 milliliters of concentrated bile. The gallbladder is divided into a fundus, a neck, and a body. The fundus of the gallbladder normally is situated under the right lobe of the liver at the end of the right ninth costal cartilage near the junction of the right vertical and upper horizontal lines (figure 1-9). The cystic duct runs backward and downward from the neck of the gallbladder and joins the common hepatic duct to form the common bile duct. The cystic duct is about 1-1/2 inches long and contains a system of valves within its lumen, called the "spiral valve of Heister." The common bile duct is about 3 inches long and communicates with the duodenum by way of the ampulla of Vater and the sphincter of Oddi.

(2) The position of the gallbladder varies with the type of body habitus and tends to shift with changes in posture and with the stages of respiration.

c. **The Pancreas.** The pancreas is an elongated gland in the epigastric and left hypochondriac regions of the abdomen. The head of the pancreas is lodged within the curve of the duodenum. The secretion of the pancreas is carried by the pancreatic duct into the duodenum (figure 3-5).

### **3-12. FUNCTIONS OF THE ACCESSORY ORGANS OF DIGESTION AND THE SMALL INTESTINE**

The liver, the gallbladder, the pancreas, and the small intestine play closely interrelated roles in the digestion and absorption of food.

a. The liver secretes about 650 milliliters of bile per day. The hepatic duct carries the bile (between meals) to the gallbladder. There, the bile is concentrated (by removal of water) so that each 10 milliliters of bile secreted by the liver is reduced to about 1 milliliter. When chyme containing fats enters the duodenum, the gallbladder contracts and the bile is emptied into the duodenum by way of the cystic and common bile ducts. Pancreatic juice (which contains several enzymes that facilitate the break down of undigested proteins, carbohydrates, and fats) enters the duodenum simultaneously with the bile. Bile emulsifies fats and the pancreatic lipase splits them into fatty acids and glycerol.

b. In the jejunum and ileum, the intestinal juice completes the hydrolysis of carbohydrates to simple sugars and of proteolytic products to amino acids. Sugar metabolism provides muscular energy and the amino acids are chiefly rebuilt into proteins for the maintenance of cells. Neutral fat is absorbed and stored until needed.

c. In addition to excreting bile, the liver assists in removing disintegration products of hemoglobin (bile pigments) from the plasma. The liver also receives the products of digestion after absorption and converts them into other substances. It converts glucose to glycogen, which it stores; removes nitrogen from amino acids; and forms fibrinogen and heparin, which function in the clotting of the blood.

d. The pancreas contains cells that make insulin, which is secreted directly into the bloodstream. Insulin is a hormone essential for glucose metabolism.

## **Section II. THE UROGENITAL SYSTEM**

### **3-13. GENERAL**

The urogenital system (figures 3-8 and 3-9) consists of the urinary organs for the production and elimination of urine and the genital organs, which are concerned with reproduction. The urinary system removes waste products of metabolism from the blood. In the average man, the kidneys clear about 1,300 milliliters of blood per minute; therefore, in approximately 5 minutes, all of the blood is circulated through the kidneys. In addition to filtering the waste products from the bloodstream, the kidneys also help to maintain the alkaline and acid balance of the blood and the required level of body fluids.

### 3-14. THE KIDNEYS

a. **Location and Position.** The kidneys are paired organs in the upper posterior part of the abdominal cavity, one on either side of the vertebral column, behind the peritoneum. The upper extremity, or pole, of each kidney is, approximately, at the level of the upper border of the twelfth thoracic vertebra. The lower extremity, or pole, is at the level of the third lumbar vertebra. Generally, the right kidney is slightly (about 1/2 inch) lower than the left. Since the kidneys are not rigidly fixed to the abdominal wall, they move up and down during respiration and normally drop about 1-1/2 inches when the person changes from supine to the erect position.

b. **Structure.**

(1) The kidneys have a characteristic bean-shaped form, their lateral borders being convex and their medial borders concave. Their anterior and posterior surfaces are slightly convex. Near the center of the concave medial border is a depression (the hilum) that marks the entrance of the vessels and nerves and the emergence of the ureters. Each kidney is about 11 centimeters in length, 5.5 centimeters in width, and 3.5 centimeters in thickness (in the average adult male). Contiguous with the kidney tissue is a mass of fatty tissue, the adipose capsule, which is comparatively radiolucent.

(2) On the longitudinal section, the kidney consists of a cortex or external part, a medulla or internal portion, and the renal pelvis (figure 3-6).

(a) The cortical substance is reddish brown in color and is composed of the glomeruli and Bowman's capsule, forming the nephrons (the functional units of the kidney, figure 3-7). There are over 3/4 million of these units in each kidney. The glomerulus is a tuft of capillaries surrounded by a capsule that acts as a filter to keep the large molecules of proteins, etc., from entering the convoluted tubules, but allows water, urea, salts, and excess sugars to enter. The efferent artery leaving the glomerulus breaks up into a plexus surrounding the convoluted tubules. About 99 percent of the water is reabsorbed and the waste products enter the collecting tubes as urine.

(b) The medullary substance consists of thousands of collecting tubes that converge to form a series of conical masses, the renal pyramids. The bases of the pyramids are directed toward the cortex of the kidney while the apices converge toward the center.

(c) The hilum expands internally into a dome-shaped central cavity, called the renal sinus. The calyces and the renal pelvis are situated within the sinus.

(d) The minor renal calyces unite to form two to five short channels, the major renal calyces, and these, in turn, combine to form the renal pelvis. At the apex of the renal pyramids, the urine is first emptied into the minor calyces; it then flows into the major calyces and on into the renal pelvis.

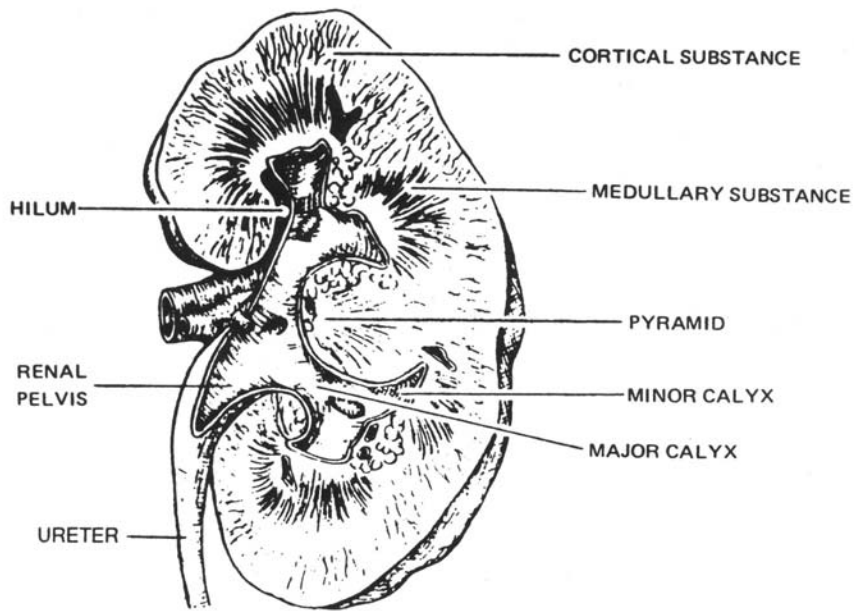


Figure 3-6. A kidney, longitudinal section, showing gross anatomy.

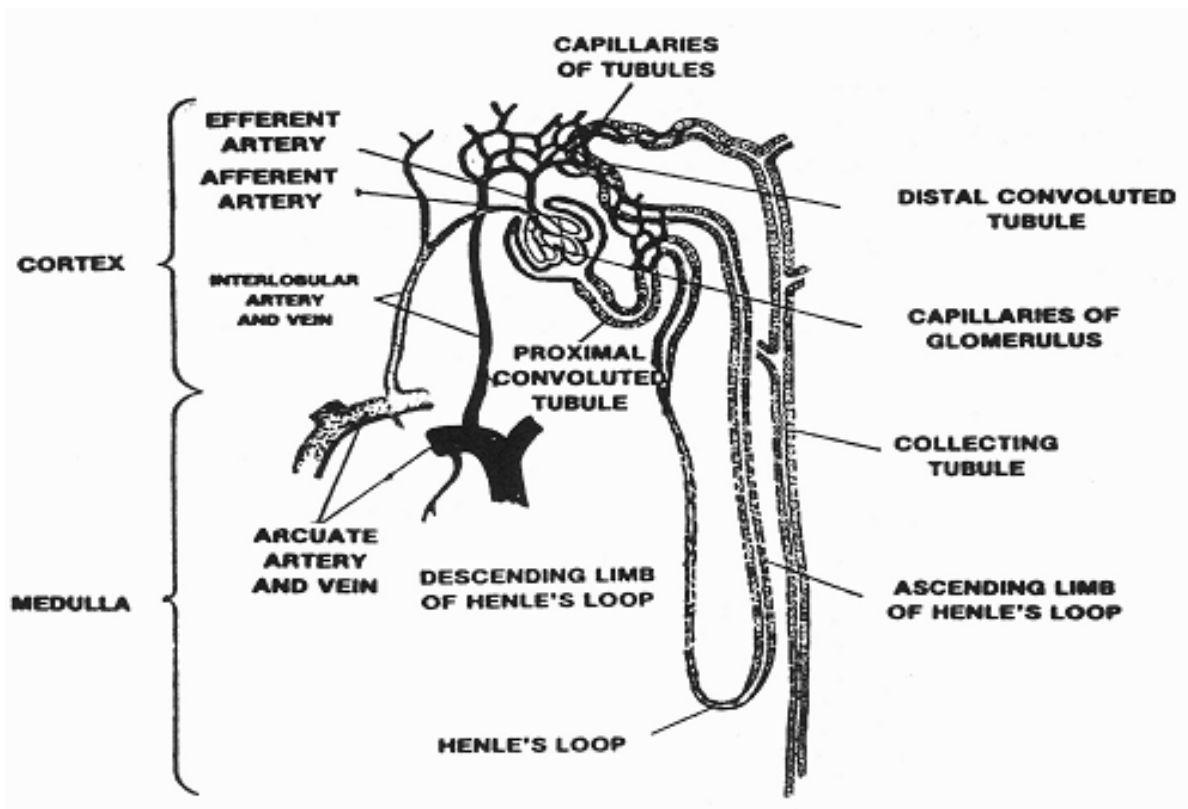


Figure 3-7. Principal components of the nephron.

(e) The renal pelvis is a cuplike cavity for the collection of urine that empties into a ureter. As the pelvis extends from the kidney, it tapers into a funnel-like convolution and then imperceptibly into the ureter.

c. **Function.** The kidneys eliminate the nitrogenous waste products of metabolism and help maintain the constant chemical composition of the blood. They excrete from about 1,000 to 1,800 cubic centimeters of urine in 24 hours. The glomeruli and the tubules of the nephrons perform different functions in the production of urine.

(1) The glomeruli act as filters. Dissolved substances and water pass through the capillary walls into the capsule. Blood pressure provides the force necessary for filtration.

(2) The tubules transform the filtrate into urine. Tissue examination of the tubules shows a great diversity of structure of the epithelium which lines them. It is quite conceivable that some portions of the tubules absorb certain substances from the filtrate while others secrete. The chemical and water constituents of the blood are kept at a constant level by the functioning of the tubules. Radiopaque organic iodine compounds, when injected intravenously, are normally excreted by the tubules with the urine.

### **3-15. THE URETERS**

The ureters are the two tubes which carry urine from the kidneys to the urinary bladder (figure 3-8). Their upper portions are continuous with the renal pelvis. The ureter proper is from 24 to 30 centimeters (10 to 12 inches) in length and varies in caliber from about 1 centimeter proximally to 1 millimeter at the entrance of the urinary bladder. Extending from its corresponding kidney, each ureter passes downward, one on either side of the vertebral column, behind the peritoneum, to the pelvic brim. After crossing the pelvic brim, the ureter passes along the lateral wall of the pelvic cavity and curves downward, forward, and inward along the floor of the pelvic cavity, entering the posterior portion of the urinary bladder. The wall of each ureter consists of an inner mucous coat, a layer of muscles, and an outer fibrous coat.

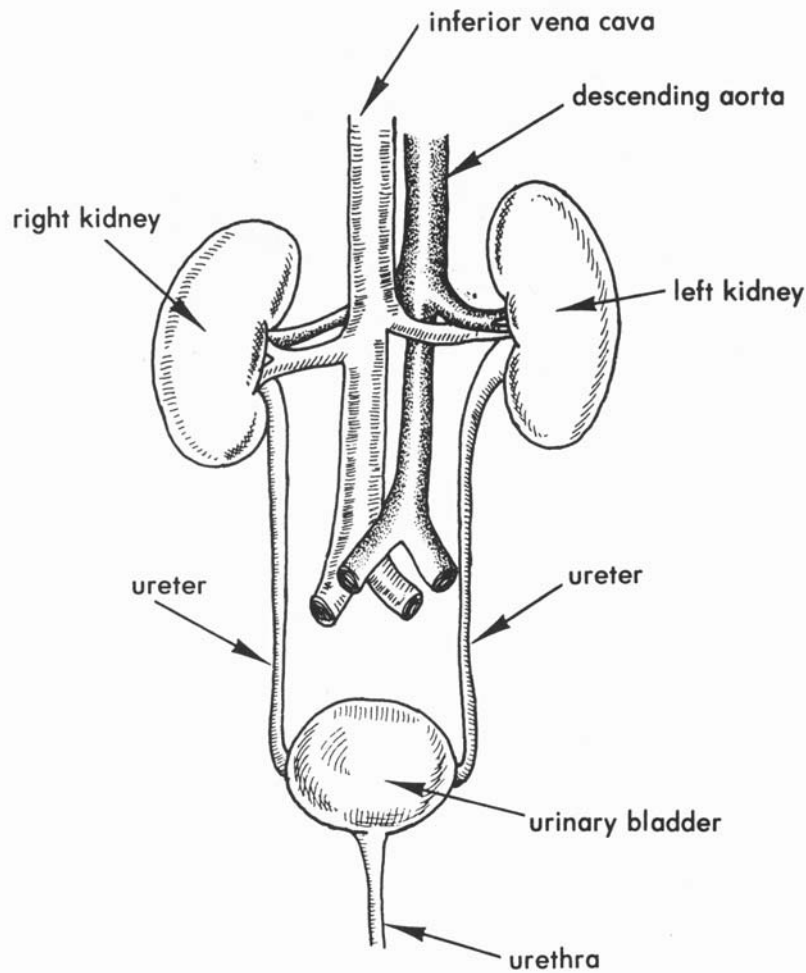


Figure 3-8. Urinary organs in relation to some of the adjacent structures (anterior aspect).

### 3-16. THE URINARY BLADDER

a. The urinary bladder is a musculomembranous sac-like organ that acts as a reservoir for the reception and storage of urine. It is in the pelvic cavity behind the pubis, in front of the rectum in the male (figure 3-9). In the female, the bladder lies in front of the anterior wall of the vagina and the neck of the uterus (figure 3-12b). When empty, it lies deeply within the pelvis; when slightly distended, it has a round form; and when greatly distended with urine, it is ovoid in shape and the fundus rises above the symphysis pubis.



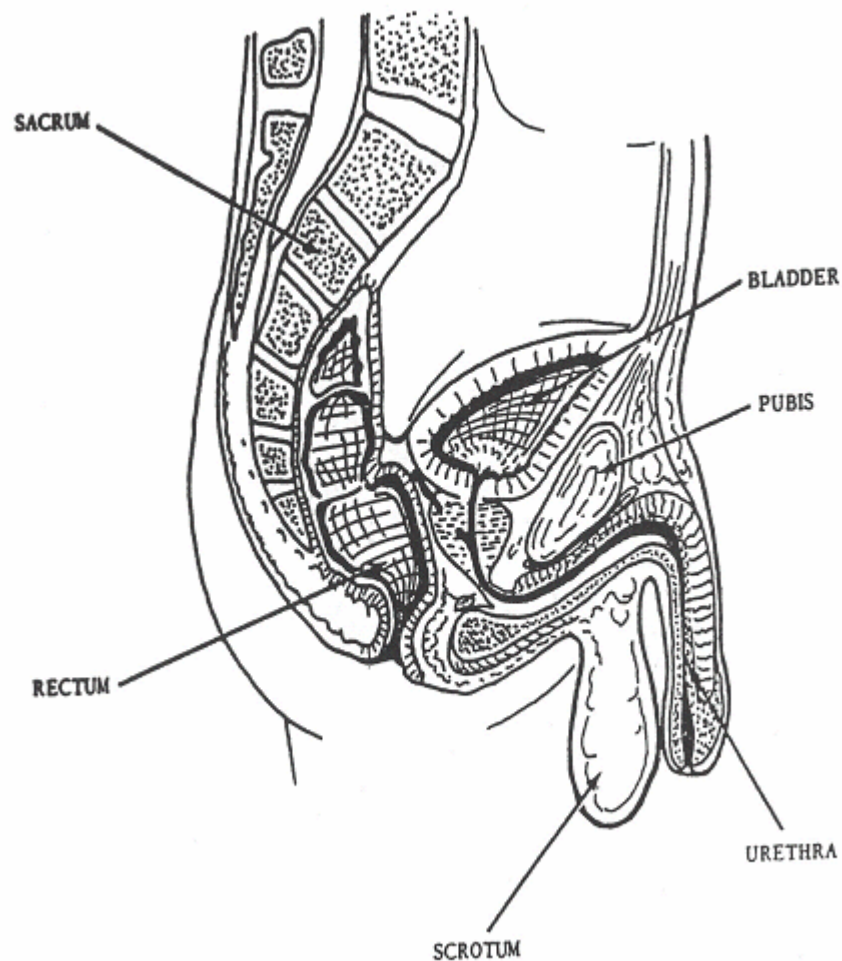


Figure 3-9. Sagittal section through the male pelvis showing the urinary bladder in relation to surrounding structures.

b. The function of the urinary bladder is to store the urine until a large enough quantity is collected to excite the nerve impulses that will cause a relaxation of the sphincter muscles surrounding the urethral opening and thus allow the contents of the bladder to be emptied. In the infant, this action occurs involuntarily, but control of urination comes with training. The urine escapes from the bladder by way of the internal urethral orifice.

### 3-17. THE URETHRA

The urethra is a membranous canal by which urine is conveyed from the bladder to the outside (figures 3-9 and 3-10).

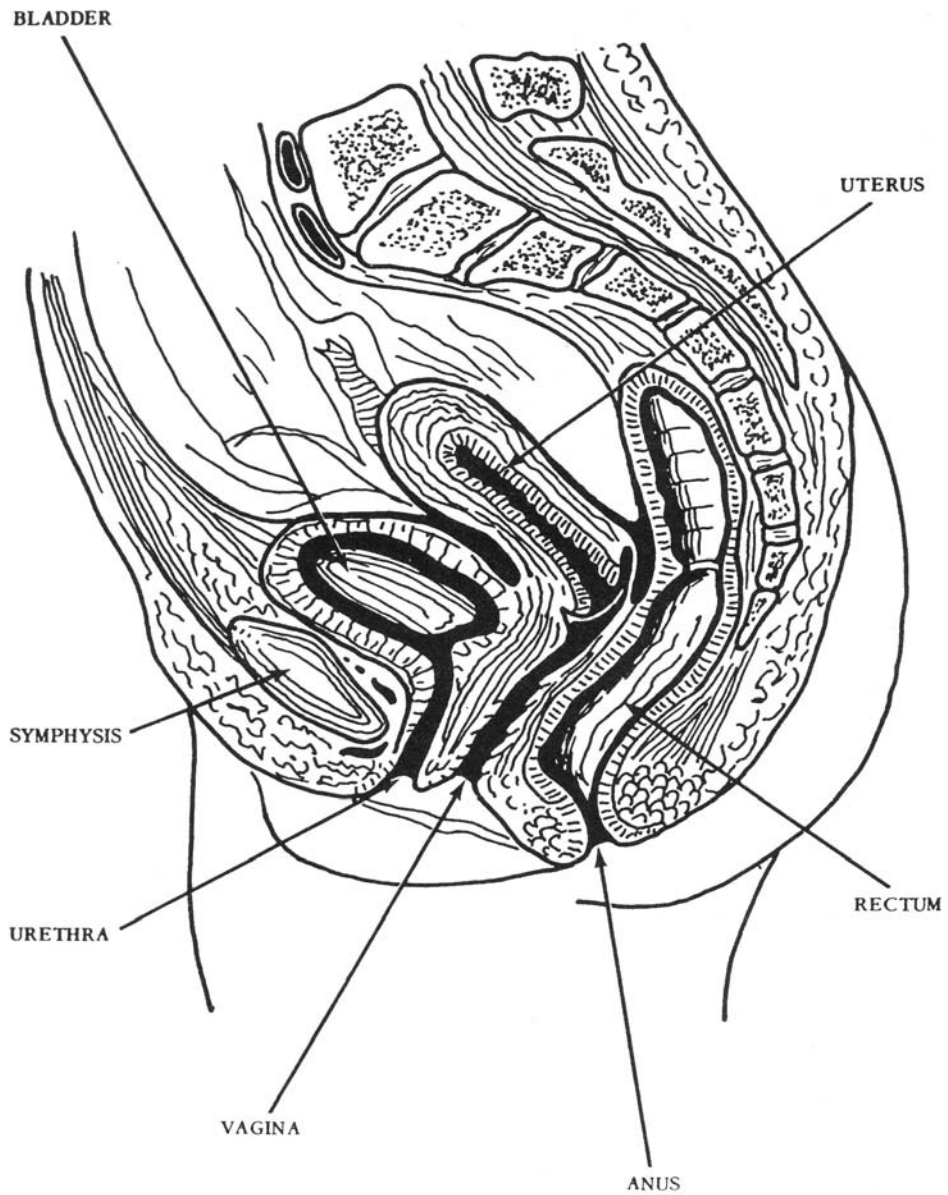


Figure 3-10. Sagittal section through the female pelvis showing the urinary bladder in relation to the surrounding structures.

a. The male urethra, from 18 to 20 centimeters long, is common to both the urinary and reproductive systems. It extends from the urethral orifice in the bladder to the external urethral orifice at the tip of the penis and consists of three portions.

(1) The prostatic urethra, about 3 centimeters long, extends from the urethral orifice in the bladder through the prostate gland. During coitus, secretions enter this part from the prostate gland and also from the ejaculatory duct.

(2) The membranous urethra, about 2 centimeters long, extends from the apex of the prostate to the bulb of the penis and perforates the perineal membrane, about 2.5 centimeters inferior to the symphysis pubis.

(3) The cavernous urethra, about 15 centimeters long, extends from the end of the membranous region, just below the perineal membrane, to the external urethral orifice at the tip of the penis. It is surrounded by the corpus cavernosum of the urethra.

b. The female urethra, about 4 centimeters long, serves only in the urinary system. It extends inferiorly from the internal urethral orifice in the bladder, perforates the perineal membrane, and ends in the external urethral orifice located anterior to the vaginal opening.

### 3-18. THE MALE REPRODUCTIVE SYSTEM

The male reproductive system consists of the gonads (testes which produce the spermatozoa), a system of ducts and accessory glands, and the external genitalia (penis and scrotum).

a. **The Scrotum.** The scrotum (figure 3-9) is an integumentary sac that contains and supports the testes and the epididymis. It is suspended from the pubic and perineal regions directly dorsal to the base of the penis. Essentially, it is an extension of the abdominal wall, consisting of skin and subcutaneous tissue. A septum divides the scrotum into the two chambers that house the testes.

b. **The Testes.** The testes are a pair of oval, glandular organs about 5 centimeters long, suspended in the scrotum by the spermatic cords. Each testis is enclosed in a layer of dense, fibrous tissue from which originate fibrous sheets of tissue that divide the testis into numerous wedge-shaped chambers (lobules). Each chamber contains from one to three highly convoluted tubules, the seminiferous tubules. The lining of these tubules is composed of two specialized types of cells: the spermatogenic cells, which produce sperm, and the supportive cells (cells of Sertoli), which are thought to provide nutrient materials for the developing sperm cells. In addition, specialized cells (cells of Leydig) in the tissue between the tubules produce the male sex hormone testosterone. The convoluted, seminiferous tubules from adjacent compartments join into straight ducts that, in turn, unite with each other and form a network, the rete testis. From 12 to 20 tiny different ducts emerge from the rete testis, penetrate its fibrous coat, and form the beginning of the epididymis.

### c. Ducts and Accessory Glands.

(1) The epididymis is essentially a tortuous 4 to 6 meter canal that coils upon itself on the lateral posterior border of the testis. The efferent ducts of the testis unite to form the single ductus epididymis. The epididymis has two functions: storage of sperm and production of one of the liquid components of seminal fluid. At its distal end, the epididymis straightens out and joins the vas deferens.

(2) The vas deferens is a thick-walled tube about 45 centimeters long. It extends from the epididymis to the ejaculatory duct, which opens into the prostatic urethra.

(3) The seminal vesicles are two membranous sacs, each about 5 centimeters long, and consisting of a single tube coiled upon itself. They lie along the inferior-posterior surface of the bladder. Each terminates in a straight, narrow duct that joins the vas deferens to form an ejaculatory duct. The vesicles secrete a liquid that forms part of the seminal fluid.

(4) The two ejaculatory ducts are located on either side of the median plane. Union of the seminal vesicle duct and the end of the vas deferens forms each. Each ejaculatory duct is a short tube, about 2 centimeters long, that passes through the base of the prostate gland and opens into the prostatic urethra. During coitus, fluid from the seminal vesicles and sperm from the vas deferens are ejected into the prostatic urethra.

(5) The prostate gland (figure 3-11) is a firm, partly glandular and partly fibro, muscular mass of tissue surrounding the prostatic portion of the urethra. It is pyramidal in shape with its apex directed inferiorly and its base directed superiorly. The outer surface of the base is also in contact with the inferior aspect of the bladder. The prostate gland secretes a thin, slightly alkaline fluid into the prostatic urethra that neutralizes the acid conditions in the urethra and also provides a medium for sperm motility.

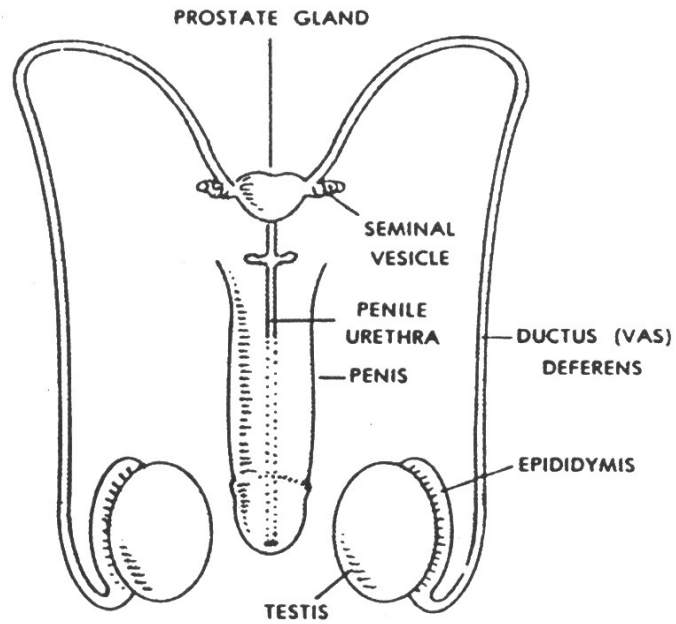
(6) Cowper's glands (bulbourethral glands) are two small, somewhat lobed bodies about the size of a pea, located just above the bulb of the penis, one on each side of the urethra. Secretions from Cowper's glands form part of the seminal fluid.

### d. The Penis.

(1) The penis consists of longitudinal columns of erectile tissue bound together with fibrous connective tissue and surrounded by skin.

(2) The corpus spongiosum penis surrounds the urethra, which is the passageway for both semen and urine. Distally, the corpus spongiosum penis is enlarged into the glans penis and contains the external urethral orifice. The circular fold of skin extending down over the glans penis is called the prepuce or foreskin.

## A. SCHEME OF ANTERIOR VIEW



## B. MIDSAGGITAL SECTION

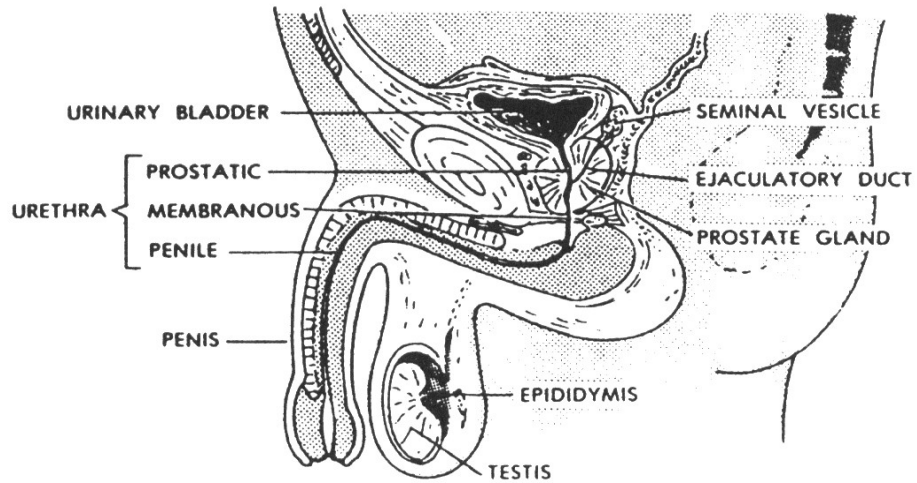


Figure 3-11. The human male reproductive (genital) system (A. anterior view; B. midsagittal section).

### 3-19. THE FEMALE REPRODUCTIVE SYSTEM

The female reproductive system consists of the gonads (ovaries), the fallopian tubes (oviducts), the uterus (womb), the vagina, and the external genitalia (vulva). The mammary glands are also sometimes considered to be a part of the reproductive system.

#### a. **The Ovaries.**

(1) The ovaries (figure 3-12) are a pair of flattened, oval bodies about 3 centimeters long, 1.5 centimeters wide, and one centimeter thick. They are located in the ovarian fossae, depressions on the lateral walls of the pelvis, on each side of the uterus. The ovaries are suspended from the broad ligament of the uterus by a fold of peritoneum, called the mesovarium, and attached to the uterus by the ovarian ligament.

(2) In the ovary, the germinal epithelium covers the surface. The interior of the ovary, the stroma, consists of connective tissue that is abundantly supplied with blood vessels. Embedded within the meshes of this framework is a large supply of vesicular follicles in varying stages of growth, each of which may form an egg cell (ovum). The follicles also produce the female sex hormones that are essential in the development of secondary sex characteristics, as well as the menstrual cycle, gestation, and lactation. However, other hormones formed in the anterior lobe of the pituitary gland regulate their production.

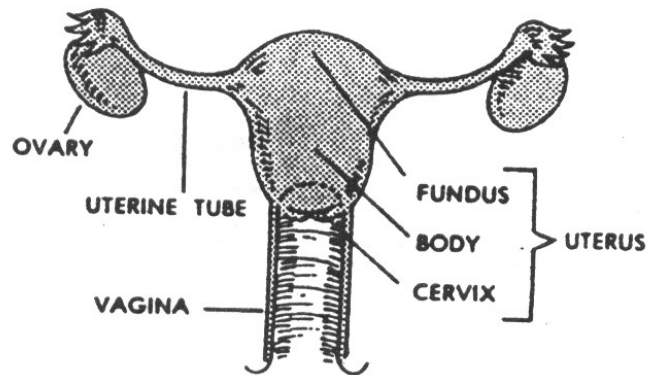
b. **The Fallopian Tubes or Oviducts.** The paired oviducts, or uterine tubes (figure 3-12A), are flexible, muscular, trumpet-shaped tubes about 10 centimeters in length and 1 to 8 millimeters in diameter. These tubes are in contact with the ovaries, but not continuous with them. The larger, funnel-shaped end of each tube has a fringed border that opens into the peritoneal cavity near the lateral border of the ovary. The more slender portion of the tube extends medially across the ovary and opens into the superior lateral wall of the uterus. The ovum (egg cell) extruded from the ovary is conveyed to the uterus through the fallopian tube. Fertilization of the ovum usually occurs in the tube, after which the fertilized ovum is generally passed on to the uterus.

c. **The Uterus.** The uterus (figure 3-13) is a hollow, muscular, pear-shaped organ that varies considerably in size and shape, but averages 7 centimeters in length, 5 centimeters in maximum width, and 2.5 centimeters in thickness. Located in the pelvic cavity between the rectum and urinary bladder, it presents two regions: the body and the neck.

(1) The body, or corpus uteri, is the main portion. It provides protection, support, and nourishment for the developing embryo. The contractions of its thick, muscular walls supply the expulsive force necessary for parturition (childbirth).

(2) The neck, or cervix, is the narrow lower third of the uterus. It contains the cervical canal, which is continuous with the main cavity in the body of the uterus.

## A. ANTERIOR VIEW



## B. MIDSAGGITAL SECTION

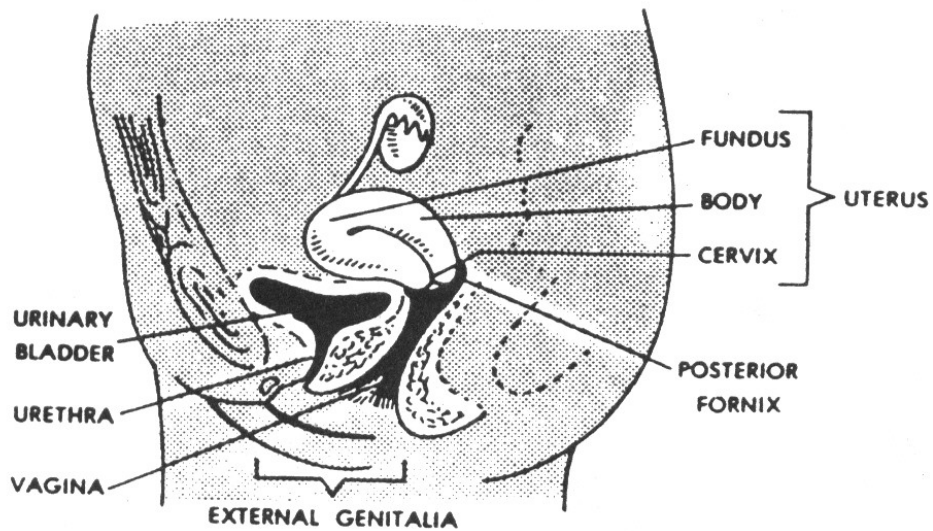


Figure 3-12. The human female reproductive (genital) system (A. anterior view; B. midsagittal section).

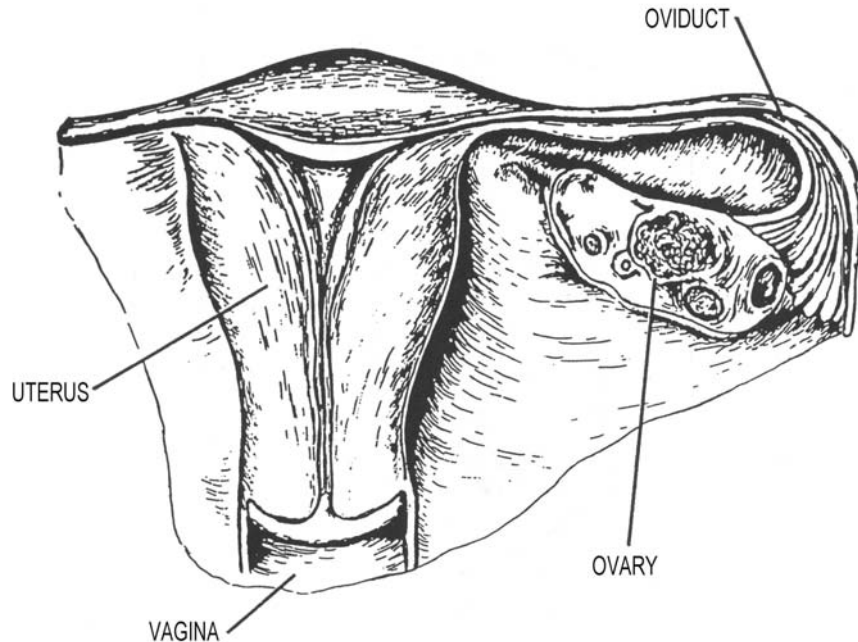


Figure 3-13. Frontal section of the female reproductive organs showing an oviduct and the pear-shaped uterus.

d. **The Vagina.** The vagina (figures 3-12 and 3-13) is a thin-walled, tubular organ extending from the cervix of the uterus to the vulva where it opens to the exterior. It averages 8 centimeters in length and lies dorsal to the bladder and urethra-ventral to the rectum. The vagina is also part of the birth canal.

e. **The Vulva.** The vulva (external genitalia) includes the mons pubis, labia majora, labia minora, clitoris, vestibule, and the greater vestibular glands (figure 3-14).

(1) The mons pubis is the rounded eminence anterior to the symphysis pubis, consisting mainly of fibrous and adipose tissue. Extending downward from the mons pubis and backwards toward the anus are two longitudinal cutaneous folds called the labia majora. Within these two folds of skin are two smaller cutaneous folds, called the labia minora, which meet anteriorly and form the prepuce of the clitoris.

(2) The cleft between the labia minor is the vestibule, which contains the clitoris, the urethral and vaginal orifices, and many vestibular glands. The clitoris, the homologue of the male penis, is a small body of erectile tissue located at the point where the two labia minor meet. The urethral orifice is located about 2.5 centimeters posterior to the clitoris and immediately anterior to the vaginal orifice. The urethra has no connection with the reproductive system. The urethra conveys urine. The vaginal orifice occupies about two-thirds of the posterior region of the vestibule and is separated from the cavity of the vestibule by a thin fold of mucous membrane, the hymen. The hymen may completely cover the vaginal orifice (imperforate hymen) or it may be absent entirely.



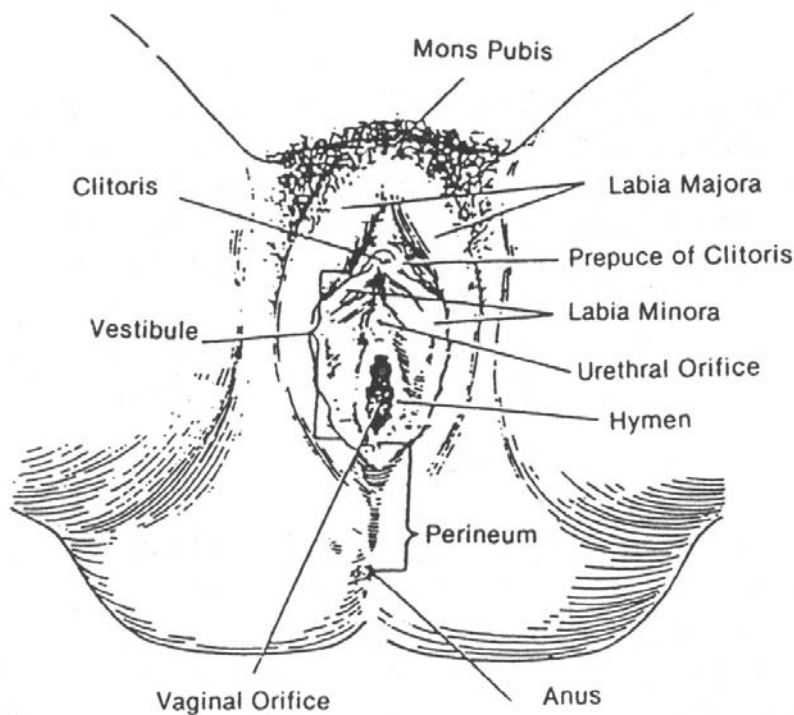


Figure 3-14. The vulva, the external female genitalia.

f. **The Mammary Glands (Breasts).** The mammary glands may be considered an accessory of the reproductive system since they secrete milk for the nourishment of infants. They extend vertically from the second to the sixth rib and transversely from the lateral margin of the sternum to the anterior border of the axilla at about the level of the fourth costal cartilage. Each breast is a cone-shaped mass of tissue, presenting near its center a papilla-like projection, the nipple. The nipple contains the openings of the milk ducts and is surrounded by a pigmented area of skin called the areola. Glandular tissues embedded in a large amount of connective tissue and varying amounts of fat comprise the internal structure. The glandular tissue consists of 15 to 20 lobes, each with its own draining duct. In the region of the nipple, each duct is dilated to form an ampulla that serves as a reservoir for the milk secretion before opening finally on the surface of the nipple. Endocrine secretions regulate the production of milk by the mammary glands.

## **Section III. THE RESPIRATORY SYSTEM**

### **3-20. GENERAL**

The respiratory system (figure 3-15) consists of the nose, pharynx, larynx, trachea, bronchi, and the lungs (in which are found the bronchioles and the alveoli, or air sacs). The primary function of the respiratory system is to supply the blood with oxygen from the outside air and to effect the elimination of carbon dioxide from the blood to the outside air. The exchanges between the air and the blood take place in the alveoli of the lungs, which are the essential structures of respiration. The mechanics of respiration will be discussed in greater detail later in this lesson.

### **3-21. THE NOSE AND PARANASAL SINUSES**

a. The nose is composed of bone and cartilage. On the undersurface of the external nose are two orifices, the nares. The nasal cavity is divided by the median nasal septum into the right and left nasal chambers. The chambers communicate with the exterior anteriorly by means of the nares and with the nasopharynx posteriorly by means of the conchae.

b. On the lateral wall of each nasal chamber are three nasal conchae. Under each concha is a meatus. Opening into each nasal chamber are the paranasal sinuses (figure 2-35), which are named according to the bone in which each is located. The ethmoidal sinuses, the maxillary sinuses, and the frontal sinuses open into the nasal cavity. The opening of the sphenoidal sinus is above the superior meatus. Inhaled air is warmed, moistened, and filtered by the nasal cavity. The filtering is done by cilia, the hair of the mucous membrane, lining the nasal passages.

### **3-22. THE PHARYNX**

The pharynx is a common passageway for air and food and, therefore, is also a part of the digestive system. The oral and laryngeal parts have been discussed. The two conchae, which are separated by the nasal septum, communicate with the pharynx anteriorly.

### **3-23. THE LARYNX**

The larynx, or voice box, is in the upper and front part of the neck. It is the passageway that connects the pharynx and the trachea. Its supporting framework is made up of nine cartilages: the single thyroid cartilage, cricoid cartilage, epiglottic cartilage, and the paired arytenoid, corniculate, and cuneiform cartilages. The epiglottis guards the entrance to the larynx.

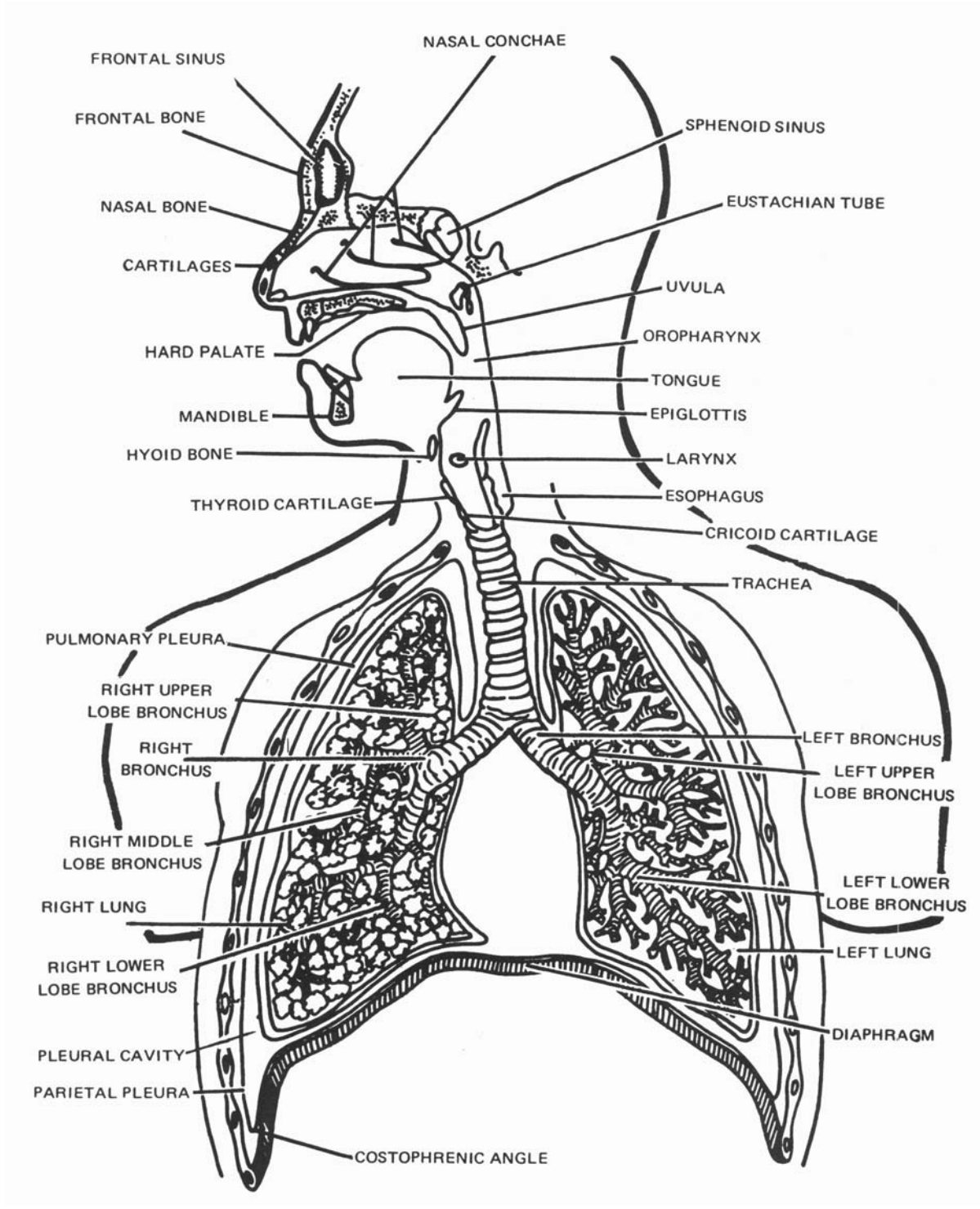


Figure 3-15. The respiratory system.

### 3-24. THE TRACHEA

a. The trachea, or windpipe, is a somewhat rigid, noncollapsible, pipe-like tube about 11 centimeters long. It is situated anterior to the esophagus and extends from the level of the sixth cervical vertebra to the inferior border of the fifth thoracic vertebra where it divides into the two bronchi. It extends into the thoracic cavity along the midsagittal plane.

b. The trachea consists of 16 to 20 C-shaped cartilages, superimposed one upon the other, forming the anterior two-thirds of the tracheal wall. Posteriorly, these open along the surface in contact with the esophagus. Consequently, the posterior surface of the trachea can be forced inward to some extent to allow swallowing of particles larger in diameter than the esophageal lumen.

### 3-25. THE BRONCHI

The two bronchi differ slightly. The right bronchus is about one inch in length and the left bronchus about two inches. Each bronchus enters its corresponding lung at a depression on the mediastinal surface, known as the hilus of the lung. As the bronchus extends into the lung, it divides and subdivides into smaller branches (bronchioles). Tiny air sacs, the alveoli, are at the terminal ends of the bronchioles.

### 3-26. THE LUNGS

a. The two lungs, one on either side within the thoracic cavity, are the essential organs of respiration. They are separated by the heart and mediastinal structures. Each lung is conical in shape, conforming generally to the shape of the cavity within which it lies. The broad base rests upon the diaphragm while the apex extends about one inch above the clavicle into the root of the neck.

b. Deep fissures into lobes divide each lung. The right lung has three lobes and the left lung two. The substance of the lungs is light, porous, and spongy owing to its numerous air-containing elements. The alveoli have very thin walls, and are surrounded by a network of capillary blood vessels. It is here that the interchange of gases occurs.

### 3-27. THE PLEURA AND THE PLEURAL CAVITY

a. Each lung is invested with a serous membrane, the pulmonary or visceral pleura. The rest of the membrane is called the parietal pleura. Different portions of the parietal pleura are called by special names that indicate their position. From the medial surface of each lung, the parietal pleura are reflected over the root (formed by the bronchus, nerves, and vessels) to the posterior surface of the sternum anteriorly and to the vertebral column posteriorly forming the mediastinal pleura. That portion lining the inner surface of the walls formed by the ribs is the costal pleura and that covering the top of the diaphragm is the diaphragmatic pleura.

b. The interface, or meeting place, of the pulmonary pleura and the parietal pleura is called the pleural cavity, but in health, it is only a potential, rather than an actual cavity. Its walls are covered with a film of serous fluid that moistens them and holds them together by hydraulic action in the presence of a barometric pressure that, in health, is slightly lower than atmospheric pressure. This tight adherence of the pulmonary and parietal pleurae facilitates movement of the lungs in the chest. The two pleural cavities are entirely separate from one another; thus one lung can be collapsed without affecting the other cavity or lung.

c. The costophrenic (phrenicostal) angle, or sinus, is the triangular space between the wall of the thorax and the lower margin of the diaphragm. This angle is readily seen in PA (posteroanterior) chest radiographs.

### **3-28. MECHANICS OF RESPIRATION**

a. Respiration is the act, or function, of breathing. The process of breathing may be subdivided into inspiration, or breathing in, and expiration, or breathing out. The coordinated movements of the lungs, diaphragm, abdomen, and associated muscles accomplish breathing.

b. In inspiration, the intercostal muscles between ribs contract to raise the anterior ends of the ribs. At the same time, a contraction flattens the dome-shaped diaphragm muscle. By these combined actions, the thoracic cavity is enlarged in all directions. As a result, each pleural cavity is also enlarged and, since it is completely airtight, a partial vacuum is created. Due to the lowering of the pressure in the pleural cavity and the elasticity of the lung, the air pressure within the lung is lowered. As the interior of the lung communicates freely with the outside air, this air rushes into the lung to equalize the pressure.

c. At the end of each inspiration, the intercostal muscles and the diaphragm relax and the thoracic wall returns to its normal resting position, giving an expiration. This decrease in size increases the pressure in the lungs. As a result, air flows out of the lungs until the pressure within them is again equal to that of atmospheric pressure. The lungs are prevented from collapsing by the negative pressure in the surrounding pleural cavity.

d. The muscles of respiration normally act automatically. The respiratory cycle consists of an active inspiration, followed by a passive expiration. The normal rate of quiet respiration in an adult is between 16 to 20 cycles per minute.

e. On full inspiration, the right dome of the diaphragm lies approximately at the level of the eleventh thoracic vertebra and the left dome at that of the twelfth thoracic vertebra. On full expiration, the right dome of the diaphragm lies at about the same level as the eighth thoracic vertebra and the left dome at that of the ninth thoracic vertebra. These respiratory movements of the diaphragm are important in radiography.

## Section IV. THE NERVOUS SYSTEM

### 3-29. GENERAL

a. The structural and functional unit of the nervous system is the nerve cell, or neuron, and its processes. A neuron is an elongated cell with dendrites (branches) to receive and conduct impulses toward the cell body and an axon (an elongation of the cell body) that conducts impulses away from the cell body. A nerve may be defined as a collection, or bundle, of nerve fibers.

b. The membrane theory of nerve conduction is explained by electrical and chemical changes in the neuron. A chain of neurons over which impulses may pass from a receptor, or sense organ, to a nerve center and back to an effector (muscle or gland) constitutes a reflex arc. A simple reflex arc (figure 3-16) consists of a sensory and a motor nerve connected within the spinal cord. Reflex arcs vary greatly in complexity. They may be quite complicated and involve several centers of the nervous system, or they may be relatively simple and involve only the lower levels.

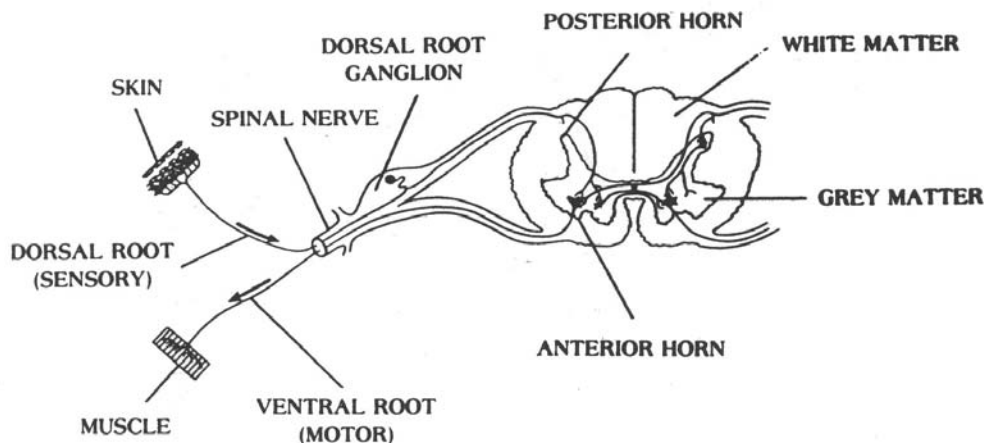


Figure 3-16. A simple reflex arc involving a receptor in the skin, a sensory nerve, a connecting center (ganglion) outside the spinal cord, the spinal cord, a motor cord, a motor nerve, and an effector.

### 3-30. THE NERVOUS SYSTEM

The nervous system may be sub classified as the central nervous system and the peripheral nervous system. The central nervous system includes the brain and spinal cord, while the peripheral nervous system includes all the nerves, ganglia, and end organs connecting the central nervous system with all other parts of the body. The peripheral nervous system includes the 12 pairs of cranial nerves (figure 3-17), the 31 pairs of spinal nerves, and the sympathetic nervous system.

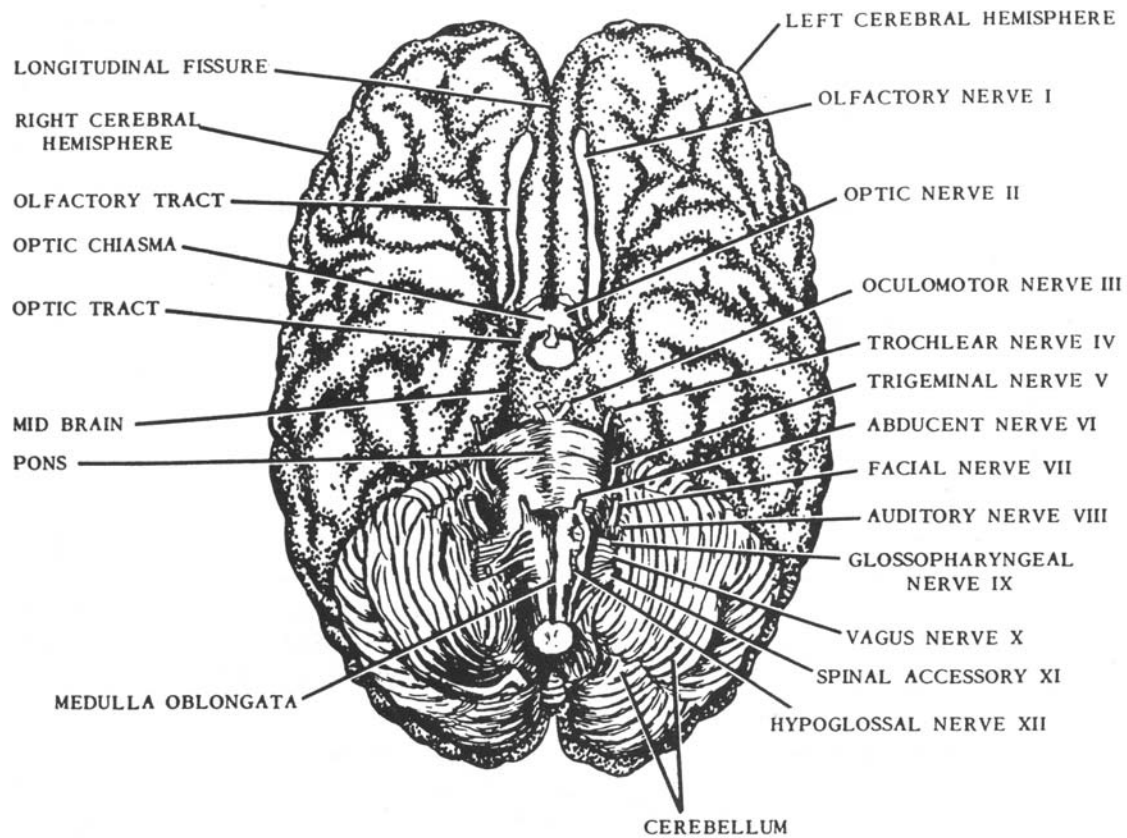


Figure 3-17. The human brain (basal surface showing cranial nerves).

### 3-31. THE AUTONOMIC (VISCERAL EFFERENT) NERVOUS SYSTEM

The autonomic nervous system is composed of the sympathetic nervous system (concerned primarily with emergency mechanisms) and the parasympathetic nervous system (concerned with the conservation of resources). The autonomic system controls visceral functions rather than somatic motor functions.

### 3-32. CENTRAL NERVOUS SYSTEM

a. **General.** The central nervous system presents two regions: gray matter and white matter. The gray matter contains mainly nerve cells and nonmyelinated fibers and the white matter, primarily myelinated nerve fibers. A concentrated mass of nerve cells (gray matter) in any part of the central nervous system is called a nucleus. A similar grouping of nerve cells in the peripheral nervous system (outside the brain and spinal cord) is called a ganglion. A tract is a bundle of nerve fibers with a common origin and destination. The nerve fibers are either ascending or descending, depending on whether they carry impulses to or from the brain.

b. **Embryonic Development.** In very early embryonic development, the central nervous system emerges as a continuous tube along the dorsal aspect of the embryo. As growth progresses, a small cranial portion of this neural tube develops into the brain and the remaining section becomes the spinal cord. In its early stages of development, the cranial portion of the neural tube presents three-enlargements: the forebrain, the midbrain, and the hindbrain. These three embryonic subdivisions give rise to the various regions of the adult brain. As the brain develops, the original cavity of the neural tube expands into four communicating chambers called ventricles that are continuous with the central canal in the spinal cord.

c. **Protective Coverings.** The brain and spinal cord are well protected within the skeleton, the brain in the cranium and the spinal cord in the vertebral canal. In addition, three connective tissue membranes called meninges (the dura mater, the arachnoidea, and the pia mater) enclose them.

(1) The dura mater, the outermost covering, is a tough fibrous membrane. It adheres to the inner surface of the cranium, but in the spinal canal it is separated from the bony housing by the small epidural space.

(2) The arachnoidea, the middle meningeal tissue, is a delicate serous membrane that loosely envelops the brain and the spinal cord. The potential space between the arachnoid and the dura mater contains cerebrospinal fluid.

(3) The pia mater, the innermost meningeal membrane, is a loosely arranged network of vascular tissue containing a plexus of fine blood vessels that permit the passage of blood to and from the central nervous system. Between the arachnoid and the pia mater is the subarachnoid space, which contains cerebrospinal fluid. The ventricles of the brain are lined by the pia mater.



### 3-33. THE BRAIN

The brain, or encephalon (figures 3-18 and 3-19), is the center of the nervous system. It fills the cranial cavity of the skull and weighs about 1,300 grams. It is the most complex mass of nervous tissues and serves as the coordinating center for all somatic and visceral functions of the body. As noted above, the adult brain develops from three embryonic regions: the forebrain, the midbrain, and the hindbrain.

a. **The Forebrain.** The forebrain, or prosencephalon, of the embryo develops into the cerebrum and the diencephalon, which consists of the thalamus, and the hypothalamus.

(1) The cerebrum, also known as the telencephalon, is the main portion of the brain, constituting about seven-eighths of its total weight. The deep longitudinal fissure divides it into right and left cerebral hemispheres. These hemispheres consist essentially of an outer region of gray matter, the cerebral cortex, which spreads over an inner mass of white matter. Several bands of nerve tissue, called commissures, connect the two hemispheres. The corpus callosum, also known as the great commissure of the brain, is the most prominent. It consists of bands of nerve fibers that form an arch below the longitudinal fissure and connect the two hemispheres. The hemispheres are divided into lobes, named after the bones of the cranium in which they lie. Although the functioning of the cerebrum is not completely understood and most of its coordinating activities involve more than one lobe, it has been found that certain functions are localized in the four lobes as follows: frontal lobe (higher thought processes and voluntary actions); parietal lobe (sensory and motor functions); temporal lobe (hearing); and occipital lobe (sight).

(2) The diencephalon, which consists of the thalamus and hypothalamus, is located between the cerebrum and midbrain. The thalamus is a large ovoid mass of gray matter located at the base of the cerebrum. It consists of two large nuclear masses separated by the third ventricle (figure 3-16) and connected by a bridge of gray matter, the connexus interthalamicus, also called the intermediate mass. It serves as a relay center for sensory impulses en route to the cerebral cortex. The hypothalamus is inferior to the thalamus and forms the floor and part of the lateral wall of the third ventricle. It is involved in the regulation of many metabolic processes and the functioning of certain viscera.

b. **The Midbrain.** The midbrain (figure 3-17), or mesencephalon, is the short section between the forebrain and the hindbrain. It provides the main motor connection between the forebrain and the midbrain. Dorsally, it presents two pairs of rounded elevations: the corpora quadrigemina, which act as relay centers in auditory and visual reflexes, and ventrally the cerebral peduncles, which are two diverging stalks, one entering each cerebral hemisphere. These peduncles consist of bundles of fibers that provide pathways for impulses passing to and from the cerebrum.

c. **The Hindbrain.** During embryonic development, the hindbrain (rhombencephalon) is divided into two portions: the metencephalon and the myelencephalon. The metencephalon develops into the cerebellum and pons, and the myelencephalon into the medulla oblongata (figures 3-17 and 3-19).

(1) The cerebellum (or "little brain") is located in the posterior region of the skull inferior to the occipital lobes of the cerebrum. It consists of two lateral expansions, the hemispheres, and a constricted central portion, the vermis, which joins the two hemispheres. Its internal structure is similar to that of the cerebrum with the gray matter located in the outer cortical layer. Three pairs of peduncles connect the cerebellum with the other portions of the brain and spinal cord. The superior peduncles connect the cerebellum with the midbrain, the middle peduncles connect it with the pons, and the inferior peduncles connect it with the medulla oblongata. The cerebellum acts as a reflex center that coordinates muscular movements. It is also the control center for the maintenance of posture and equilibrium.

(2) The pons (figure 3-14) is anterior to the cerebellum and lies between the midbrain and the medulla oblongata. As the name implies, it forms a bridge of connecting fibers, extending between the halves of the cerebellum and joins midbrain with the medulla. It is located in the midline of the cranial cavity at the base of the skull.

(3) The medulla oblongata is anterior to the cerebellum and extends almost vertically from the caudal margin of the pons through the foramen magnum to the level of the cranial border of the atlas where it joins the spinal cord. Internally, its structure resembles that of the spinal cord with the gray matter generally located centrally. Many nerve fibers in the medulla cross from one side to the other. As a result, one side of the brain controls the opposite side of the body. The medulla contains the fourth ventricle, which is continuous with the central canal of the spinal cord. It serves as a relay station for the passage of impulses between the brain and the spinal cord, contains centers controlling cardiac vasomotor and respiratory activities, and regulates many other reflex activities.

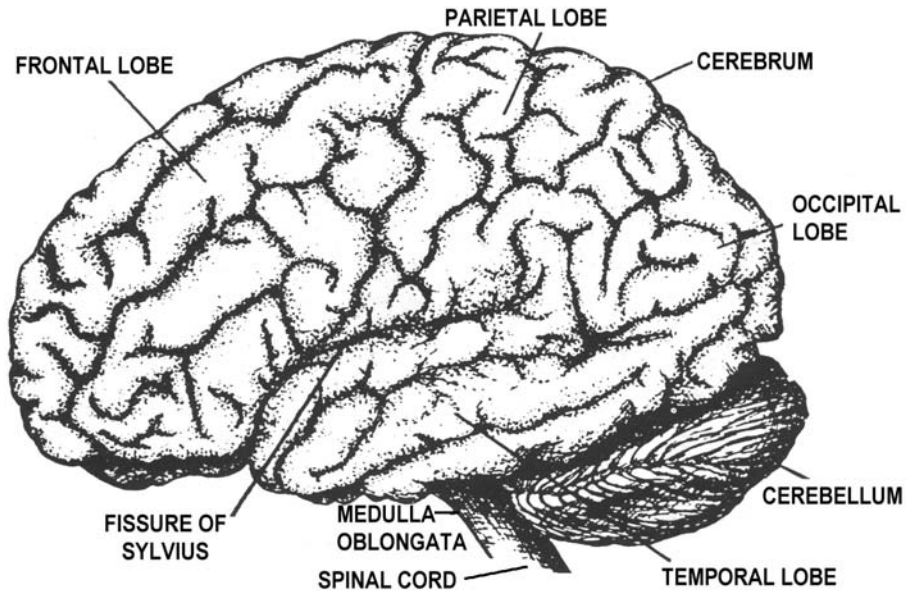


Figure 3-18. The human brain (lateral view).

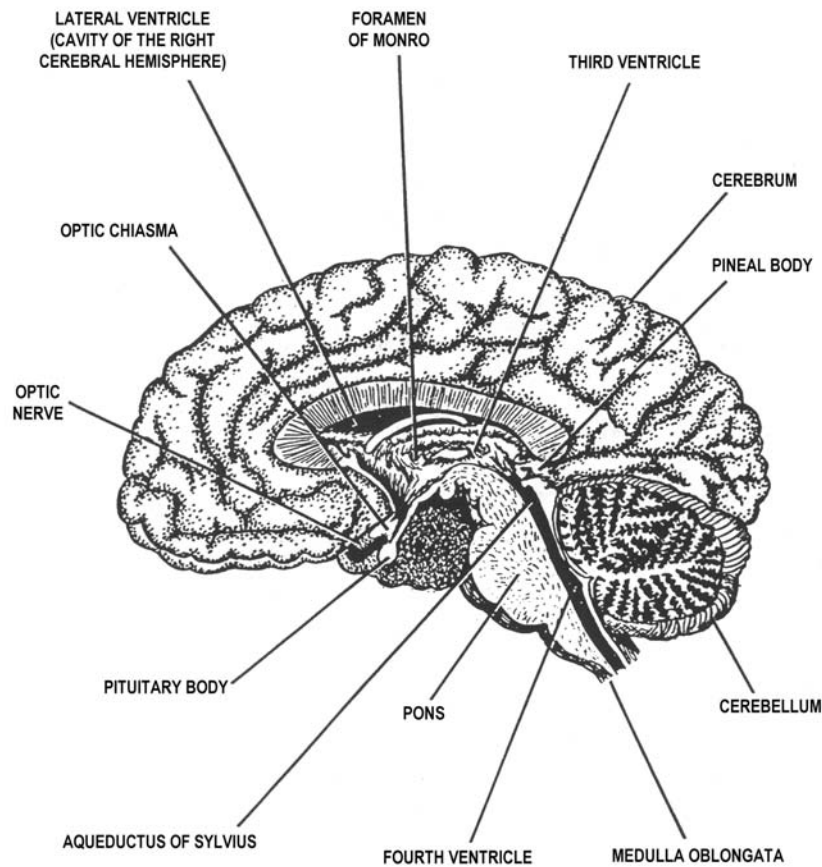


Figure 3-19. The human brain (sagittal section).

#### d. Ventricles and Cerebrospinal Fluid.

(1) The ventricles (figures 3-20 and 3-21) are four communicating cavities located within the brain. The lateral ventricles are located in the right and left cerebral hemispheres. They communicate with the third ventricle through the interventricular foramen (foramina of Monro). The third ventricle is a small passageway in the center of the diencephalon and is connected with the fourth ventricle through the cerebral aqueduct (aqueduct of Sylvius). The fourth ventricle is located anterior to the cerebellum, posterior to the pons, and in the upper portion of the medulla oblongata. It communicates with the subarachnoid space (between the arachnoid and pia mater membranes) through three openings: two lateral foramina of Luschka and one medial foramen of Magendie.

(2) The cerebrospinal fluid is a clear, viscid liquid formed in the choroid plexuses, tortuous vascular masses on the roofs of the lateral and third ventricles. A layer of epithelium separates the blood vessels of the choroid plexuses from the ventricular activities. Cerebrospinal fluid is formed as an almost protein-free extract of the blood. As the blood flows through the many choroid plexuses, water, traces of protein, glucose, lymphocytes, and some hormones leave the blood plasma and enter the ventricles as cerebrospinal fluid by active transport.

(3) Cerebrospinal fluid is enclosed in its own circulatory system within the brain, passing from the right and left ventricles through the interventricular foramen of Monro into the third ventricle and then by way of the cerebral aqueduct of Sylvius into the fourth ventricle. From the fourth ventricle, it passes through the medial foramen of Magendie and two lateral foramina into the subarachnoid space over the surface of the brain. It may continue down the central canal of the spinal cord. In addition, the cerebrospinal fluid moves caudally along the dorsal surface of the spinal cord and cranially along its ventral surface in the subdural spaces. In the circulatory process, it filters through small villi of arachnoid tissue into venous sinuses where it is returned to the main bloodstream. Cerebrospinal fluid serves as a shock absorber for the brain and spinal cord.

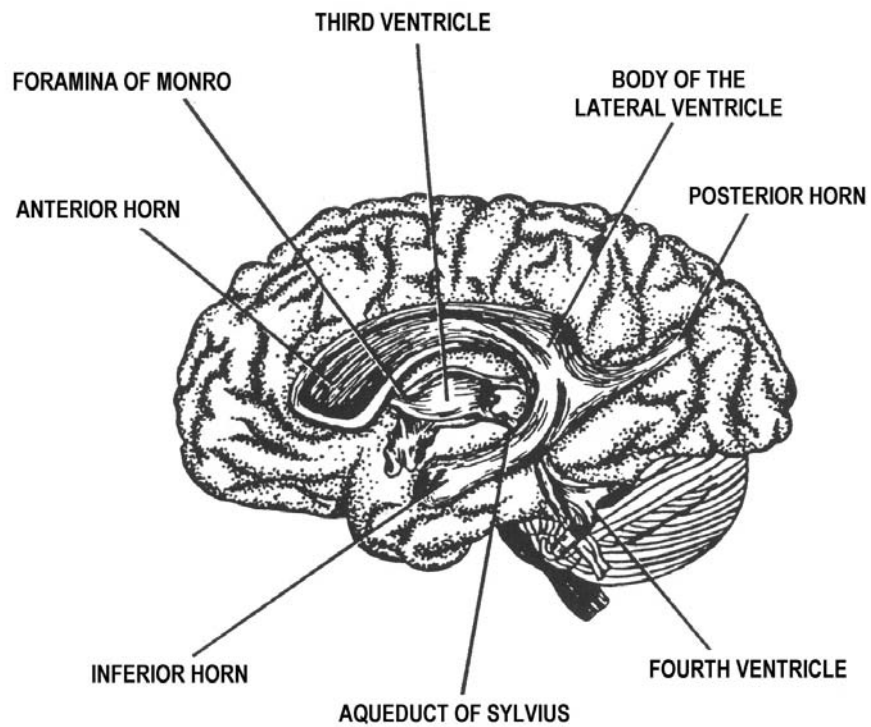


Figure 3-20. The ventricular cavities viewed from the side.

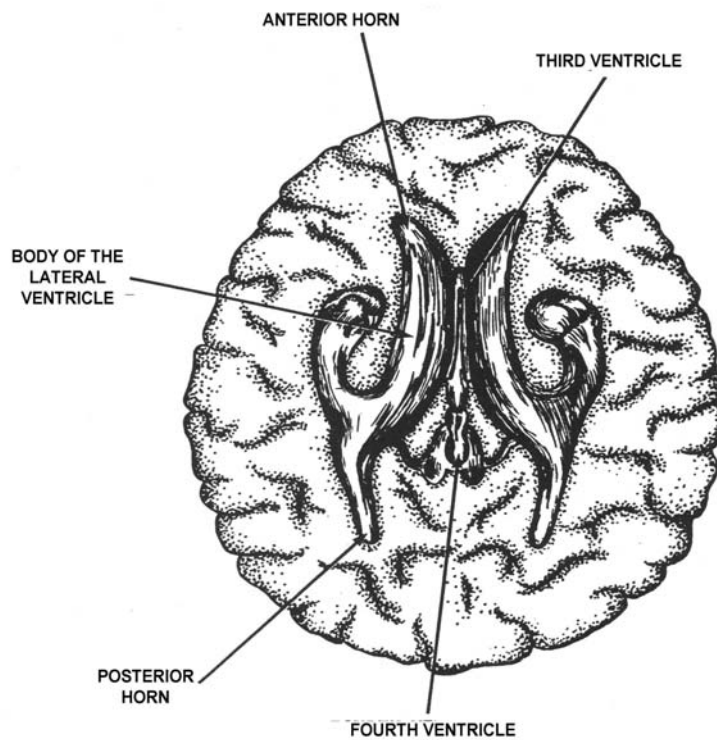


Figure 3-21. The ventricular cavities viewed from above.

### 3-34. THE SPINAL CORD

a. The spinal cord occupies the upper two-thirds of the spinal canal. It is continuous with the medulla oblongata and extends from the foramen magnum at the base of the skull to the cranial border of the second lumbar vertebra. The caudal end tapers into the filum terminale, which is the threadlike extension of the cord ending at about the level of the first sacral segment. Thirty-one pairs of spinal nerves extend from the cord. These nerves exit the neural canal through the intervertebral foramina. Neurologists have determined approximately what areas of the body are innervated for feeling (sensory) and motor (muscle contraction), and the level in the spinal cord where these nerves synapse.

b. The patellar reflex exemplifies the reflex arc. This stretch reflex is obtained by striking just below the patella with a rubber hammer. The sensory nerve transmits the impulse through the posterior root of L-2, L-3, and L-4 (which lie in the lower part of the cord) to connector neurons that terminate in the anterior root. Here, the motor neurons transmit the impulse to the muscles of the thigh, which contract to "jerk" the knee. It should be noted that pressure on the cord might result in paralysis or pain. If the pressure is removed, functions will probably be restored. However, tearing or breaking the brain or cord results in permanent disability and there is no recovery.

## Section V. THE CIRCULATORY SYSTEM

### 3-35. GENERAL

The circulatory system includes the lymphatic system, the blood, and the cardiovascular system. Its purpose is to carry oxygen and nutrients to the tissues of the body and to carry carbon dioxide and other waste materials away from the tissue, as well as to maintain fluid balance and to fight infection.

### 3-36. THE LYMPHATIC SYSTEM

a. The lymphatic system is composed of the lymphatic vessels and the lymph glands, or nodes. The lymphatic vessels are similar to veins (they contain valves) and are filled with lymph. Lymph is interstitial fluid that flows into the lymphatics; interstitial fluid is the "middle-man" between the blood and the tissues. The microscopic lymph vessels terminate in the tissues as blind closed-ended tubes. The pressure from the arterioles forces nutrients into the tissue spaces. This force, plus contracting muscles and osmosis, pushes some of the fluids into the lymph vessels. The smaller vessels unite to form larger vessels that carry the lymph into an extensive network of nodes.

b. The lymph nodes, or glands, are small oval or bean-shaped bodies, varying from a pinhead to a lima bean in size. They are distributed along the course of the lymph vessels, sometimes singly, but usually in groups or clusters. These are sometimes superficial, and are sometimes deep nodes in close contact with arteries and veins. Lymph nodes are especially numerous in the neck (cervical), the armpit (axillary), the groin (inguinal), and in the thorax and abdomen. Lymph vessels enter these nodes, and a larger trunk leaves the nodes. The nodes provide a tortuous maze containing lymphocytes that defend the body against invasion of bacteria. Eventually, vessels from the nodes carry lymph to the thoracic duct (where lymph from the left and lower portions of the body enters the bloodstream at the junction of the left subclavian vein and the left internal jugular vein) or the right lymphatic duct (where lymph from the upper right portion of the body enters the bloodstream at the junction of the right subclavian vein and the right internal jugular vein). Valves prevent any backflow. The distribution of the principal lymph nodes and their vessels is shown in figure 3-22.

### **3-37. THE SPLEEN**

The spleen is the largest collection of lymphoid tissue in the body. It is a large, gland-like, but ductless, organ directly beneath the diaphragm behind and to the left of the stomach. The spleen is an elongated ovoid body, more or less bean-shaped, and is enclosed in a capsule of connective and muscular tissue. Its main functions are to store and cleanse blood to destroy old red blood cells and, in the fetus, to produce new red blood cells. It also produces lymphocytes. The spleen may be visualized radiographically both with and without contrast media.

### **3-38. BLOOD**

a. The blood is a red fluid, (bright red in the arteries and dark red in the veins) containing erythrocytes (red blood cells-(RBC)), leukocytes (white blood cells-(WBC)), platelets, and plasma. The red cell count in the normal male is from 5 to 6 million per cubic millimeter and in the normal female from 4.5 to 5.5 million per cubic millimeter. These cells give the blood its red color. The number of white cells is approximately 7,000 to 9,000 per cubic millimeter in the normal adult. The average number of platelets is about 300,000 per cubic millimeter of blood. Their chief function is concerned with the clotting of blood. The plasma is the fluid portion of the circulating blood. It is composed of serum (the fluid containing the nourishing elements of the blood) and fibrinogen, which is a substance that aids in the clotting of the blood.

b. The functions of the blood are to carry nutritive material and oxygen to the tissues of the body, to remove the waste products of the tissues, to protect the body against bacterial invasion, and to maintain proper temperature and moisture content in the body.

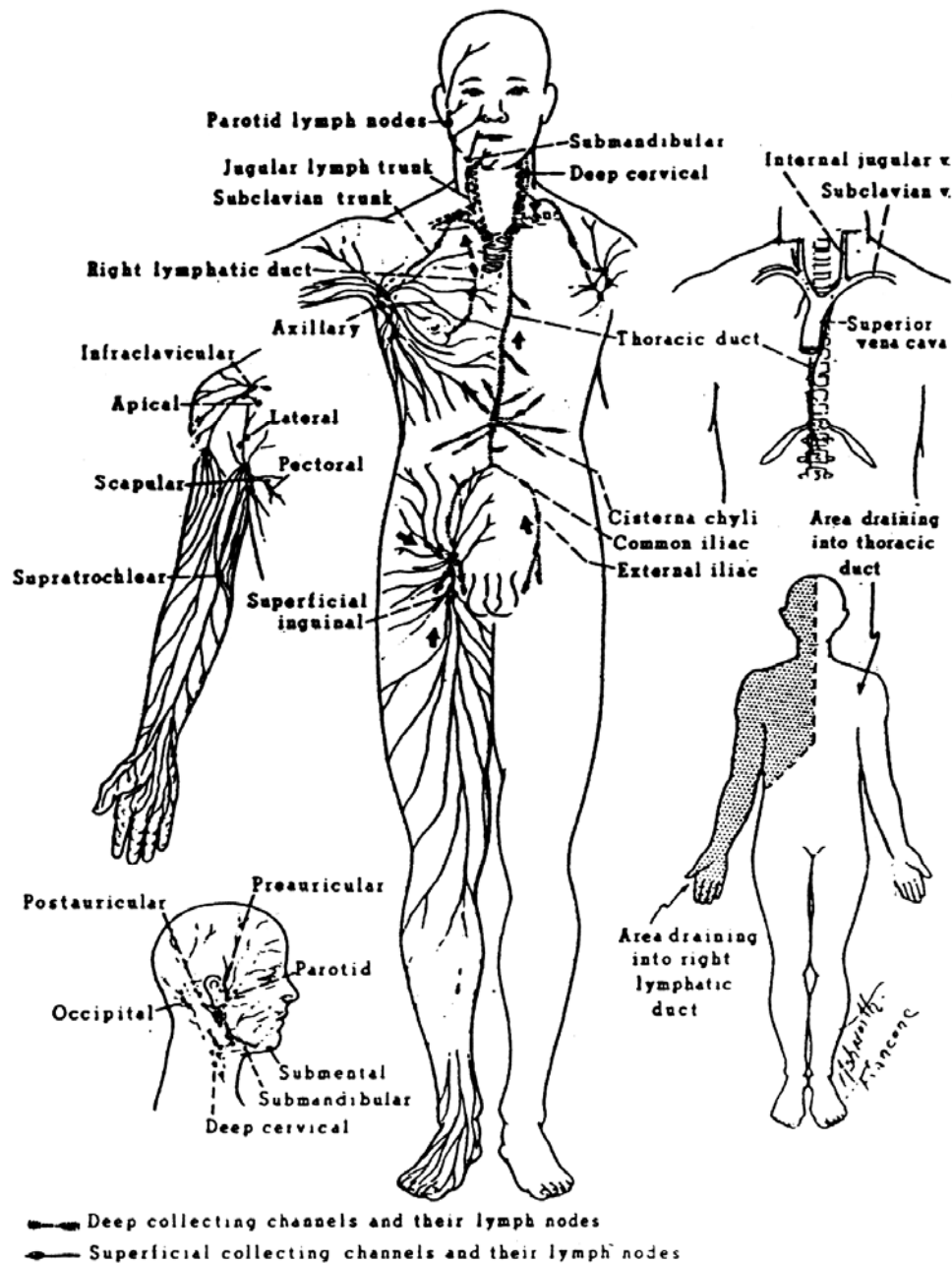


Figure 3-22. The lymphatic system and drainage. (Reproduced for instructional purposes from Stanley W. Jacob and Clarice Ashworth Francone, Structure and Function in Man, 2d edition, 1970, Chapter 11. Written consent of the copyright owner has been obtained.)



### 3-39. THE CARDIOVASCULAR SYSTEM

The cardiovascular system consists of the heart and the arteries, the veins, and the capillaries. It is concerned with the movement of blood through the body.

### 3-40. THE HEART

a. **General.** The heart (figures 3-23 and 3-24) is the major organ of the circulatory system. It is hollow, muscular, and somewhat cone-shaped, slightly larger than the closed fist. In the average male, it weighs about 300 grams. The heart lies obliquely in the lower two-thirds of the thoracic cavity, with the apex directed downward and the bulk of its mass to the left of the midsagittal line. It may be felt pulsating between the fifth and sixth ribs, about 2.5 cm below the left nipple.

b. **Structure.**

(1) Located in the mediastinum, the heart is enclosed in a dual-layered, loose-fitting sac called the pericardium. Between the outer fibrous layer and the inner serous layer is a serous liquid, the pericardial fluid, which lubricates the smooth outer surface of the heart. The superior portion, or base, of the heart consists of two receiving chambers, the atria. The main body extends into the apex and consists of two larger chambers, the ventricles. Blood from all parts of the body, except from the lungs, enters the right atrium through three veins: the coronary sinus (which collects blood from veins of the heart) and the inferior and superior vena cava (which collect blood from the other veins of the systemic circulation). Blood from the lungs enters the left atrium through the pulmonary veins. Two arteries emerge from the ventricles. From the right ventricle, the pulmonary artery carries blood to the lungs, and from the left ventricle; the aorta distributes blood to all other parts of the body.

(2) As the heart beats, backflow of blood is prevented by the action of valves: the tricuspid valve between the right atrium and ventricle, the mitral valve (bicuspid valve) between the left atrium and ventricle, and the semilunar valves, which guard the outlets of the ventricles.

c. **Circulation of Blood Through the Heart.** You may follow the arrows in figure 3-23 to illustrate the following discussion: deoxygenated blood from the body tissue enters the right atrium through the superior and inferior venae cavae. It then is passed through the tricuspid valve into the right ventricle. The blood leaves this chamber through the pulmonary semilunar valve and is passed by the right and left pulmonary arteries to the lungs, where it receives a fresh supply of oxygen and releases carbon dioxide. The oxygenated blood is returned to the heart in the right and left pulmonary veins, which open into the left atrium. From the left atrium, the blood is passed through the bicuspid (or mitral) valve into the left ventricle. This ventricle is the largest and strongest chamber of the heart, and from it the oxygenated blood passes through the aortic semilunar valve into the aorta, from which it is sent to all parts of the body, except to the lungs.

## YOUR HEART AND HOW IT WORKS

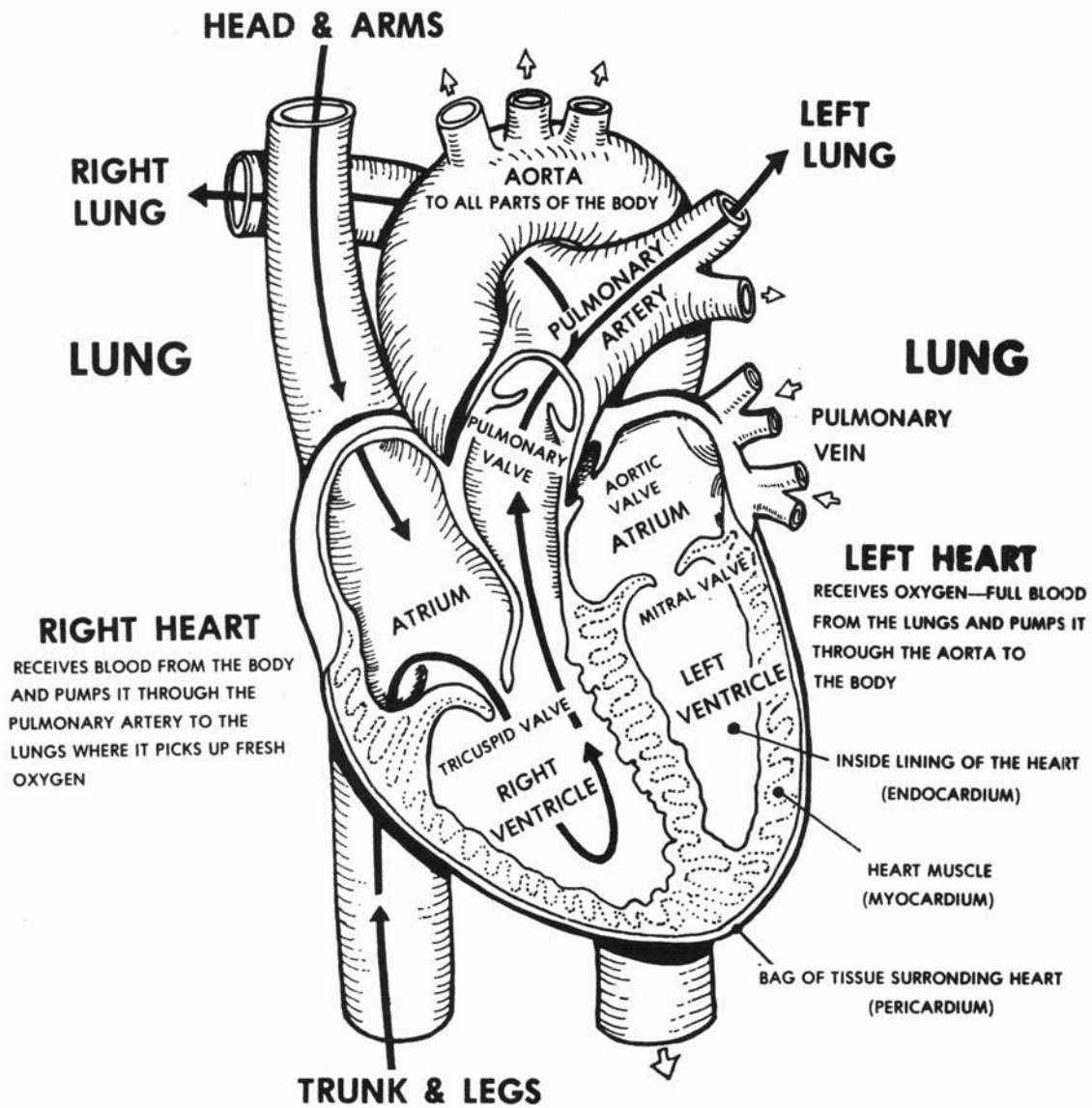


Figure 3-23. The circulation of blood through the heart.

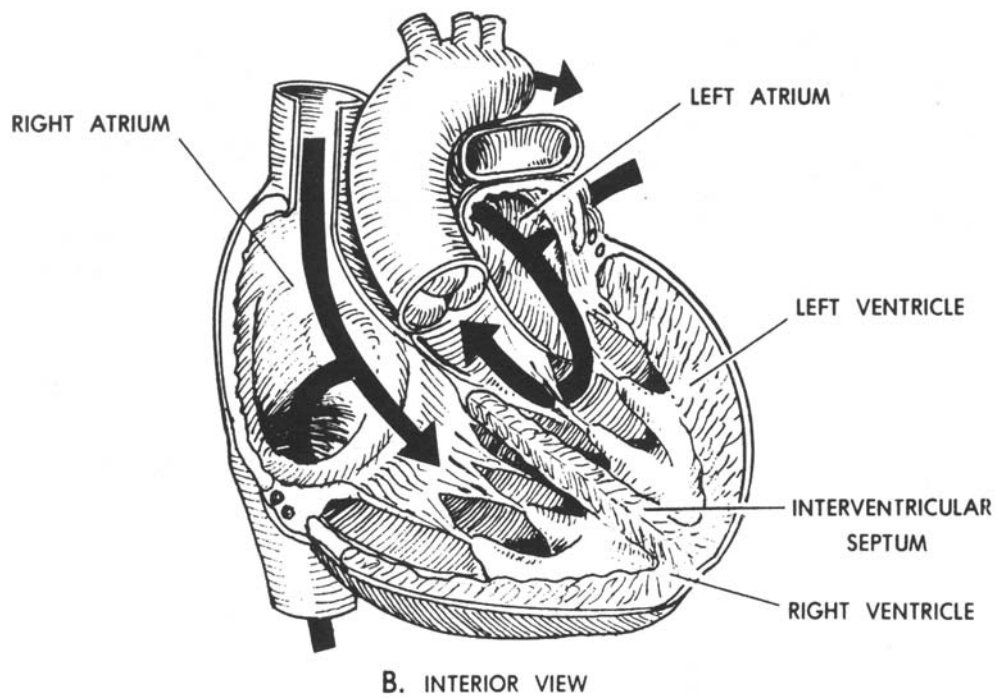
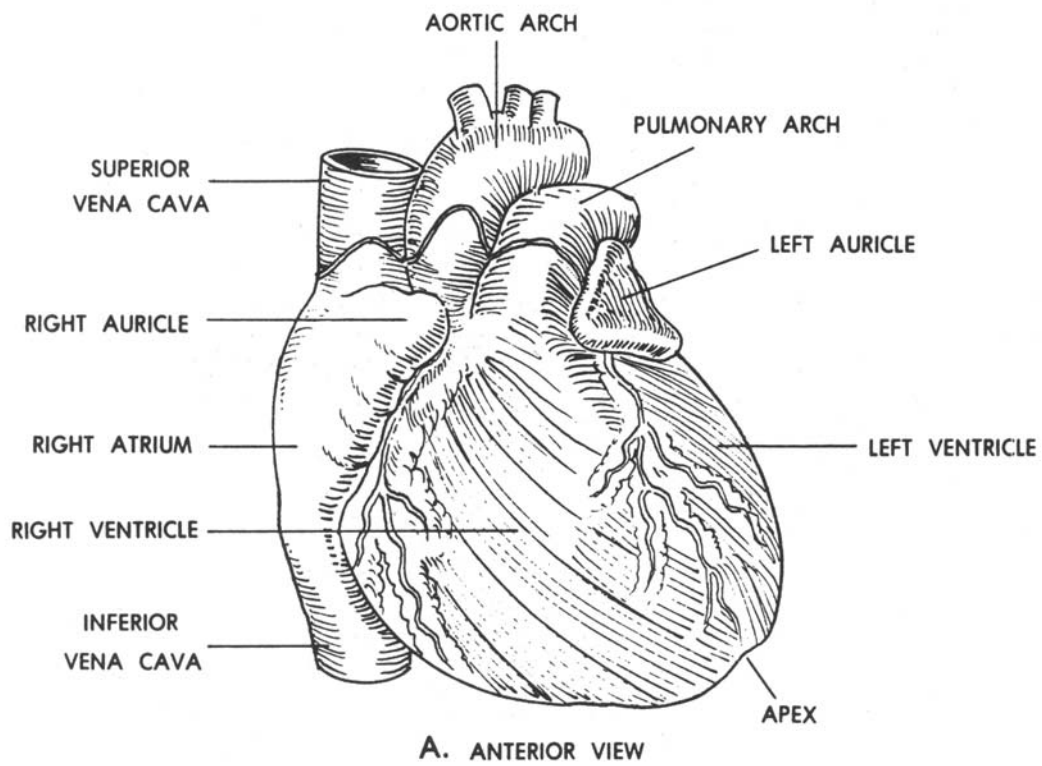


Figure 3-24. The human heart.

#### d. Heart Action.

(1) Variations in the individual heart rate depend on sex, age, and physical activity, as well as on other factors. However, the heart normally beats about 70 times per minute. The body of the adult normally contains 4 1/2 to 5 1/2 quarts of blood.

(2) Each heartbeat, or cardiac cycle, consists of a wave of ventricular contractions called systole followed by a wave of relaxation called diastole. Each wave starts at the atria and moves across the ventricles. When a chamber is in systole, blood is being forced out; when it is in diastole, blood is entering. The systolic pressure is the pressure during the contraction phase, the diastolic pressure is the pressure during relaxation, and the pressure between the two pulses is the pulse pressure.

### 3-41. THE BLOOD VESSELS

a. The vessels carrying blood from the heart to all parts of the body are the arteries. They branch out extensively through the body, becoming progressively smaller and ending in minute vessels called arterioles. From the arterioles, the blood passes through a network of microscopic thin-walled channels called the capillaries. From here, the blood is collected into venules and then returned to the heart through veins of progressively larger size.

b. Arteries are thick-walled and never empty. Veins are thin-walled and collapse when there is no air. The force of muscles adjacent to veins aids in the forward propulsion of blood toward the heart. Valves spaced frequently along the large veins prevent the backflow of blood. Both arteries and veins are lined with endothelium. The capillary walls are composed of a single layer of endothelial cells.

### 3-42. SYSTEMIC CIRCULATION

The systemic circulation follows an orderly pattern in which blood from the heart is pumped through the major arteries and its branches to all body tissues (except the lungs) and returns to the heart through major veins and their tributaries.

a. **Via the Major Arteries.** The aorta is the primary arterial trunk line in the systemic circulatory system. It arises from the left ventricle, ascends superiorly, arches over the left lung, and branches to supply blood to the head and arms. It descends through the thoracic and abdominal cavities, along the spinal column to the level of the fourth lumbar vertebra. Here, it bifurcates into the right and left common iliac arteries, which supply the lower extremities. Major arteries supplying other parts of the body branch out from the aorta at specific locations. For descriptive purposes, the aorta may be divided into four regions: the ascending aorta, the arch of the aorta, the thoracic aorta, and the abdominal aorta. The major arteries are shown in figure 3-25.

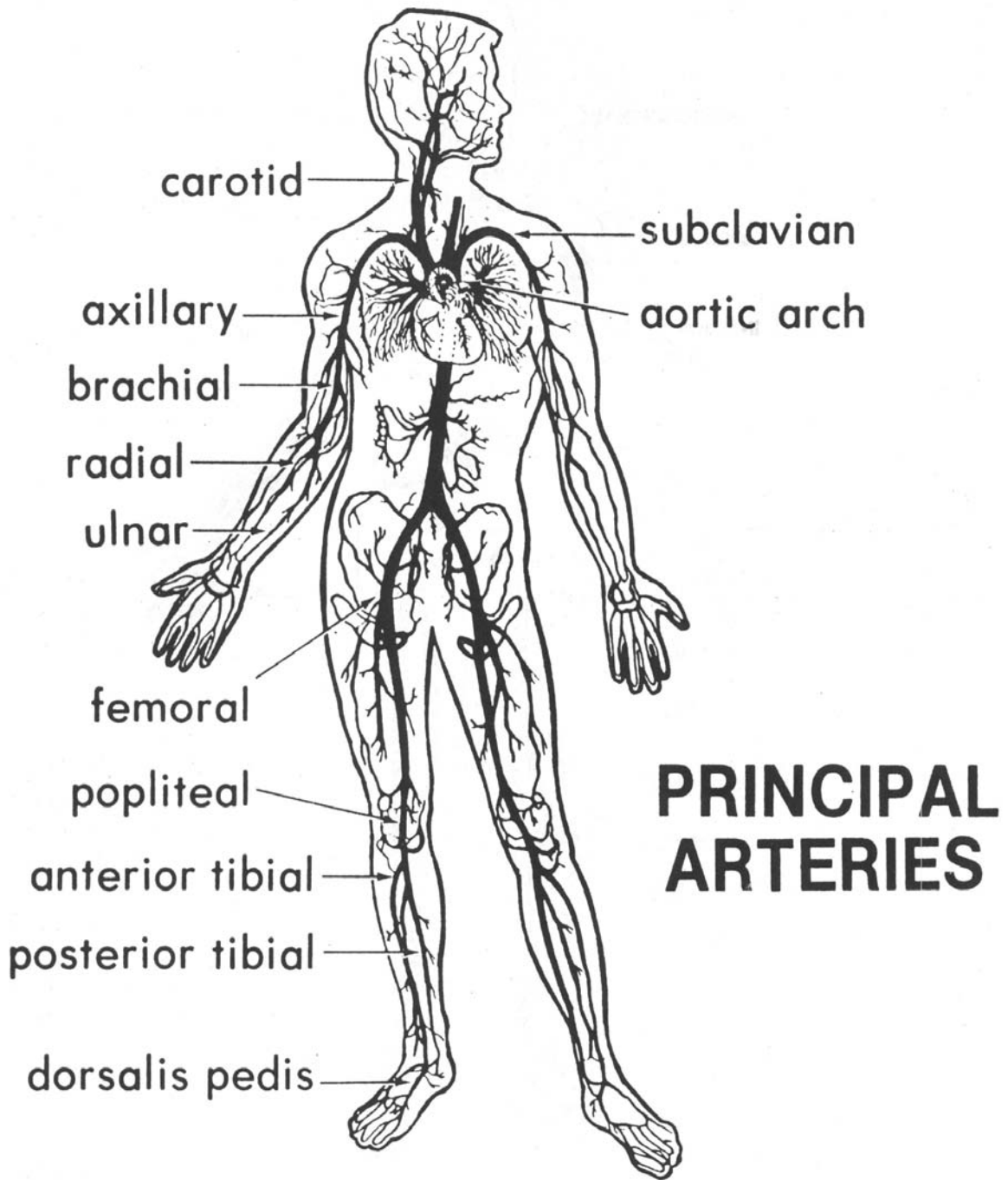


Figure 3-25. The principal arteries.

## b. Via the Major Veins.

(1) In general, the major veins pass through the body in proximity to the arteries, and in most cases, have the same names. Blood from the veins of the heart drains through the coronary sinus into the right atrium. Blood from the head and neck drains into the jugular veins, and that from the upper extremities into the subclavian veins. On each side, these veins join to form the right and left brachiocephalic veins, which, in turn, unite into the superior vena cava that opens into the right atrium. The superior vena cava also receives the azygos vein which, with its tributaries, returns blood from the thorax to the superior vena cava. The azygos vein begins in the abdomen as an extension of one of the tributaries of the inferior vena cava and serves as a connection between the superior and inferior venae cavae in the return of blood to the heart. The major veins are shown in figure 3-26.

(2) From the lower extremities and abdomen, two venous routes lead to the heart. In the direct route, blood from the lower extremities moves through the right and left common iliac veins, which join at the level of the fifth lumbar vertebra to form the inferior vena cava. This major vein passes through the abdominal cavity in proximity to the aorta along the posterior abdominal wall. It receives the lumbar, genital, renal, adrenal, hepatic, and inferior phrenic veins as it ascends through the abdominal cavity before it enters the right atrium of the heart.

(3) Blood from the spleen and the abdominal organs of the gastrointestinal tract is not returned directly to the heart by way of the inferior vena cava. Instead, the veins draining the small intestine, stomach, lower esophagus, and spleen join to form the portal vein, which enters the liver. Blood from the tissues of the liver enters the hepatic vein which then drains into the inferior vena cava en route to the right atrium.

### 3-43. PULMONARY CIRCULATION

The pulmonary arteries arise from the right ventricle and carry deoxygenated blood to the lungs where gaseous exchanges occur. The lungs are drained by the pulmonary veins, which carry oxygenated blood to the left atrium of the heart.

### 3-44. PATHOLOGICAL CONDITIONS

A thrombus is a clot of blood lodged at its point of formation in a blood vessel or the heart. If a clot or any foreign material travels from its point of origin until it becomes lodged in a smaller vessel, it is called an embolism. Arteriosclerosis is a condition of arteries that results from a collection of cholesterol and fats on the interior wall, narrowing the lumen. Arteriosclerosis is a hardening of the arterial wall. An aneurysm is a ballooning of an artery or vein.

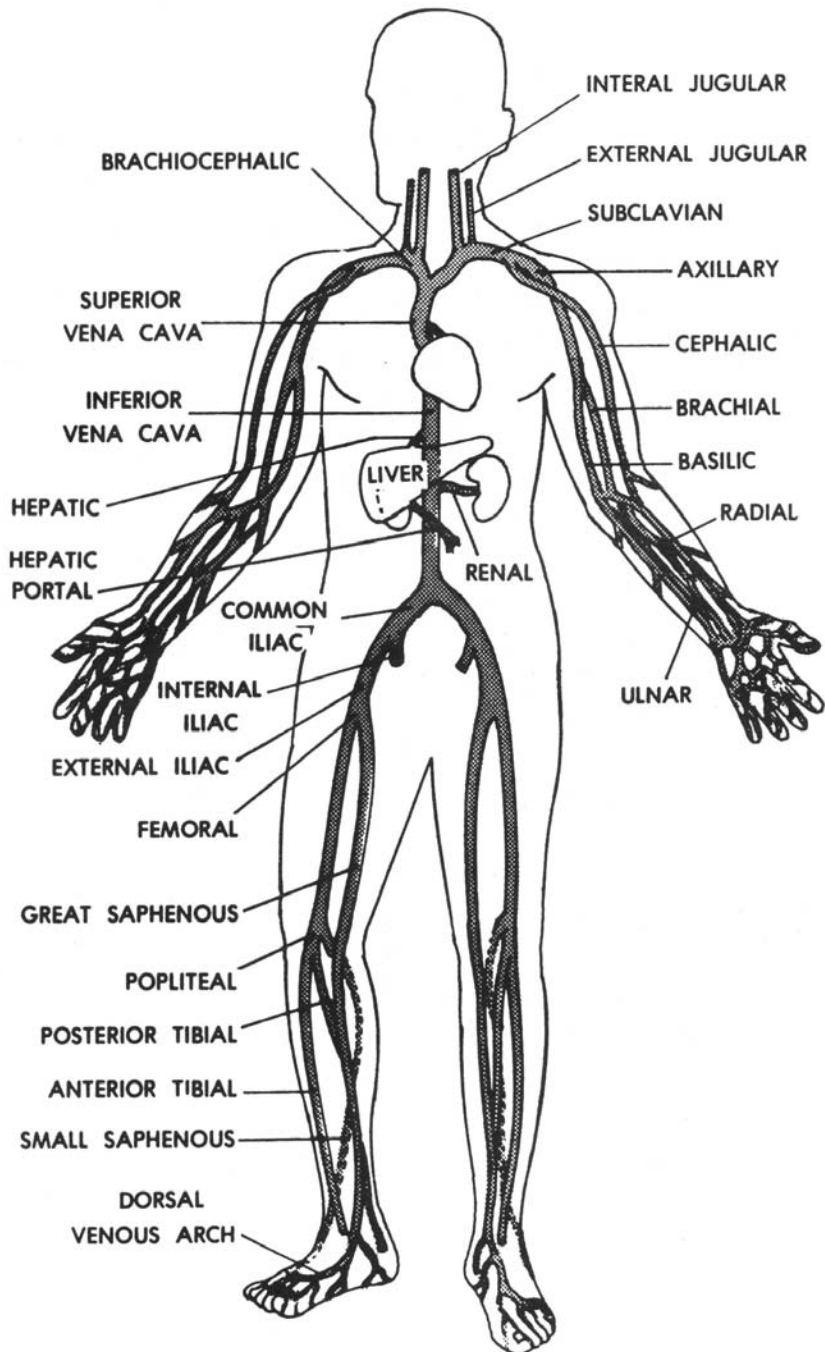


Figure 3-26. The principal veins.

## Section VI. THE ENDOCRINE SYSTEM

### 3-45. GENERAL

Within the body, in various localities are the glands of internal secretion ("ductless glands"). The substances secreted by these endocrine glands into the blood are named hormones. Hormones are secreted in minute quantities since only a trace is necessary to produce an effect. They reach different parts of the body in the bloodstream and influence the activity of one or another organ or tissue. The glands which produce hormones are: thyroid, parathyroid, adrenal, pituitary, sex glands, pancreas (islet cells), intestinal glands, pineal gland, and thymus.

### 3-46. THYROID GLAND

The thyroid gland lies in the anterior region of the neck below the lower border of the larynx. It consists of two lobes connected by a strip of tissues called the "isthmus." The hormone secreted by the thyroid is thyroxin; its main function is to regulate metabolism of the body.

### 3-47. PARATHYROID GLAND

The parathyroids are small round bodies, usually four in number, located in the posterior border of the lobes of the thyroid gland. The hormone of the parathyroid gland is parathormone. It regulates the calcium content of the blood and is related to the general metabolic state of calcium in the body. This is of particular importance since it influences the amount of calcium in certain tissues, bone formation, coagulation of blood, maintenance of normal muscular excitability, and milk production.

### 3-48. ADRENAL GLANDS

The adrenal glands ("suprarenal glands") are two small bodies shaped like a cocked hat on top of each kidney. They consist of an outer portion, the cortex, and an inner portion, the medulla. The hormone secreted by the medulla is epinephrine (adrenalin). It causes an increase in heart rate and blood pressure and a rise in the sugar content of the blood. It enables the individual to mobilize the resources of the body during emergency periods.

### 3-49. PITUITARY GLAND

a. Frequently this gland is called the hypophysis. It is a small oval mass, about the size of a pea, situated in a bony depression of the middle cranial fossa known as the sella turcica. It is composed of an anterior and a posterior lobe.



b. The pituitary gland is frequently referred to as the "leader of the endocrine orchestra" because of its widespread effect upon the other glands in the body, either modifying or controlling their secretions. The anterior lobe plays the master role and many different effects have been attributed to it.

(1) Somatotropin (growth hormone) (GH or STH). Somatotropin causes growth of all tissues of the body that are capable of growing. This hormone causes both increased size of the cell itself and increased mitosis with the development of increased numbers of cells. This hormone increases the rate of protein synthesis in all the cells of the body, decreases the rate of carbohydrate utilization, and increases the mobilization of fats and use of fats for energy.

(2) Corticotropin (adrenocorticotropin, ACTH). Corticotropin stimulates the adrenal cortex. ACTH causes the adrenal cortex to produce an increased quantity of hormones. It also controls the adrenal cortex to the extent that if the pituitary gland is removed, the adrenal cortex atrophies and becomes degenerate. If fresh pituitary gland is introduced, the adrenal cortex repairs itself.

(3) Thyrotropin (TSH).

(a) Stimulates thyroxine activity. Thyrotropin increases the rate at which the thyroid cells take up inorganic iodine from the blood. Thyrotropin further increases the rate at which thyroxine in the thyroid is released into the blood.

(b) Stimulates thyroid growth. Thyrotropin causes an increase in the size of the thyroid cells and also an increase in the number of cells.

(4) Follicle-stimulating hormone (FSH).

(a) Graafian follicle control. In the female, FSH causes the proliferation of the ovarian follicular cells during growth of the Graafian follicles. These cells are also stimulated to secrete small amounts of estrogen.

(b) Induction of spermatogenesis. In the male, FSH stimulates spermatogenesis.

(5) Luteinizing hormone (LH) (interstitialcell-stimulating hormone, ICSH). In the female, LH joins with the follicle-stimulating hormone to stimulate estrogen secretion. LH also promotes the rupture of the follicle to release the ovum so that it may be impregnated. In the male, it stimulates the production of testosterone.

(6) Luteotropic hormone (LTH, prolactin). In females, LTH promotes the growth of breast tissue and lactation. In concert with the luteinizing hormone, it stimulates and maintains the corpus luteum, which secretes progesterone and estrogens.

(7) Antidiuretic hormone (ADH), vasopressin).

(a) Blood pressure. If large amounts of ADH are injected into an animal, the arterial pressure rises appreciably.

(b) Renal tubule effect. This hormone increases the permeability of the collecting tubules to water. Without ADH (diabetes insipidus), a person will lose large amounts of water from the body fluids, but retain the electrolytes. In the presence of ADH, a person keeps most of the water in the body, but loses more electrolytes. ADH keeps the body fluid diluted and a lack of this hormone concentrates the body fluids.

(8) Oxytocin.

(a) Contraction of uterus. Oxytocin in sufficient quantity causes the uterus to contract and is, therefore, responsible to a large degree for initiating labor and birth.

(b) Milk ejection. Suckling stimulates the release of oxytocin which, in turn, starts the flow of milk.

### 3-50. GONADS

a. **Ovaries (Female).** The ovaries, located in the pelvic cavity, secrete estrogens and progesterone. Estrogens are also secreted by the adrenal cortex and, during pregnancy, in very large amounts by the placenta.

(1) The main function of estrogens is to promote cellular proliferation and growth of the sexual organs and other reproductive tissues. Estrogens cause the endometrium (lining of the uterus) to thicken, and they play an essential role in the regulation of the menstrual cycle. Estrogens produce the secondary sex characteristics of females: enlargement of the uterus and vagina, growth of pubic hair, development of mammary glands, development of the pelvic girdle, and deposition of fat in the mons pubis and labia majora.

(2) Progesterone is secreted by the corpus luteum, and during pregnancy, by the placenta. The corpus luteum is a glandular mass formed in an ovary when a follicle discharges its ovum. If the ovum is impregnated, the corpus luteum increases in size and lasts for several months. Without pregnancy, the corpus luteum actively secretes for only about 14 days. The function of progesterone is primarily to provide adequate nutrients for an embryo if it should begin to develop. During pregnancy, it maintains the placenta, prevents further ovulation, enlarges the breasts, and stimulates the development of milk-secreting cells in the mammary glands.

b. **Testes (Male).** The testes, located in the scrotum, secrete testosterone. The testes of a fetus secrete testosterone to stimulate the development of the male anatomy. After birth, the testes become dormant and remain so until puberty when testosterone is secreted once again and stimulates the development of secondary male sex characteristics, including enlargement of the male sex organs; growth of facial, pubic, and chest hair; growth of the larynx to deepen the voice; and disposition of protein to increase muscularity and general body size.

### **3-51. PANCREAS**

The islet cells of the pancreas produce the hormone insulin, which is essential for the transfer of sugar from extracellular fluids into cells.

### **3-52. INTESTINAL GLANDS**

The duodenum supplies a hormone called "secretin," which causes the intestinal juices to flow whenever food reaches the intestines. The liver and spleen are also believed to supply hormones to the blood.

### **3-53. PINEAL GLAND**

The pineal gland is a small gland posterior to the third ventricle of the brain. It exerts an influence on the rate of growth and the commencement of puberty.

### **3-54. THYMUS**

The thymus is a temporary organ located partly in the neck and thorax. It is large in infancy and shrinks as the individual matures. The thymus plays an important role in the development of the lymphatic system and production of lymphocytes in the fetus and infant. It secretes hormones that activate lymphatic tissue.

## **Section VII. THE SPECIAL SENSES**

### **3-55. GENERAL**

The specific adaptation of certain structures in the body permits reception of stimuli and their subsequent transformation into sensation. In the designated areas of the cerebral cortex, these stimuli are converted into conscious processes. The skin and underlying connective tissue contain receptors for pain, temperature, and touch. Other receptors are located in muscles, tendons, the tongue (taste buds), the nose (olfactory), the retinas of the eyes (visual), the cochleae of the ears (hearing), and the labyrinths of the ears (equilibrium). The parts of the sensory mechanism are the sense organ receptors, the pathways by which the messages are conducted into the central nervous system, and the sensory centers in the central cortex. The special senses include smell, taste, sight, and hearing.

### 3-56. THE EYE

a. The eye is specialized for the reception of light. The optic nerve conveys the impulses to the visual area of the cerebral cortex where the sensation is made apparent.

b. The eyeball is divided into an anterior chamber and a posterior chamber separated by the crystalline lens. The anterior chamber contains the aqueous humor while the posterior chamber is filled with the vitreous humor.

c. The retina is a delicate nerve membrane that receives the images and transfers these images to the optic nerve and ultimately to the cerebral cortex. It contains two kinds of light-sensitive cells: cones and rods.

(1) Cones are concentrated near the center of the retina and dispersed to a lesser degree away from the center. They are sensitive to light in the daylight range (from 0.1 to 1,000 millilamberts).

(2) Rod cells are concentrated away from the optical center. They see in terms of shades of gray and do not differentiate colors. Sensitivity of the rods extends as low as 0.0001 millilamberts.

### 3-57. THE EAR

a. The ear (figure 3-27) consists of the outer ear, the middle ear, and the inner ear. The pinna, or external part of the outer ear, is composed of cartilage covered with skin. It projects from the side of the head and collects sound vibrations that are conducted by the external auditory canal to the middle ear.

b. The middle ear is the irregular space in the temporal bone filled with air and containing the auditory ossicles: the incus (anvil), malleus (hammer), and stapes (stirrup). They conduct vibrations from the tympanic membrane to the internal ear. The middle ear is also connected with the nasopharynx by the auditory (eustachian) tube, which equalizes the air pressure in the middle ear with the exterior. Another communication exists between the middle ear and the mastoid air cells.

c. The inner ear contains the receptors for hearing and equilibrium in relationship with the petrous portion of the temporal bone. Sound waves, which traverse the external auditory canal to the tympanic membrane (ear drum), produce vibrations in the auditory bones. The vibrations are transmitted to a fluid and thence to the fibers of the hair cells of the organ of Corti, which lies at the base of the cochlear duct. These fibers, in turn, initiate impulses in the auditory nerve, which travel to the auditory center of the cerebral cortex.

d. In each inner ear, there are three semicircular canals as well as a utricle and a saccule. These are concerned with equilibrium. Changing the position of the head causes movement of fluid within the canals and an impulse is conveyed to the central nervous system by the vestibular nerve.

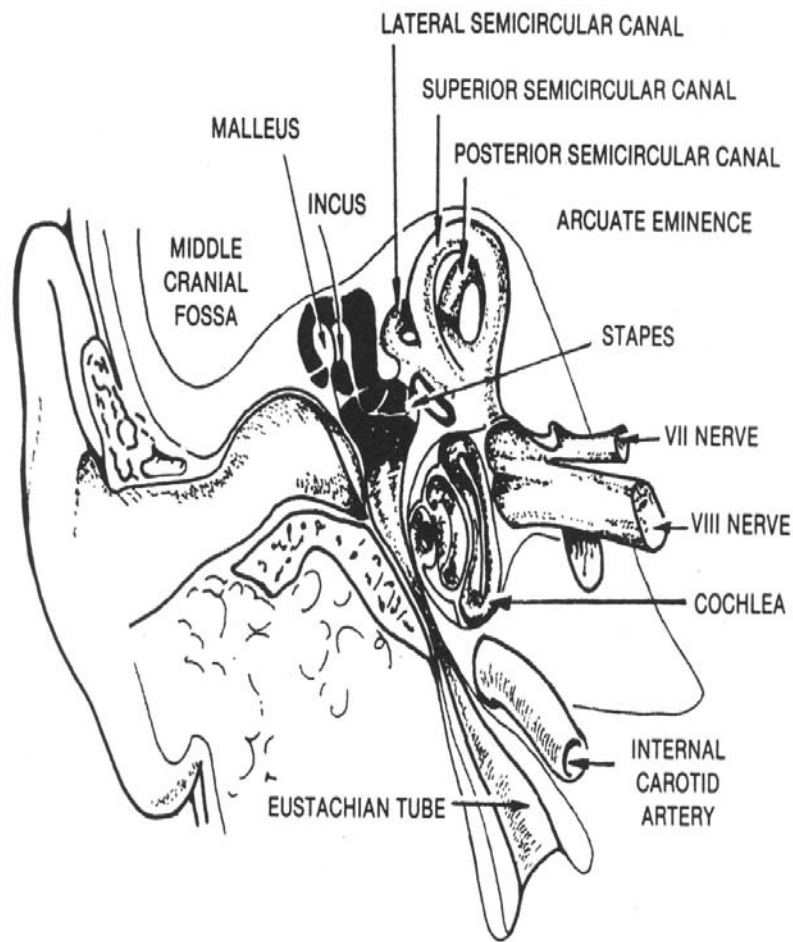


Figure 3-27. The ear. (From DeWeese, D. D. and Saunders, W. H., Textbook of Otolaryngology, 3d edition, St. Louis: The C. V. Mosby Company, 1968.)

**Continue with Exercises**

### EXERCISES, LESSON 3

**INSTRUCTIONS.** Answer the following exercises marking the lettered response that best answers the question or best completes the incomplete statement, or by writing the answer in the space provided.

After you have completed all of these exercises, turn to "Solutions to Exercises" at the end of the lesson and check your answers. For each exercise answered incorrectly, reread the material referenced with the solution.

1. The hard palate is made up of portions of two bones, the palatine bone and the:
  - a. Sphenoid.
  - b. Hyoid.
  - c. Turbinate.
  - d. Maxilla.
  
2. A pathological condition that occurs when a clot or any foreign material travels from its point of origin until it becomes lodged in a smaller vessel is a/an:
  - a. Thrombus.
  - b. Embolism.
  - c. Aneurysm.
  - d. Arteriosclerosis.
  
3. Which salivary gland is located closest to the ear?
  - a. Parotid.
  - b. Submaxillary.
  - c. Sublingual.
  - d. Mucous.

4. Which of these secretions is carried by Wharton's duct?
  - a. Bile.
  - b. Saliva.
  - c. Urine.
  - d. Insulin.
  
5. How many canine teeth are there in each jaw when the permanent teeth are intact?
  - a. Two.
  - b. Four.
  - c. Six.
  - d. Eight.
  
6. At what level does the oropharynx terminate at the lower end?
  - a. Cricoid cartilage.
  - b. Hyoid bone.
  - c. Esophagus.
  - d. Soft palate.
  
7. When any structure protrudes through the esophageal hiatus of the diaphragm, it is called a(n):
  - a. Inguinal hernia.
  - b. Hiatal hernia.
  - c. Cooper's hernia.
  - d. Ventral hernia.

8. What is the name of the upper opening of the stomach?
  - a. Cardiac orifice.
  - b. Fundus.
  - c. Pyloric orifice.
  - d. Epigastrium.
  
9. What are the three sections of the small intestine?
  - a. Duodenum, jejunum, and ileum.
  - b. Duodenum, cecum, and colon.
  - c. Ileum, jejunum, and iliac.
  - d. Ileum, cecum, and colon.
  
10. The appendix is attached to the lower end of the:
  - a. Anal canal.
  - b. Cecum.
  - c. Colon.
  - d. Duodenum.
  
11. Which part of the colon extends from side to side in the abdomen?
  - a. The ascending colon.
  - b. The descending colon.
  - c. The sigmoid colon.
  - d. The transverse colon.



12. The hepatic duct transmits secretions from which organ?
- a. Kidney.
  - b. Liver.
  - c. Stomach.
  - d. Pancreas.
13. The common bile duct carries bile destined for which section of the alimentary canal?
- a. Stomach.
  - b. Duodenum.
  - c. Ileum.
  - d. Jejunum.
14. Pancreatic secretions enter the duodenum by way of the:
- a. Cystic duct.
  - b. Common bile duct.
  - c. Hepatic duct.
  - d. Pancreatic duct.
15. At approximately which vertebral level is the lower extremity of the kidneys located?
- a. Twelfth thoracic.
  - b. First lumbar.
  - c. Third lumbar.
  - d. Fifth lumbar.

16. The prostate gland surrounds a portion of the:
- a. Adipose capsule.
  - b. Cortex.
  - c. Urethra.
  - d. Glomerulus.
17. The body of the uterus protects and supports the:
- a. Embryo.
  - b. Urethra.
  - c. Prostate.
  - d. Vagina.
18. The two tubes which carry urine from the kidneys to the urinary bladder are called the:
- a. Umbilici.
  - b. Urethra.
  - c. Ureters.
  - d. Uteri.
19. The cricoid, thyroid, and epiglottic cartilages are part of the:
- a. Larynx.
  - b. Pharynx.
  - c. Nasal sinuses.
  - d. Middle ear.

20. The muscles located between the ribs are called the:
- a. Intercostal.
  - b. Extensor.
  - c. Trapezius.
  - d. Fascia Lata.
21. Which choice below does NOT name one of the major parts of the brain?
- a. Cerebellum.
  - b. Pons.
  - c. Pia mater.
  - d. Cerebrum.
22. The four cavities located within the brain are called:
- a. Atria.
  - b. Auricles.
  - c. Plexuses.
  - d. Ventricles.
23. Inguinal lymph nodes are found in the:
- a. Neck.
  - b. Armpits.
  - c. Groin.
  - d. Elbow.

24. An organ of the body that cleanses the blood and also produces lymphocytes is the:
- a. Liver.
  - b. Heart.
  - c. Spleen.
  - d. Pancreas.
25. The \_\_\_\_\_ glands secrete a hormone called \_\_\_\_\_, which causes an increase in heart rate and blood pressure and a rise in blood sugar content.
- a. Pituitary, somatropin.
  - b. Parathyroid, parathormone.
  - c. Adrenal, epinephrine.
  - d. Thyroid, thyroxin.
26. The triangular space between the wall of the thorax and the lower margin of the diaphragm is called the:
- a. Pleural cavity.
  - b. Upper lobe.
  - c. Hilus.
  - d. Costophrenic angle.

**Check Your Answers on Next Page**

### **SOLUTIONS TO EXERCISES, LESSON 3**

1. d (para 3-2; figure 2-30)
2. b (para 3-44)
3. a (para 3-4a(1))
4. b (para 3-4a(2))
5. a (para 3-5; figure 3-3)
6. b (para 3-6b; figures 3-1 and 3-2)
7. b (para 3-7)
8. a (para 3-8a(2))
9. a (para 3-9; figure 3-1)
10. b (para 3-10a; figure 3-1)
11. d (para 3-10b(4); figure 3-1)
12. b (para 3-11a; figure 3-1)
13. b (para 3-11b(1); figures 3-1 and 3-5)
14. d (para 3-11c; figure 3-5)
15. c (para 3-14a)
16. c (para 3-17c(5))
17. a (para 3-19c(1))
18. c (para 3-16)
19. a (para 3-23)
20. a (para 3-28b)

21. c (para 3-32c(3); figure 3-16)
22. d (para 3-33d(1); figures 3-17 and 3-18)
23. c (para 3-36b; figure 3-19)
24. c (para 3-37)
25. c (para 3-47)
26. d (para 3-27c)

**End of Lesson 3**